

Case Report

Abscess Formation of the Round Ligament of the Liver: Report of a Case

Kazunori Tsukuda*, Shiro Furutani, Saki Nakahara, Akihiro Tada,
Keitaro Watanabe, Shoji Takagi, Eiji Ikeda, Ryuji Hirai, and Hisashi Tsuji

Department of Surgery, Okayama Red Cross General Hospital, Okayama 700-8607, Japan

Abscess formation of the round ligament of the liver is very rare. We report a case of a 70-year-old female with abscess of the round ligament after an endoscopic papillotomy for choledocholithiasis. On the 21st day following papillotomy, abscess formation of the round ligament was found by ultrasonographic examination. Surgical treatment was performed because conservative therapy was not effective. The purulent fluid and necrotic tissue at the round ligament were completely removed. Cultures obtained from the abscess grew *Staphylococcus epidermidis*, but the mechanism of abscess formation in this case remains unclear.

Key words: round ligament of the liver, abscess

Abscess formation or necrosis of the round ligament of the liver is very rare, and only 6 cases have been reported to date [1-6]. The diagnosis is based on localized inflammation of the ligament without apparent etiology. We present herein the case of a 70-year-old female with an abscess of the round ligament of the liver after treatment for choledocholithiasis.

Case Report

A 70-year-old female patient consulted her physician with severe abdominal pain and was diagnosed with acute pancreatitis. The initial blood tests showed her white blood cell count was 7,700/ μ l and serum amylase was 5,540 IU/l. The patient was referred to our institution a week later, because high fever persisted in spite of the treatments with ulina-

statin and cefmetazole sodium.

The patient presented right upper abdominal pain. Her body temperature was 36.8°C, blood pressure was 106/70 mmHg, and pulse was 72/min at the first visit. Her white blood cell count was 9,100/ μ l, CRP was 9.6 mg/dl, amylase was 205 IU/l and total bilirubin was 0.6 mg/dl. Computed tomography and ultrasonographic examination revealed swelling of the gallbladder and gallstones in the common bile duct. Under the diagnoses of acute choledochitis and pancreatitis due to choledocholithiasis, endoscopic retrograde cholangiography was performed. The patient consequently underwent endoscopic papillotomy and the stones were removed. After the treatment, the patient's symptom was relieved and blood tests were normal.

On the 21st days after the papillotomy, a periodical ultrasound inspection showed intraabdominal abscess formation adjacent to the gallbladder (Fig. 1). Computed tomography confirmed an abscess at the round ligament of the liver that extended to the hepatic fissure (Fig. 2). The patient had no evidence

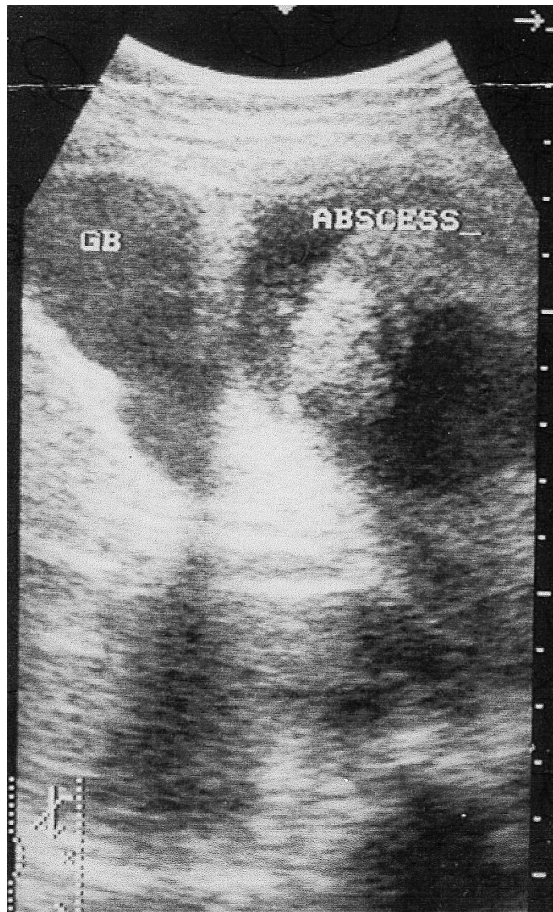

Fig. 1 Ultrasonography showed wall thickening of the gallbladder and abscess formation adjacent to the gallbladder.

of infection of the umbilicus. At this point the white blood cell count was $3,300/\mu\text{l}$ and CRP was 1.9mg/dl . Though the patient did not show severe symptoms, surgical treatment was performed because the abscess did not dwindle with conservative treatment.

During surgery, no acute process was found in the gallbladder. An abscess with purulent fluid and necrotic tissues involved the round ligament and left lobe of the liver. The necrotic tissue was completely removed and cholecystectomy was done. Intraoperative cholangiography was performed, but a connection of the intrahepatic duct with the abscess cavity was not proved. The patient had an uneventful postoperative course and was discharged on the 15th postoperative day.

Pathological examination showed that the necrotic tissues consisted of fatty tissue and blood but not liver

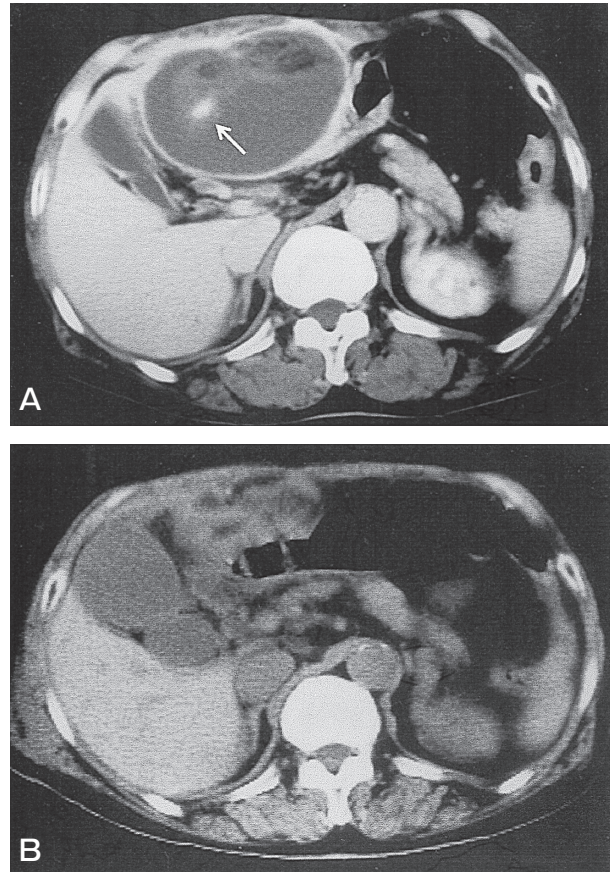


Fig. 2 **A**, Computed tomography shows a large abscess, $9 \times 6\text{cm}$, at the round ligament of the liver. The existence of the umbilical vein (arrow) which runs inside the abscess and is connected to the left branch of the portal vein confirmed that the abscess was formed inside the round ligament; **B**, An identical CT view during the patient's first visit showed no abscess formation.

tissue, which indicated that the abscess did not originate from a liver abscess. Cultures obtained from the abscess grew *Staphylococcus epidermidis*, common bacteria that cause omphalitis. The mechanism of abscess formation in this case remains unclear, because the patient showed no abnormal findings of the umbilicus.

Discussion

The round ligament represents the remnant of the left fetal umbilical vein and is a degenerative string of tissue that extends from the umbilicus to the transverse fissure of the liver. Within a week of birth, the infant's umbilical vein is completely obliterated and is replaced by the round ligament of the liver. In an

adult, the round ligament is known to reopen to allow the passage of blood under extreme pressure, such as that caused by cirrhosis and portal hypertension [7].

Omphalitis is exclusively a disease of neonates, usually due to staphylococcal or streptococcal infection and few cases of adult omphalitis have been reported [8]. Though staphylococcus was a source of contagion in the present case, no involvement of the umbilicus was shown through the entire hospitalization period. The previous papillotomy treatment and involvement of the lateral lobe of the liver made correlation with infection of the biliary duct seem likely, but radiological and bacteriological findings did not support this conclusion. Thus, the mechanism of abscess formation in this case remains unclear.

A review of the literature has shown only 6 cases similar to the present one [1-6]. The patient age ranges from 18 to 84 years in reported cases. Only 2 cases mentioned contagions; one was infected with *E. coli*, *Enterococcus* and *Klebsiella pneumoniae* and the other was negative for bacteria [2, 3]. The infection in the former case indicated that the infection may have originated from the gastrointestinal tract. Most cases showed acute abdominal symptoms and underwent surgical treatment. Unlike our case, the other cases arose without previous medical treatment or primary illness. Surgical treatment should be performed without delay after a diagnosis of this type of

infection, because there is a report that abscess of the round ligament extended to generalized peritonitis and necessitated emergency surgery [4].

Infection of the round ligament is extremely rare but should be suspected in patients with abdominal complaints and imaging study may be useful to demonstrate abscess formation of the round ligament.

References

1. Charuzi I and Freund H: Gangrene of the hepatic round ligament causing diffuse peritonitis: a case report. *Am Surg* (1976) 42: 925-926.
2. Watson SD, McComas B, Rannick GA and Stanton PA Jr: Gangrenous ligamentum teres hepatis causing acute abdominal symptoms. *South Med J* (1988) 81: 267-269.
3. Pans A, Burnel M and Gillard R: Gangrene of the round liver ligament: an unrecognized pathology. *Chirurgie* (1999) 124: 551-554.
4. Losanoff JE and Kjossev KT: Isolated gangrene of the round and falciform liver ligaments: a rare cause of peritonitis: case report and review of the world literature. *Am Surg* (2002) 68: 751-755.
5. Martin TG: Videolaparoscopic treatment for isolated necrosis and abscess of the round ligament of the liver. *Surg Endosc* (2004) 18: 1395.
6. Tison C, Regenet N, Frampas E, Masliah C and Le Borgne J: Gangrene isolee du ligament rond du foie. *Gastroenterol Clin Biol* (2005) 29: 204-205.
7. Khati NJ, Enquist EG and Javitt MC: Imaging of the umbilicus and periumbilical region. *Radiographics* (1998) 18: 413-431.
8. Cushing AH: Omphalitis: a review. *Pediatr Infect Dis* (1985) 4: 282-285.

