

Original Article

## Initial Report of Hybrid Radical Prostatectomy for Prostate Cancer: Reduced Bleeding, Clear Vision, and Secure Surgical Margins

Takashi Saika\*, Yasuyuki Kobayashi, Toyohiko Watanabe, Daisuke Manabe, Shin Ebara, Shinya Uehara, Yasutomo Nasu, and Hiromi Kumon

Department of Urology,  
Okayama University Graduate School of Medicine, Dentistry and Pharmaceutical Sciences,  
Okayama 700-8558, Japan

To evaluate morbidity in Hybrid Radical Prostatectomy (HRP, hybridized laparoscopic and open retropubic radical prostatectomy). The operative and pathological outcomes obtained in 25 consecutive patients who underwent HRP were reviewed. The median operating time was 220 min, median blood loss was 550 ml, and no patient required an allogenic blood transfusion. No severe postoperative complications were observed. The surgical margin was positive in 12% of all patients, and in 1 patient with pT2 or less (4.5%). These results indicate that HRP is safe and may be able to combine the benefits of both laparoscopic and open procedures.

**Key words:** prostate cancer, radical prostatectomy, hybrid surgery, morbidity, positive surgical margin

Open radical retropubic prostatectomy (RRP) is widely considered to be the gold standard treatment for localized prostate cancer. Refined surgical techniques and appropriate patient selection have improved the outcomes of this procedure [1-4]. However, interest has been growing for laparoscopic radical prostatectomy since the first feasibility report by Schuessler *et al.* [5] and the standardization of the LRP technique by Guillonneau *et al.* [6]. Since then, reports of the advantages and pitfalls of this minimally invasive approach have increasingly appeared in the literature [7, 8]. Although LRP is one attractive alternative to open prostatectomy, the clinical value of LRP remains controversial, with general interest

focusing on its comparison with RRP [9-12]. Ultimately, however, the first priority for any surgical procedure for radical prostatectomy must be safety along with oncological control and universal validity rather than any bias toward one surgical modality.

Based on this fundamental point, we hybridized LRP and RRP by combining the advantages of both. LRP advantages include reduced blood loss and reduced apical positive margin rates [13] by laparoscopic images using magnification and illumination. The advantage of RRP is that it is an established and easy technique for seminal vesicle, vesico-prostate junction, and vesico-urethral anastomosis using eye/hand coordination with usual tactile feedback and three-dimensional vision. We have named this surgical procedure "Hybrid Radical Prostatectomy," or HRP.

We analyzed a cohort of 25 patients treated with HRP at our university. We then compared these

results to published reports from the literature regarding the outcomes of LRP and RRP, including mini-laparotomy radical retropubic prostatectomy (mini-lap RRP).

## Patients and Methods

A retrospective review was performed on 25 consecutive patients undergoing HRP with pelvic lymphadenectomy at our institute from May 2006 through April 2007. Informed consent was obtained from all patients before the surgery. Operative characteristics noted were operating time, estimated blood loss, transfusion rate, nerve-sparing procedure, length of catheterization, and length of hospital stay. Oncological features, including postoperative Gleason grade, clinical and pathological stage, margin positivity, and rate of biochemical recurrence, were reviewed. Postoperative continence at 6 months postoperatively was also reviewed. Patients were considered continent if they had no leakage or required less than one pad per day.

In this series, a surgical team consisted of 4 surgeons (T. S., Y. K., D. M., and S. U.) with sufficient skill for both laparoscopic radical nephrectomy and for RRP.

### *Operative technique of hybrid radical prostatectomy.*

#### 1. First phase: endoscopic extraperitoneal approach.

The first phase of HRP is carried out according to a modification of the technique of endoscopic extraperitoneal radical prostatectomy, which has been previously described and illustrated in detail [14].

The operation started with the creation of a preperitoneal space. A 1.5-cm midline approximately 1 cm below the umbilicus incision was made and preparation extended down to the rectus abdominis aponeurosis. A balloon trocar was introduced along the posterior rectus sheath and was slowly insufflated; the preperitoneal space was then dissected under endoscopic vision. The balloon trocar was exchanged for a 12-mm blunt tip trocar, and high-flow carbon dioxide was insufflated to 12mmHg pressure. Under endoscopic guidance a 12-mm trocar was placed approximately 3 to 4cm right of the midline and approximately 2 cm below the first trocar. Two more 5-mm trocars were introduced into the preperitoneal space (Fig. 1).

The first step of this phase was dissection of the space of Retzius from the anterior surface of the bladder neck down to the anterior surface of the prostate and endopelvic fascia.

The endopelvic fascia was incised, and prostate apical dissection was then started to identify the urethra and posterior limits of the venous complex. For adequate hemostasis of the deep dorsal venous complex (DVC) and reduction of the rate of positive surgical margin in the prostate apex, we attempted to define the prostatic apex as precisely as Ahlering *et al.* described in their robotic prostatectomy [15]. Briefly, the one-step stapling and division of the DVC was performed by a 45-mm Endo-GIA stapler (Ethicon, Somerville, NJ, USA) (Fig. 2A). Once the stapler was fired, the urethra and prostatic apex were clearly exposed (Fig. 2B). The urethral wall was incised with cold scissors. After the prostate apex was freed, the procedure shifted to the second phase. Magnification by endoscopic equipment and reduced bleeding by pneumoretroperitoneum pressure allowed good visibility throughout the first phase.

#### 2. Second phase: minimally open extraperitoneal approach.

At the pubic bone lesion, a 5-6cm incision was added for the open approach. The prostate lateral pedicles, the ampulla of the vas deferens, seminal

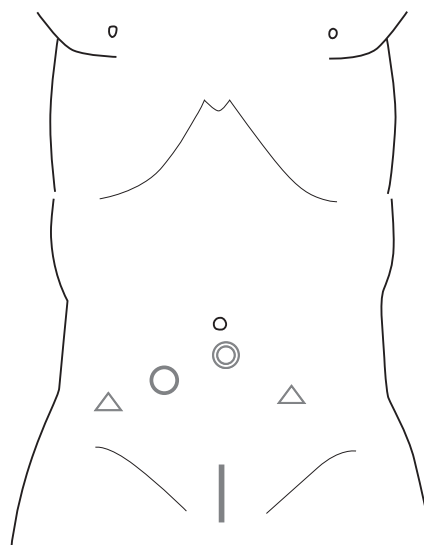


Fig. 1 Schema of trocar introduction and incision. ◎, primary port; ○, 10-mm trocar; △, 5-mm trocar.

vesicle, and bladder neck were dissected in a retrograde manner as described for the conventional retropubic radical prostatectomy procedure [1]. A new bladder neck was plastied with mucosal everting suture for adaptation to the urethra. A urethrovesico anastomosis was made with four 3-0 PDS sutures at 2-, 5-, 7-, and 10-o'clock positions.

## Results

The data are summarized in Table 1.

The median operating time was 220 min. (range, 145-270), median blood loss was 550 ml (range, 70-1,100), and no patient required an allogenic blood transfusion. No trend for a learning curve was observed in this series (Fig. 3). No influence of body mass index (BMI) on peri-surgical results was observed. There was no intraoperative trouble associated with this procedure except for one ileal injury by a trocar introduction which was closed with no subsequent problems. No severe postoperative complications were observed in any patient. The surgical margin was positive in 3 of all 25 patients and in 1 of 22 patients with pT2 or less (4.5%). Two patients with capsule penetration showed positive at the posterior-lateral lesion in one and at the posterior-apex lesion in the other. Another patient with pT2 showed positive at a lateral in nerve sparing lesion. One patient was recognized as experiencing biochemical recurrence at 9 months post surgery. The urethral catheter was removed on median day 6. Patients with a post-surgical recovery duration of 6 months or more regained continence.

## Discussion

While the advantages in LRP, including reduced blood loss, a wide working space by pneumoretroperitoneum pressure, and reduced apical positive margin rates and more anatomic approaches, cannot be neglected, but the procedure involves a steep learning curve. In particular, the difficulties in seminal vesicle and bladder neck dissection and in vesicourethral anastomosis may result in a greater postero-lateral positive margin rate and longer surgical time [14]. On the other hand, several groups have introduced improved visibility in their open surgery with endoscopes in minilaparotomy to facilitate urologic surgery

**Table 1** Summary of results

Variable	Value $\pm$ SD (Median)
Patients (n)	25
Average follow-up (mo)	7.4 $\pm$ 4.0 ( 4.1)
Age (yr)	
Mean	66.2 $\pm$ 5.5 (67.0)
BMI (kg/m <sup>2</sup> )	
Mean	24.2 $\pm$ 3.6 (23.5)
PSA (ng/mL)	
Mean	13.05 $\pm$ 8.0 (10.1)
Clinical stage	
T1b	3
T1c	10
T2a	1
T2b	7
T2c	4
Lymphadenectomy*	
Bilateral	12
Unilateral	7
None	6
Nerve preservation (%)	
Bilateral	12
Unilateral	7
None	6
Operative time (min)	
Mean	224 $\pm$ 41.0 (220)
Range	145-285
Estimated blood loss (ml)	
Mean	594.6 $\pm$ 296.9
Range	70-1,100
Transfused (%)	0
Sural nerve grafts (n)	1
Length of Foley catheterization	
Mean	7.3 $\pm$ 2.2 ( 6.0)
Range	5-13
Positive surgical margins (%)	
pT2 or less	1/22 ( 4.5)
pT3	2/ 3 (66.7)
Overall	3/25 (12.0)
Post operative Gleason score	
6	7
7	16
8	2

BMI, body mass index; PSA, prostate-specific antigen.

\*Lymphadenectomy was performed unilaterally in patients with unilateral positive results in biopsy. Lymphadenectomy was omitted in patients with a Gleason Score of 6 and low PSA (less than 10 ng/ml).

through a single minimal incision without pneumoperitoneum and trocars [16, 17]. However, although they have reported that the magnification provided by the endoscope allows easy identification of the tissue

planes and more precise dissection, they diminished this advantage with their limitations of “gas less” and “port less.” In minilaparotomy, a surgical field that is narrower than one under the pneumoretroperitoneum

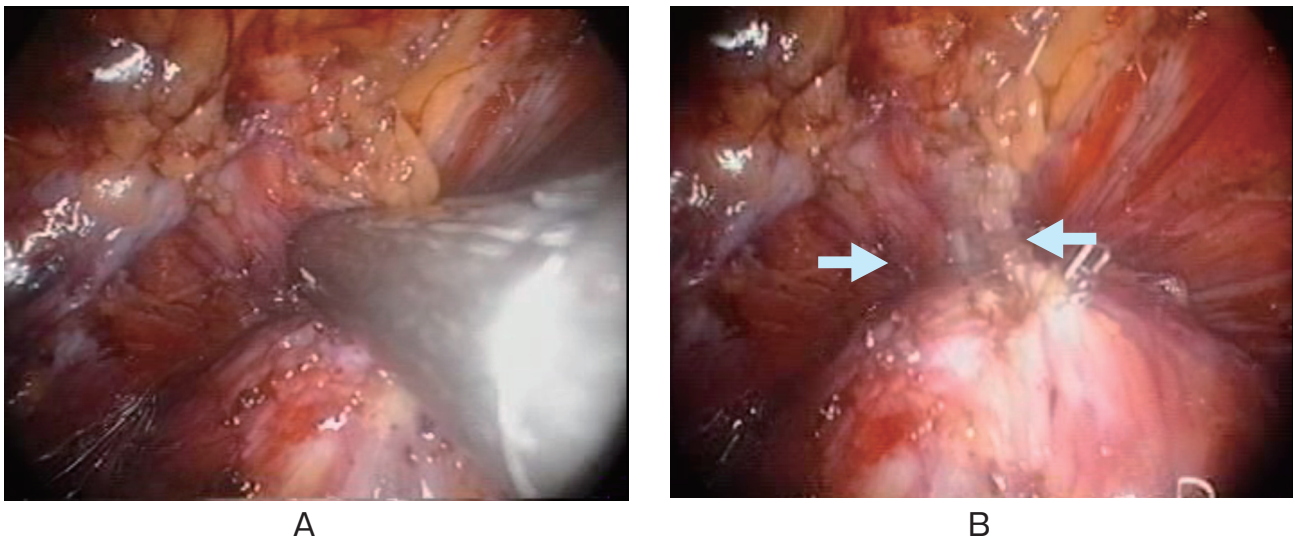


Fig. 2 A, 45-mm Endo-GIA stapler allows for one-step stapling and division of the deep dorsal vein complex; B, The anterior urethra wall (arrows) is exposed after firing of the Endo-GIA stapler.

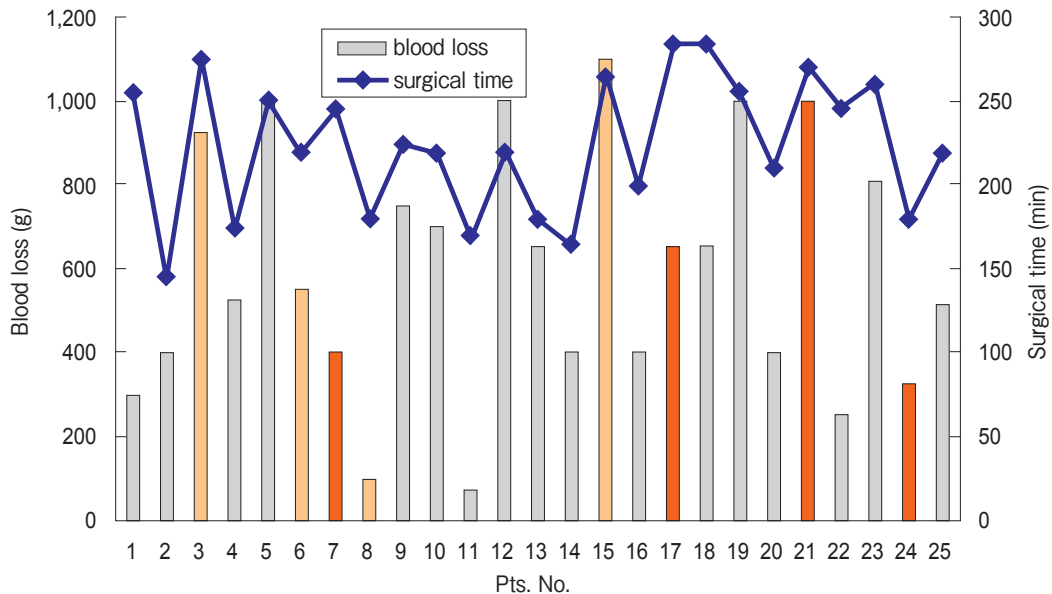


Fig. 3 Longitudinal results of Hybrid Radical Prostatectomy with regard to blood loss and operative time in relation to body mass index (BMI).

- BMI less than 25 kg/m<sup>2</sup>
- BMI 25 kg/m<sup>2</sup> or more but 30 kg/m<sup>2</sup> or less
- BMI greater than 30 kg/m<sup>2</sup>

**Table 2** Compared with laparoscopic radical prostatectomy (LRP) and open retropubic radical prostatectomy (RRP)

	Hybrid	LRP *	RRP *
No. of Patients	25	3,449	1,757
Operative time (Median) (min)	220	288	214
Estimated blood loss (Median) (g)	520	800	1,400
Duration of catheterization (Median)(Days)	7	7	15
Surgical positive margin rate (all cases) (%)	12	23	29
(pT2=>) (%)	4.5	10	18

\*based on 30 comparative studies; J Urol. Vol 175, 2011–2017, 2006. [20].

and the limitation of surgical equipment may be a disadvantage.

We have conducted this hybrid surgery to combine the advantages of both RRP and LRP procedures while potentially eliminating the disadvantages. Our preliminary series shows that operative time and blood loss of HRP are comparable to those published by other groups performing laparoscopy, without having a long learning curve. Therefore, without needing extensive practice or long experience, HRP may have the potential to overcome one disadvantage of laparoscopic surgery: longer operative time. Moreover, in terms of cancer control and its eradication, the positive margin rates of only 12%, and especially the 4.5% in pT2 in our HRP series, compare favorably with those of other large RRP [18, 19] and LRP series [9–11]. The HRP procedure, therefore, may also be advantageous with regard to both positive margin rates and peri-surgical results (Table 2).

In the future, technological advances such as surgical robots may shorten the learning curve and allow more urologists to perform endoscopic surgery. Similar oncological results with regard to the surgical margin (15% overall and 9.7% in pT2) have been obtained by employment of a surgical robot (da Vinci, Intuitive Surgical, Inc., Sunnyvale, CA, USA), with 3-dimensional vision facilitating the performance of LRP by a surgeon skilled in open surgery but with limited laparoscopic experience. The cost of the equipment, however, is a major drawback. With regard to the oncological benefits of HRP, results regarding the long-term oncological outcomes for HRP, *e.g.* PSA progression and disease specific survival, are premature and a larger series and longer term should be discussed.

## References

- Walsh PC, Lepor H and Eggleston JC: Radical prostatectomy with preservation of sexual function: anatomical and pathological considerations. *Prostate* (1983) 4: 473–485.
- Walsh PC: Radical prostatectomy for localized prostate cancer provides durable cancer control with excellent quality of life: a structured debate. *J Urol* (2000) 163: 1802–1807.
- Kundu SD, Roehl KA, Eggener SE, Antenor JAV, Han M and Catalona WJ: Potency, continence and complications in 3477 consecutive radical retropubic prostatectomies. *J Urol* (2004) 172: 2227–2231.
- Davis JW, Kuban DA, Lynch DF and Schellhammer PF: Quality of life after treatment for localized prostate cancer: differences based on treatment modality. *J Urol* (2001) 166: 947–952.
- Schuessler WW, Schulam PG, Clayman RV and Kavoussi LR: Laparoscopic radical prostatectomy: initial short-term experience. *Urology* (1997) 50: 854–857.
- Guillonneau B, Cathelineau X, Barret E, Rozet F and Vallancien G: Laparoscopic radical prostatectomy: technical and early oncological assessment of 40 operations. *Eur Urol* (1999) 36: 14–20.
- Omar AM and Townell N: Laparoscopic radical prostatectomy: a review of the literature and comparison with open techniques. *Prostate Cancer Prostatic Dis* (2004) 7: 295–301.
- Hoznek A, Menard Y, Salomon L and Abbou CC: Current opinion 2005 Update on laparoscopic and robotic radical prostatectomy. *Curr Opin Urol* (2005) 15: 173–180.
- Herrmann TR, Rabenalt R, Stolzenburg JU, Liatsikos EN, Imkamp F, Tezval H Gross AJ, Jonas U and Burchardt M: Oncological and functional results of open, robot-assisted and laparoscopic radical prostatectomy: does surgical approach and surgical experience matter? *World J Urol* (2007) 25: 149–160.
- Ghavami R, Knoll A, Boczek J and Melman A: Comparison of operative and functional outcomes of laparoscopic radical prostatectomy and radical retropubic prostatectomy: single surgeon experience. *Urology* (2006) 67: 1241–1246.
- Guazzoni G, Cestari A, Naspro R, Riva M, Centemero A, Zanoni M, Rigatti L and Rigatti P: Intra- and peri-operative outcomes comparing radical retropubic and laparoscopic radical prostatectomy: results from a prospective, randomised, single-surgeon study. *Eur Urol* (2006) 50: 98–104.
- Slabaugh TK Jr and Marshall FF: A comparison of minimally invasive open and laparoscopic radical retropubic prostatectomy. *J Urol* (2004) 172: 2545–2548.
- Fromont G, Guillonneau B, Validire P and Vallancien G:

- Laparoscopic radical prostatectomy preliminary pathological evaluation. *Urology* (2002) 60: 661–665.
14. Salomon L, Levrel O, de la Taille A, Anastasiadis AG, Saint F, Zaki S, Vordos D, Cicco A, Olsson LE, Hoznek A, Chopin D and Abbou CC: Radical prostatectomy by the retropubic, perineal and laparoscopic approach: 12 years of experience in one center. *Eur Urol* (2002) 42: 104–111.
  15. Ahlering TE, Eichel L, Edwards RA, Lee DI and Skarecky DW: Robotic radical prostatectomy: a technique to reduce pT2 positive margins. *Urology* (2004) 64: 1224–1228.
  16. Yamada Y, Nakamura K, Aoki S, Taki T, Kokubo H, Matsubara H, Tobiume M, Zennami K, Katsuda and Honda N: Endoscope-assisted minilaparotomic radical retropubic prostatectomy. *Int J Urol* (2006) 13: 111–115.
  17. Kiyokawa H and Kato H: Radical retropubic prostatectomy through a minimal incision with portless endoscopy: our initial experience. *Int J Urol* (2006) 13: 7–9.
  18. Ward JF, Zincke H, Bergstralh EJ, Slezak JM, Myers RP and Blute ML: The impact of surgical approach (nerve bundle preservation versus wide local excision) on surgical margins and biochemical recurrence following radical prostatectomy. *J Urol* (2004) 172: 1328–1332.
  19. Swindle P, Eastham JA, Ohori M, Kattan MW, Wheeler T, Maru N, Slawin K and Scardino PT: Do margins matter? The prognostic significance of positive surgical margins in radical prostatectomy specimens. *J Urol* (2005) 174: 903–907.
  20. Toohar R, Swindle P, Woo H, Miller J and Maddern G: Laparoscopic radical prostatectomy for localized prostate cancer: a systematic review of comparative studies. *J Urol* (2006) 175: 2011–2017.
  21. Smith JA Jr, Chan RC, Chang SS, Herrell SD, Clark PE, Baumgartner R and Cookson MS: A comparison of the incidence and location of positive surgical margins in robotic assisted laparoscopic radical prostatectomy and open retropubic radical prostatectomy. *J Urol* (2007) 178: 2385–2389.