

The Minimally Invasive Plate Osteosynthesis (MIPO) Technique with a Locking Compression Plate for Femoral Lengthening

Hirosuke Endo^{a*}, Koji Asaumi^b, Shigeru Mitani^a, Tomoyuki Noda^a,
Hirosaki Minagawa^a, Tomonori Tetsunaga^a, and Toshifumi Ozaki^a

^aDepartment of Orthopaedic Surgery, Okayama University Hospital, Okayama 700-8558, Japan, and

^bDepartment of Orthopaedic Surgery, Okayama Red Cross Hospital, Okayama 700-8607, Japan

A minimally invasive plate osteosynthesis technique using a locking compression plate (LCP) has been used widely in trauma cases. Its advantages are that the MIPO technique does not interfere with the fracture site and thus provides improved biological healing, and that the LCP has excellent angular stability. Its use in bone lengthening, however, has not been established. In such cases, it is desirable to shorten the external skeletal fixation period as much as possible. Here, the MIPO technique using an LCP was applied to femoral distraction osteogenesis in an attempt to shorten the external skeletal fixation period. For femoral lengthening, the MIPO technique was performed in 2 stages. Orthofix external fixators (Orthofix, England) were used to insert screws from the anterolateral side rather than from the lateral side of the femur for bone lengthening. When sufficient callus formation was detected postoperatively at the site of bone lengthening, and the absence of infection was ensured, limb draping was performed, including a whole external fixator, and then the MIPO technique was applied with an LCP.

In 3 cases (5 limbs), the average duration of external skeletal fixation was 134 days, the average external-fixation index was 24 days/cm, and the average consolidation index was 22 days/cm. The MIPO technique using an LCP made it possible to shorten the external skeletal fixation-wearing period in femoral lengthening.

Key words: femoral lengthening, minimally invasive plate osteosynthesis, locking compression plate, external skeletal fixation, external-fixation index

Bone lengthening in the lower limbs is a widely prevalent therapy for leg-length differences and short-limbed dwarfism. Bone lengthening is an excellent method, but due to the use of external skeletal fixation, there are cosmetic problems and a significant burden on patients because of activities of daily living (ADL) limitations. However, if external fix-

ators are removed without waiting for sufficient callus formation, there is a risk of bone fracture. It is necessary to wear external skeletal fixations 2 to 3 times longer than the normal lengthening period (distraction phase) while waiting for bone maturation (consolidation phase). Bone lengthening during the distraction phase is ordinarily less than 1 mm per day. Once the biologically optimal length is achieved, it is preferable that the consolidation phase be as short as possible. Various attempts have been made toward achieving this objective [1-5]. This study focuses on

the application of the MIPO technique [6, 7], which is performed in trauma cases for biological fixation to femoral lengthening. There has been no prior report of using the MIPO technique after limb lengthening. It is possible that an LCP in the consolidation phase can be equipped with a fixator inside the skin, rather than the external fixator that is necessary for the consolidation phase. This successfully shortened the duration of external skeletal fixation. This report describes our original surgical techniques and results of femoral lengthening.

Materials and Methods

Patients.

1. Study group (consolidation with MIPO technique)

The cases included 5 limbs in 3 patients, comprised of 4 limbs in 2 males and 1 limb in 1 female (Table 1A). The average age of the patients at the time of surgery was 17 years (16 to 18 years). The underlying disease in the 4 limbs in male patients involved short-limbed dwarfism due to achondroplasia, and the 1 limb in the female patient involved a leg-length difference due to Klippel-Trenaunay-Weber syndrome. The average observation period was 1 year and 9 months (1 to 3 years).

2. Control group (consolidation with external fixator)

The cases included 8 limbs in 6 patients (Table 1B), comprised of 2 limbs in 3 males and 5 limbs in 3 females. The average age of the patients at the time of surgery was 15 years (6 to 22 years). The underlying disease in 5 limbs in 3 patients involved short-

Table 1A Patient data: lengthening with MIPO technique and ultrasound

Case no.	Age	Diagnosis	Distraction Length (cm)	Distraction period (days)(days/cm)	Waiting period (days)	Duration of external fixation (days)(days/cm)	Deformity correction
1	16*	Achondroplasia	9.0	100 (11)	31	131 (14)	—
2	16*	Achondroplasia	9.0	100 (11)	31	131 (14)	+
3	16	Klippel-Trenaunay-Weber-syndrome	5.0	50 (10)	77	127 (25)	—
4	18*	Achondroplasia	5.0	60 (12)	80	140 (28)	—
5	18*	Achondroplasia	5.0	60 (12)	80	140 (28)	+

*Case 1 and 2, 4 and 5 represent the same patients.

Table 1B Patient data: lengthening with external fixator and ultrasound

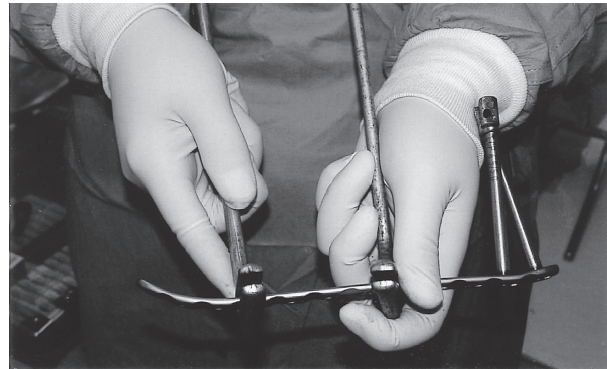Case no.	Age	Diagnosis	Distraction Length (cm)	Distraction period (days)(days/cm)	Duration of external fixation (days)(days/cm)	Deformity correction
1	13*	Metaphyseal dysplasia	4.0	30 (8)	175 (44)	—
2	13*	Metaphyseal dysplasia	4.0	40 (10)	195 (49)	—
3	22	Posttrauma discrepancy	5.3	79 (10)	226 (25)	—
4	19*	Achondroplasia	9.0	90 (10)	372 (45)	—
5	19*	Achondroplasia	9.0	90 (10)	372 (46)	—
6	14	Posttrauma discrepancy	3.0	30 (10)	288 (96)	—
7	10	Spondyloepiphyseal dysplasia	2.0	25 (12)	210 (105)	+
8	6	Postinfection discrepancy	3.0	33 (11)	240 (80)	+

*Case 1 and 2, 4 and 5 represent the same patients.

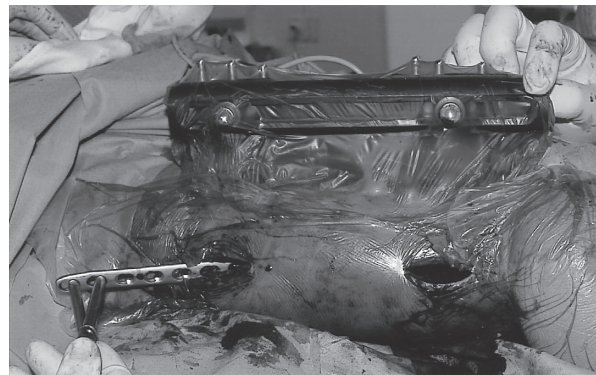
limbed dwarfism due to short stature (metaphyseal dysplasia, achondroplasia, or spondyloepiphyseal dysplasia). The remaining 3 limbs in 3 patients involved leg-length discrepancy due to trauma or infection. The femoral lengthening and consolidation was performed by an external fixator, and ultrasound treatment (SAFHS® TEIJIN, Tokyo, Japan) was concomitantly administered in all cases. The average observation period was 3 year and 9 months (1 to 6 years).

All patients and their families were informed that the data from their cases would be submitted for publication and gave their consent.


Operative procedure. For distraction osteogenesis, unilateral long slide lengtheners (Orthofix LRS; Orthofix, England) were used in all of the cases. In order to perform the MIPO technique, screws were inserted anterolaterally in advance of attaching the external skeletal fixation for avoiding the lateral part to insert a plate. An osteotomy was performed laterally according to standard methods, and distraction osteogenesis was performed at 1 week after the surgery at a pace of 1 mm per day. To accelerate callus formation, ultrasound treatment (SAFHS® TEIJIN, Tokyo, Japan) was concomitantly administered in all cases. A waiting period of at least 1 month was required before the inner callus was sufficiently formed after the target lengthening distance was achieved. Clinical examinations and blood tests were performed ensure that there were no infections of the femur. Locking compression plates (Mathys Medical, Bettlach, Switzerland) were used in all cases. The locking plate was carefully bent to depending on the deformity (Fig. 1A). With the MIPO technique, the locking plate was inserted through a proximal skin incision and placed onto the periosteum (Fig. 1B). Next, the external fixators were removed, after screws were fixed into at least 2 holes in both the proximal and distal parts (Fig. 1C). Screws penetrated to the bi-cortex, and ultimately, 3 screws at distal and proximal parts were used to fix the plate. The prognosis of one case in this series is shown in Fig. 2. For postoperative treatment, activity was allowed depending on the pain the next day. Weight bearing was not limited and the patients were allowed to walk freely without any brace, cast or crutches, depending on their general condition.



A



B



C

Fig. 1 MIPO (minimally invasive plate osteosynthesis) technique for femoral bone lengthening.

A, plate bending for MIPO; B, plate insertion under external fixation; C, fixed distal and proximal screws of the LCP (locking compression plate).

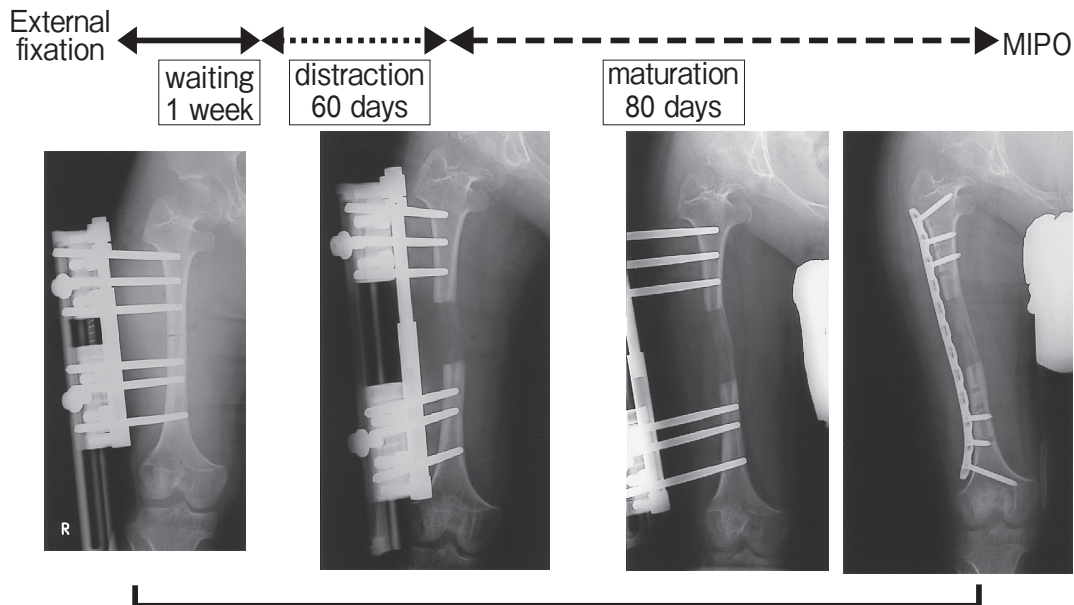


Fig. 2 The prognosis of the femoral lengthening in Case No. 3. The external skeletal fixation lasted 147 days. The distraction length was 5 cm. Hence, the external fixation index was 28 day/cm.

Results

The average lengthening distance using the new technique was 6.6 cm (5 to 9 cm), the average lengthening period was 76 days (2.5 months), and the average distraction index was 11.5 days (0.4 months/cm). The mean duration of external fixation was 133.8 days (127 to 140 days, 4.5 months), the average external-fixation index was 24.6 days/cm (14.1 to 28 days/cm, 0.8 months). Deformity correction was performed for 2 limbs. There were no cases of post-operative infection. No cases showed a change in alignment radiologically after the conversion, so good callus formation was achieved (Fig. 3). The plates were removed at 1 year and 7 months after the surgery in Case 1 and 2 (Table 1A). They could be removed without widening the initial skin incision at the time of surgery. In this case, a CT scan after the MIPO demonstrated that the distraction-osteogenesis site had become a marrow cavity over time and a new cortical bone had formed (Fig. 4). For 2 limbs in 1 of the 2 cases of achondroplasia, the patient gave up limb lengthening at 5 cm due to the development of thigh pain and numbness because of lumbar canal stenosis. In this case, there was a marked joint contracture with 0 to 20 degrees of range of motion in both

knees. A blunt release of the femoropatellar joint and the rectus femoris muscle was performed simultaneously from the distal part of the incision using the MIPO technique. The patient recovered almost a full range of motion in the knees within 3 months after the conversion operation (Fig. 5).

Discussion

In femoral bone lengthening, there are 2 primary methods using 2 different kinds of fixators: a ring-type Ilizarov external fixator, and a single-column Orthofix external fixator. Paley *et al.* [8] reported multiple complications in bone lengthening using the Ilizarov technique, and Grill *et al.* [9] reported that patients accept Orthofix external fixators better. In our department, distraction osteogenesis is performed using Orthofix external fixators according to the method by Bastiani *et al.* [10], except for cases with severe deformity that require three-dimensional correction. However, long lengthening distances require long-term use of external fixators until bone maturation is complete, making either method very inconvenient and stressful in the patient's daily life.

Wagner [11] reported a method of bone grafting and plate fixation after bone lengthening using single-

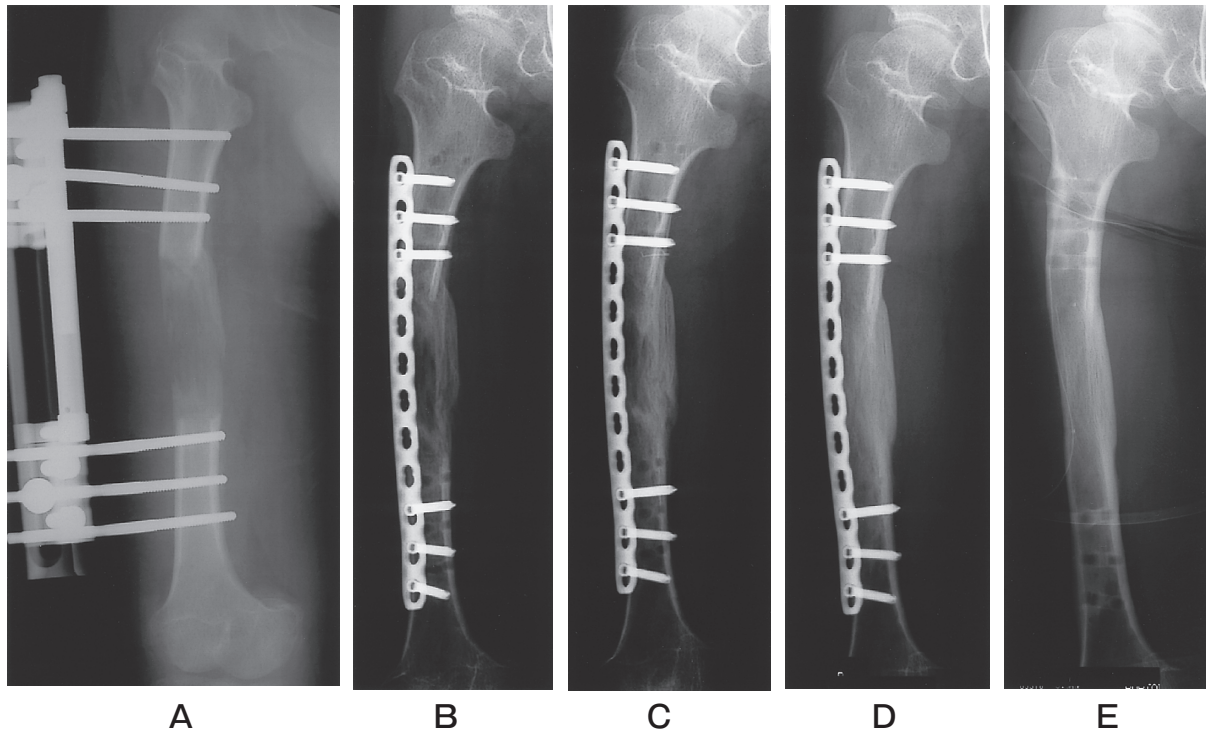


Fig. 3 The change of the femur on the radiographs before and after plating in Case No. 1. A, 1 month before plating; B, 1 month; C, 4 months; and D, 10 months after plating; E, 19 months after plating, after implant removal.

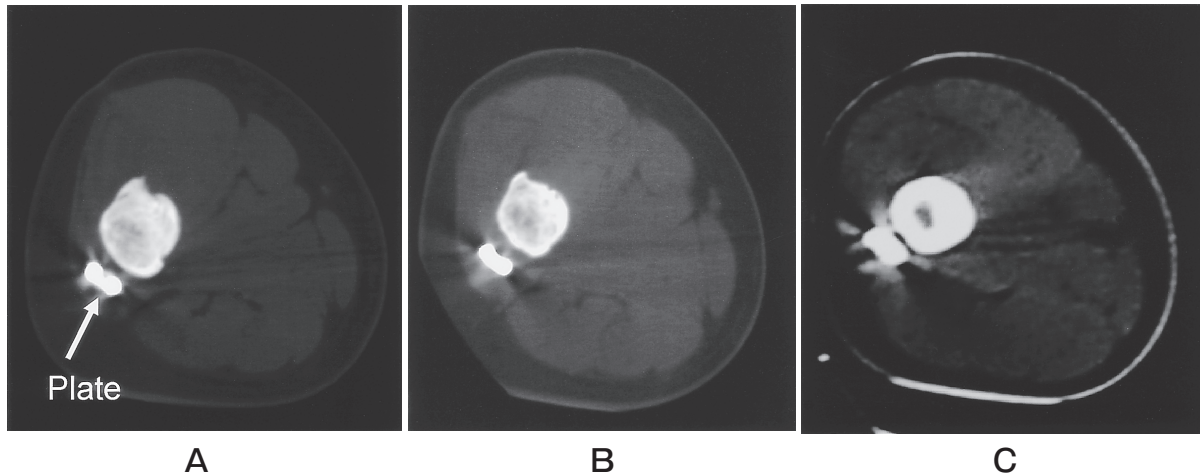


Fig. 4 The change of the femur on the computed tomograms after plating in Case No. 1. A, 3 months; B, 7 months; C, 18 months after plating.

column external fixators. However, Aaron *et al.* [12] compared the Wagner technique with the Ilizarov technique and reported that the Wagner technique had a longer consolidation index and multiple major com-

plications. In the technique described herein, there are some advantages over the Wagner technique. Our technique is less invasive with regard to the periosteum: using MIPO with an LCP, no bone graft is

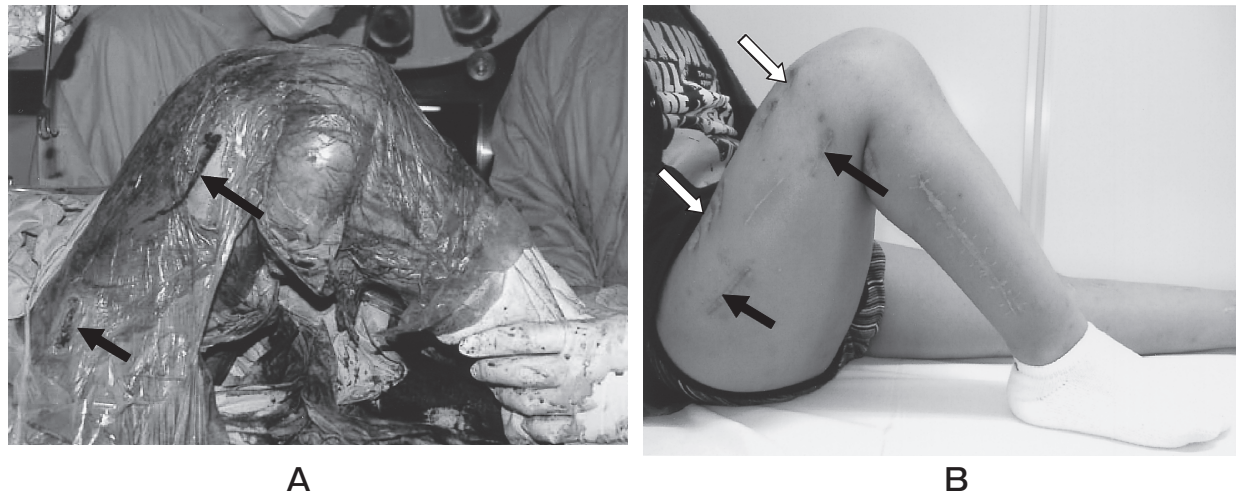


Fig. 5 Knee joint manipulation in Case No. 3.

A, surgical manipulation was performed temporarily in the plating operation. (black arrow, open incision of MIPPO); **B**, 3 months after plating, almost full range of knee motion was recovered (black arrow, open scar of MIPPO; white arrow, open external-fixator scar).

required. Furthermore, postoperative external fixation such as bracing or casting is not required because the LCP has excellent angular stability. In fact, no cases in this series showed a change in alignment after conversion operations.

Paley *et al.* [9] compared cases in which intramedullary nails were combined with external fixator in femoral lengthening to cases using the orthodox Ilizarov technique. They reported that the duration of external fixation was shorter in the cases with intramedullary nails, and that the prevention of recurrent fractures and early rehabilitation was possible. In their report, the mean duration of external fixation was 4 months, and the mean external-fixation index was 0.7 months/cm. There were differences in the waiting period prior to bone formation, but our cases had similarly good results compared with the cases using external fixators only (Table 2).

However, deep infections have been reported for bone lengthening procedures that incorporated intramedullary nails [8, 10], and there is a risk of infection caused by the contamination between external skeletal fixation screws and nails during bone lengthening. The MIPPO technique also involves a risk of infection, but it is predicted that the risk of intramedullary spreading of infections is lower than with the use of intramedullary nails. It is possible to postpone or skip the conversion from external fixation to inter-

nal fixation if blood tests and clinical findings indicate an active infection. In addition, bone lengthening with intramedullary nails may address simple lengthening, but it is difficult to use for cases involving the correction of a severe deformity. Our technique is also applicable to limbs that require deformity correction. Hankemeier *et al.* [13] reported lower limb lengthening using extensible intramedullary nails (Intramedullary Skeletal Kineticdistractor: ISKD, Orthofix, England). They reported that, bone lengthening with ISKDs was associated with less pain and fewer complications, shorter hospital stays and good range of motion for the joint. However, ISKDs cannot be applied to cases having an open epiphyseal line, a narrow and irregular medullary canal (less than 14.5mm for the femur and less than 12.5mm for the tibia), or severe deformity. The current method is more advantageous for diseases that cause narrow medullary canal and complicated deformity such as achondroplasia.

There are some potential problems with this method in addition to the risk of infection. While the requisite incisions are smaller, there are more of them, and patients are exposed to increased surgical stress because 2 additional procedures, including implant removal, are required. There may also be difficulty in removing the plates because of the use of titanium material. In Cases 3 and 4, the external-

Table 2 Comparison of the methods for femoral lengthening

	Mean distraction length (cm)	Mean duration of external fixation (month)	Mean external fixation index (month/cm)	Complication (limb/(%))		
				infection	knee joint contracture	fracture or deformity
Paley <i>et al.</i>						
External fixation only (29 cases 32 limbs)	5.2	7.5	1.7	2 (6%)	3 (9%)	8 (25%)
Intramedullary Nail (31 cases 32 limbs)	5.8	4	0.7	2 (6%)	1 (3%)	2 (6%)
Our result						
External fixation only (6 cases 8 limbs)	4.9	8.6	2.0	3 (38%)	3 (38%)	1 (13%)
Locking plate (3 cases 5 limbs)	5.8	4.4	0.8	0	2 (40%)	0

skeletal-fixation screws were inserted too anteriorly on the anterolateral side, causing joint contracture.

In this series, the duration of external fixation was decreased by conversion. However, the duration for sufficient callus formation using this technique was possibly longer than that of the cases treated by external fixation only. The fixation of an LCP is stronger than that of external fixation; callus formation may be prolonged by the rigidity of the fixation.

Conclusion. The MIPO technique using an LCP is a useful method for shortening the external skeletal fixation period in femoral lengthening.

References

- Sato W, Matsushita T and Nakamura K: Acceration of increase in bone mineral content by low-intensity ultrasound energy in leg lengthening. *J Ultrasound Med* (1999) 18: 699-702.
- Kitoh H, Kitakoji T, Tsuchiya H, Mitsuyama H, Nakamura H, Katoh M and Ishiguro N: Transplantation of marrow-derived mesenchymal stem cells and platelet-rich plasma during distraction osteogenesis-a preliminary result of three cases. *Bone* (2004) 35: 892-898.
- Lin CC, Huang SC, Liu TK and Chapman MW: Limb lengthening over an intramedullary nail. *Clin Orthop Relat Res* (1996) 330: 208-216.
- Paley D, Herzenberg JE, Paremian G and Bhawe A: Femoral lengthening over an intramedullary nail. *J Bone Joint Surg Am* (1997) 79: 1464-1480.
- Simpson AHR, Cole AS and Kenwright J: Leg lengthening over intramedullary nail. *J Bone Joint Surg Br* (1999) 81: 1041-1045.
- Farouk O, Krettek C, Miclau T, Schandelmaier P, Guy P and Tschernke H: Minimally invasive plate osteosynthesis: does percutaneous plating disrupt femoral blood supply less than the traditional technique? *J Orthop Trauma* (1999) 6: 401-406.
- Krettek C, Müller M and Miclau T: Evolution of Minimally invasive plate osteosynthesis (MIPO) in the femur. *Injury* (2001) 32: SC 14-23.
- Paley D: Problems, obstacles, and complication of limb lengthening by the Ilizarov technique. *Clin Orthop Relat Res* (1990) 250: 81-104.
- Grill F and Dungal P: Lengthening for congenital short femur. *J Bone Joint Surg Br* (1991) 73: 439-447.
- De Bastiani G, Aldegheri R, Renzi-Brivio L and Trivella G: Limb lengthening by callus distraction (callotaxis). *J Pediatr Orthop* (1987) 7: 129-134.
- Wagner H: Operative lengthening of the femur. *Clin Orthop Relat Res* (1978) 136: 125-142.
- Aaron AD and Eilert RE: Results of the Wagner and Ilizarov methods of limb limb-lengthening. *J Bone Joint Surg Am* (1996) 78: 20-29.
- Hankemeier S, Gössling T, Pape HC, Wiebking U and Krettek C: Limb lengthening with the intramedullary skeletal kinetic distractor (ISKD). *Oper Orthop Traumatol* (2005) 1: 79-101.

