

Original Article

Novel Magnetic Resonance Imaging Evaluation for Valgus Instability of the Knee Caused by Medial Collateral Ligament Injury

Hisanori Ikuma^a, Nobuhiro Abe^{b*}, Youichiro Uchida^c,
Takayuki Furumatsu^b, Kazuo Fujiwara^d, Keiichiro Nishida^e,
and Toshifumi Ozaki^d

^aDepartment of Orthopaedic Surgery, Kagawa Rosai Hospital, Marugame, Kagawa 763-8502, Japan,

^bDepartment of Orthopaedic Surgery, Okayama University Hospital, Okayama 700-8558, Japan,

^cDepartment of Orthopaedic Surgery, Nippon Kokan Fukuyama Hospital, Fukuyama, Hiroshima 721-0927, Japan,

Departments of ^dOrthopaedic Surgery, and ^eHuman Morphology, Okayama University Graduate School of Medicine,
Dentistry and Pharmaceutical Sciences, Okayama 700-8558, Japan

Instability of the knee after the medial collateral ligament (MCL) injury is usually assessed with the manual valgus stress test, even though, in recent years, it has become possible to apply magnetic resonance imaging (MRI) to the assessment of the damage of the ligament. The valgus instability of 24 patients (12 isolated injuries and 12 multiple ligament injuries) who suffered MCL injury between 1993 and 1998 was evaluated with the Hughston and Eilers classification, which involves radiographic assessment under manual valgus stress to the injured knees. We developed a novel system for classifying the degree of injury to the MCL by calculating the percentage of injured area based on MRI and investigated the relationship between this novel MRI classification and the magnitude of valgus instability by the Hughston and Eilers classification. There was a significant correlation between the 2 classifications ($p=0.0006$). On the other hand, the results using other MRI based classification systems, such as the Mink and Deutsch classification and the Petermann classification, were not correlated with the findings by the Hughston and Eilers classification in these cases ($p > 0.05$). Since MRI is capable of assessing the injured ligament in clinical practice, this novel classification system would be useful for evaluating the stability of the knee and choosing an appropriate treatment following MCL injury.

Key words: medial collateral ligament, magnetic resonance imaging, knee instability, novel method

Instability of the knee after injury to the medial collateral ligament (MCL) is still a serious problem in patients with multiple ligament injuries. In particular, when the anterior cruciate ligament (ACL) or the posterior cruciate ligament (PCL) is injured in

addition to the MCL, the outcome will depend on evaluation and treatment of the MCL injury [1-4]. MCL injury of the knee is usually assessed according to the classification of Hughston and Eilers [5], which involves manual evaluation of valgus instability of the knee. However, this classification occasionally requires anesthetization of the lower limbs for strict evaluation, and thus can be a somewhat invasive method.

Received October 4, 2007; accepted December 26, 2007.

*Corresponding author. Phone:+81-86-235-7273; Fax:+81-86-223-9727
E-mail:nobuabe@md.okayama-u.ac.jp (N. Abe)

In recent years, technical advances in magnetic resonance imaging (MRI) have led to more complete evaluation of the knee injury [6–10]. Various reports have been published concerning MRI-based classifications of MCL injury. At present, there are 2 main MRI classification systems, the classification of Mink and Deutsch [8] for evaluating superficial injury to the MCL and that of Petermann [11] for evaluating injury to both the superficial and deep layers of the ligament. It has occasionally been reported that these methods of evaluation do not correlate with the classification of Hughston and Eilers and thus do not adequately evaluate instability of the knee [12–13].

The objective of this study was to investigate whether or not these MRI classifications can adequately evaluate valgus instability of the knee and to discuss a novel MRI classification that could assess valgus instability more effectively.

Materials and Methods

The subjects of this study were 24 patients (24 knees) who suffered MCL injury and were treated in Nippon Kokan Fukuyama Hospital between 1993 and 1998. Isolated MCL injury was noted in 12 knees of 12 patients (7 males and 5 females), and their age range was 17 to 38 years (mean: 28.0 years). Multiple ligament injury was noted in 12 knees of 12 patients (7 males and 5 females), and their age range was 16 to 51 years (mean: 36.7 years). In the multiple ligament injury group, the ACL, PCL, and both were injured in 9, 2, and 1 of the patients, respectively. Knee surgery was performed by a single orthopaedic surgeon who had 15 years of clinical experience, and the site of MCL injury was confirmed intraoperatively in

all patients.

MRI method. In all patients, MRI was performed within 1 week of injury and a 0.5 T system (MR Vectra; GE Medical Systems, Milwaukee, WI, USA) was used for imaging. MCL injury was evaluated on T2-weighted coronal images, which were obtained by the fast spin echo method. With the patient in the supine position and the knee completely extended, MRI was performed using superficial leg coils and the following parameters: TR/TE of 3000/21, flip angle of 30 degrees, 3.0 mm slice thickness and 3.0 mm gap, FOV of 200 mm, and 192 × 256 matrix.

Evaluation of valgus instability. After muscular relaxation was achieved under anesthesia, the knee was flexed to 30 degrees, and valgus instability was evaluated manually according to the classification of Hughston and Eilers (Table 1). This classification evaluates the extent of valgus instability of the knee after MCL injury using a 3 grade scale based on the distance between the medial articular surface of the femur and the medial articular surface of the tibia on frontal X-ray films. If the distance is less than 5 mm, 5 to 10 mm, or more than 10 mm, valgus instability is classified as Grade 1, 2, or 3, respec-

Table 1 Grading of lateral instability of the knee

	Medial joint opening
Grade 1	5 mm or less
Grade 2	between more than 5 mm to 10 mm
Grade 3	more than 10 mm

According to Hughston and Eilers^[5], the 3-degree sprains can be graded according to the amount of medial joint opening demonstrated on stress testing.

Table 2 Classification of MCL injury for MRI

	Mink and Deutsch	Petermann
Grade I	Edema and hemorrhage within the ligament (Ligament continuity intact)	Periligamentous swelling without complete disruption of superficial and/or deep layer (Minor tearing of Ligament)
Grade II	Localized hemorrhage (Partial ligament disruption)	Conform Grade I but with complete disruption of superficial layer (Complete disruption superficial layer)
Grade III	Marked hemorrhage and thickening (Complete disruption)	Conform Grade II but with fluid extravasating from the joint into the periligamentous tissue (Complete disruption superficial and deep layer)

tively. Thus, the grade becomes higher with an increase in the extent of instability [5].

Evaluation of MRI findings. The images obtained by MRI were evaluated by 3 orthopaedic surgeons who had more than 10 years of clinical experience and who had no knowledge of the clinical or intra-operative findings. Each image was evaluated according to the classification of Mink and Deutsch, the classification of Petermann (Table 2), and our novel classification. According to the classifications of Mink and Deutsch and Petermann, MCL injury exists if swelling and hematoma (seen as a high-signal intensity area) are noted around the ligament, or if discontinuity of the ligament is observed on T2-weighted images. All patient information was removed from the images, and the surgeons were only told that the patients had a pain in the knee and gait disturbance. Each image was assessed for 10 min.

Novel MRI classification. The subjects were patients who were considered to have MCL injury according to the above criteria. Hemorrhage and swelling around the MCL were evaluated by MRI, and all coronal images of the knee including the ligament were assessed. The maximum transverse diameter of the high signal intensity area around the site of injury was measured on T2-weighted images. This was then divided by the maximum transverse diameter of the articular surface of the tibia to standardize its value because of anatomical variation and the result thus obtained was multiplied by 100. This ratio was designated as the MCL instability ratio (Fig. 1).

Evaluation of the relationship between MRI classifications and valgus instability. The results of the classification of Mink and Deutsch, that of Petermann, and our novel classification were compared with the results of the classification of Hughston and Eilers to investigate the relationship between these MRI classification systems and valgus instability of the knee.

Statistical analysis. The data obtained were analyzed by Spearman's rank correlation analysis, and $p < 0.05$ was considered to indicate statistical significance. The statistical analysis was carried out using the program Ystat 2006 for Windows program (Igakutoshoshuppan Co., Ltd., Tokyo, Japan).

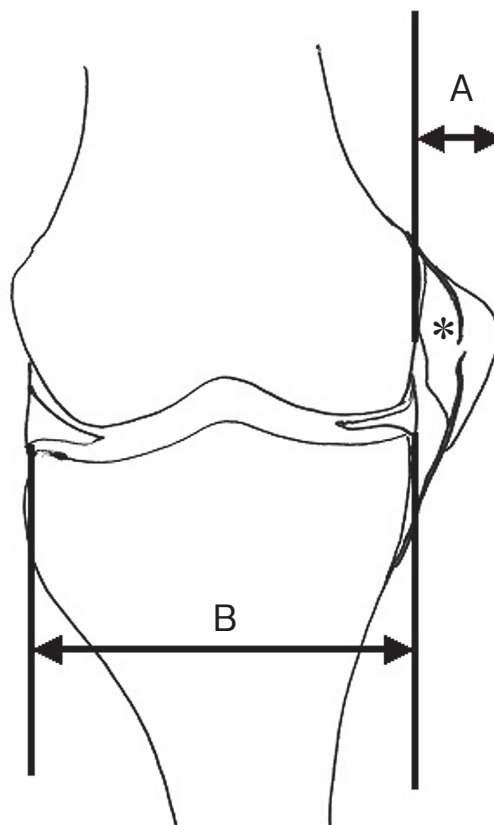


Fig. 1 MCL Instability ratio: $A/B \times 100$

A, The maximum transverse diameter of the high signal intensity area on T2-weighted images; **B**, The maximum transverse diameter of the articular surface of the tibia; *, The high signal area of hemorrhage and swelling caused by MCL injury on T2-weighted images.

Results

Evaluation of valgus instability. When using the classification of Hughston and Eilers, the extent of instability was respectively classified as Grade 1, 2, and 3 in 25.0%, 58.3%, and 16.7% of patients from the isolated MCL injury group, while it was classified as Grade 1, 2, and 3 in 8.3%, 50.0%, and 41.7% of patients from the multiple injury group. Intraoperative findings confirmed femoral side injury, mid-substance injury, and tibial side injury in 75.0%, 8.3%, and 16.7% of the isolated MCL injury group respectively, versus 58.3%, 33.3%, and 8.3% of the multiple injury group (Table 3).

When the extent of instability was evaluated according to the classification of Hughston and Eilers

in all patients from both groups, it was classified as Grade 1 in 12.5% of the patients with femoral side injury, 4.2% of the patients with mid-substance injury, and 0% of the patients with tibial side injury. It was classified as Grade 2 in 41.7%, 8.3%, and 4.2% of these patients, respectively, and as Grade 3 in 12.5%, 8.3%, and 8.3%. The percentage of patients with femoral side injury was higher in all grades (Table 4).

Evaluation of correlations between MRI findings and valgus instability. No correlation was noted between the classification of Hughston and Eilers and that of Mink and Deutsch in the isolated MCL injury or multiple ligament injury groups ($p > 0.05$). Grade 2 instability according to the classification of Hughston and Eilers tended to be classified as Grade III according to the classification of Mink and Deutsch in both groups (Table 5). There were no correlations between the classification of Hughston and Eilers and that of Petermann in either of the ligament

Table 3 Surgical population by Hughston and Eilers classification, intra-operative findings

Hughston and Eilers classification	Isolate injury	Multiple injury
Grade 1	3 (25.0)	1 (8.3)
Grade 2	7 (58.3)	6 (50.0)
Grade 3	2 (16.7)	5 (41.7)

intra-operative findings	Isolate injury	Multiple injury
Femoral	9 (75.0)	7 (58.3)
Mid-substance	1 (8.3)	4 (33.3)
Tibial	2 (16.7)	1 (8.3)

Note: -Numbers in parenthesis are percentages.

Table 4 Relationship between Hughston and Eilers classification and intra-operative findings

Hughston and Eilers classification	Injury location		
	Femoral side	Mid-substance	Tibial side
Grade 1	12.5	4.2	0
Grade 2	41.7	8.3	4.2
Grade 3	12.5	8.3	8.3

Note: -Numbers are percentages.

injury groups ($p > 0.05$). Grade 2 instability according to the classification of Hughston and Eilers tended to be classified as Grade III according to the classification of Petermann, and the extent of injury was evaluated as higher than that of valgus instability according to this classification as well as that of Mink and Deutsch (Table 6). Based on these results, it was considered to be difficult to evaluate valgus instability of the knee after MCL injury by the classification of Mink and Deutsch or that of Petermann. On the other hand, a correlation was noted between the MCL instability ratio and valgus instability of the knee in

Table 5 Relationship between Mink and Deutsch and Hughston and Eilers classification

Mink and Deutsch classification		Hughston and Eilers classification		
		1	2	3
Isolate injury	I	1-1-0	1-1-1	1-0-0
	II	2-1-1	3-0-3	1-1-1
	III	0-1-2	3-6-3	0-1-1
Multiple injuries	I	1-0-1	1-0-1	1-0-0
	II	0-1-0	3-1-0	1-1-2
	III	0-0-0	2-5-5	3-4-3

($p > 0.05$)

Note: -Numbers are numbers of patients who evaluated their MRI findings by 3 orthopaedists. Numbers correspond to Orthopaedist 1-Orthopaedist 2-Orthopaedist 3.

Table 6 Relationship between Petermann and Hughston and Eilers classification

Petermann classification		Hughston and Eilers classification		
		1	2	3
Isolate injury	I	1-1-1	1-1-1	1-1-1
	II	1-1-1	1-3-6	1-1-1
	III	1-1-1	5-3-0	0-0-0
Multiple injuries	I	1-1-1	0-1-2	0-1-1
	II	0-0-0	2-1-1	1-0-4
	III	0-0-0	4-4-3	4-4-0

($p > 0.05$)

Note: -Numbers are numbers of patients who evaluated their MRI findings by 3 orthopaedists. Numbers correspond to Orthopaedist 1-Orthopaedist 2-Orthopaedist 3.

the isolated MCL injury group ($p=0.0105$) (Fig. 2) and in the multiple ligament injury group ($p=0.0235$) (Fig. 3). A correlation ($p=0.0006$) was also noted when analysis was done using patients from both groups. Based on the regression line obtained from these data, the extent of valgus instability was evaluated using the 3-grade scale in the classification of Hughston and Eilers (Grade 1: less than 5 mm; Grade 2: 5 to 10 mm; Grade 3: more than 10 mm). According to the MCL instability ratio, less than 4.66%, 4.66% to 12.49% and 12.49% or more of the patients were classified as having Grade I, II, and III instability, respectively (Fig. 4).

Discussion

The MCL is the most important and strongest of the medial supporting mechanisms of the knee, being the main stabilizing mechanism against stress of the valgus and external rotation [14]. In fact, it accounts for 78% of the braking effect against valgus stress when the knee is in 25 degrees of flexion [15]. Therefore, poor healing of an MCL injury may lead to persistent instability of the knee, resulting in potential knee deformity in the future. Particularly after multiple ligament injury, evaluating the extent and healing of MCL injury has been reported to be important because of the high risk of persistent knee instability [16].

The treatment of MCL injury is often chosen solely on the basis of manual evaluation of the extent of valgus instability. However, it has been reported to be

difficult to achieve uniformly accurate evaluation using the manual method because of pain and muscle spasm after injury [17-19]. The clinical course is often poor in patients with Grade III MCL injury [1], and there is still controversy as to whether damage to this ligament should be treated conservatively or by surgery, especially in patients who have multiple ligament injury. Therefore, it is necessary to establish a method by which preoperative evaluation can be performed accurately.

In recent years, numerous studies have used MRI to evaluate MCL injury by MRI have been reported [6-13, 20, 21], and the classification of Mink and Deutsch, and that of Petermann have come into general use. In these 2 classifications systems, MCL injury is evaluated based on discontinuity of the liga-

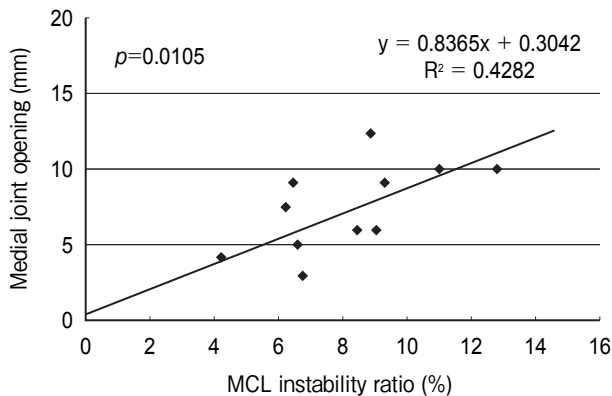


Fig. 2 Medial joint opening VS MCL instability ratio in the isolated injury group.

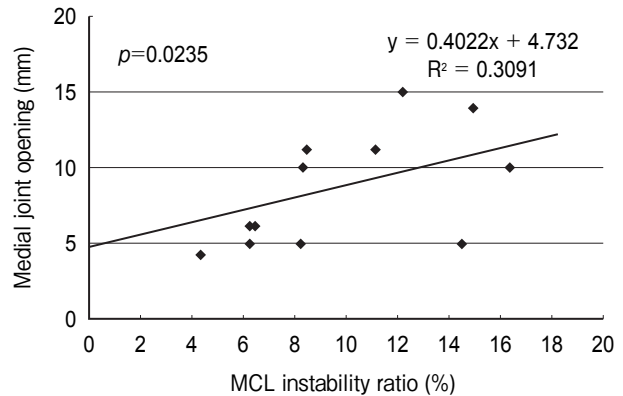


Fig. 3 Medial joint opening VS MCL instability ratio in the multiple injury group.

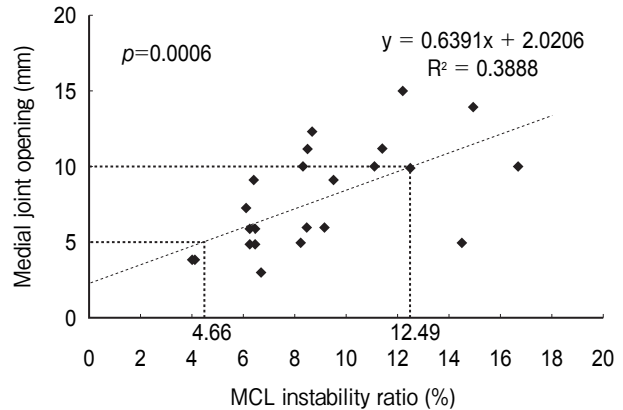


Fig. 4 Medial joint opening VS MCL instability ratio in the isolated and multiple injury group.

ment and hemorrhage and swelling at the site of injury. It has not been clarified how accurately these classifications can evaluate valgus instability of the knee. It was reported that comparison between the classification of Mink and Deutsch and that of Hughston and Eilers showed that the MRI classification tended to overestimate valgus instability [13, 22]. On the other hand, when the classification of Petermann was used, valgus instability could be evaluated if a valgus-varus laxity tester was used, but it could not be evaluated easily by the manual method [23]. Considering that manual evaluation is often performed in clinical practice, it would seem to be necessary to establish a classification system for the evaluation of knee instability by MRI alone. In this study, there was no correlation between either of the MRI classifications and the Hughston and Eilers classification. These results demonstrate that there are many differences related to interobserver variability between these 2 classification systems, and that valgus instability of the knee cannot be accurately evaluated by either method. Therefore, we investigated the efficacy of our novel MRI classification system “the MCL instability ratio”, for evaluating valgus instability of the knee after MCL injury.

According to a recent report concerning MRI evaluation of isolated MCL injuries, periligamentous swelling and hemorrhage generally tend to be mild, so deep layer injury can only be evaluated by focusing attention on irregularity of the lateral margin of the meniscus and changes in the composition of the meniscocapsular fluid [21]. On the other hand, in the case of multiple ligament injury, it is possible to evaluate deep layer injury by focusing attention on the leakage of articular fluid around the MCL [11]. Thus, these reports concentrated on the diagnosis of MCL injury based of MRI visualization of articular fluid leakage and hemorrhage. Since hemorrhage and swelling tend to occur with an increase in the extent of MCL injury, MRI-based evaluation may become easier as the damage becomes more severe. We developed our novel MRI classification system by focusing attention on differences in the extent of periligamentous hemorrhage and swelling in relation to the extent of ligament injury (Fig. 5). According to the classification of Mink and Deutsch and that of Petermann, MCL injury is considered to be present when periligamentous swelling and hematoma and ligament injury can be

detected, so these changes were selected for classification by our method. T2-weighted images were used, because a high signal intensity is displayed due to an increase of regional water content after hemorrhage in the acute period immediately after injury [24]. MRI was performed within 1 week of injury, because the high signal intensity on T2-weighted images decreases after 7 days along with a decrease of the water content and an increase of the protein content [24]. All coronal images that included the MCL were used for our method of evaluation. Assuming that the high signal intensity area on T2-weighted images corresponded to hemorrhage and swelling, its maximum transverse diameter was measured. The ratio of this diameter to the maximum transverse diameter of the tibial articular surface was calculated while controlling for differences in body size among the subjects. Since this ratio showed a good correlation with the extent of valgus instability of the knee, it was consid-

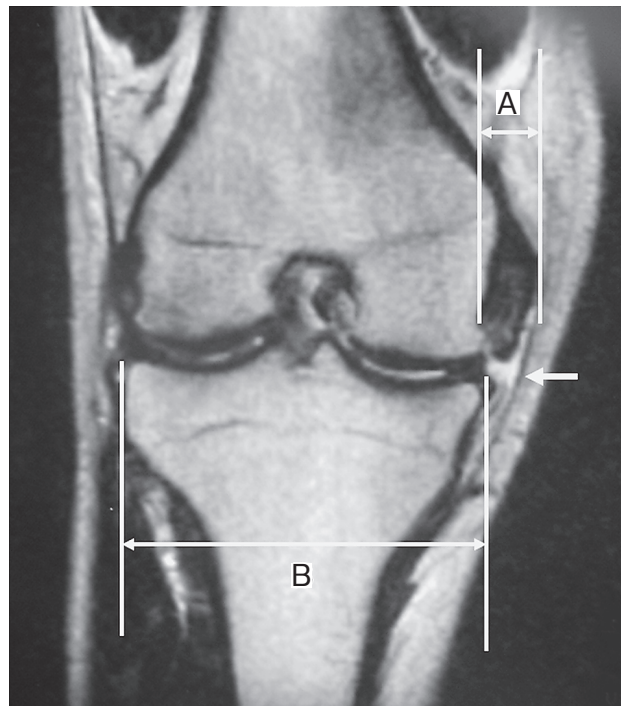


Fig. 5 This 16-year-old male suffered MCL and ACL injury while playing rugby football and his knee showed Grade 3 instability by the Hughston and Eilers classification. This MRI shows the T2-weighted image. **A**, the maximum transverse diameter of the area of hemorrhage and swelling; **B**, the maximum transverse diameter of the articular surface of the tibia. White arrow shows discontinuity of MCL and leakage of articular fluid.

ered possible to use this method to evaluate valgus instability by MRI alone without manual evaluation. Finally, the MCL instability ratio was divided into three grades by using values that corresponded to Grades 1 to 3 of the Hughston and Eilers classification.

Unlike the conventional classifications, our novel MRI classification has the advantage that there is little risk of variation between examiners, because it is not necessary to perform the valgus stress test of the knee manually, and because numerical values obtained by making measurements on the images are compared. In future studies, it will be necessary to accumulate more data about the clinical course of patients evaluated by this classification. However, since MRI is widely available at present, the assessment of valgus instability of knees with MCL injury by this novel MRI classification system would be useful in clinical practice.

References

- Fetto JF and Marshall JL: Medial collateral ligament injury of the knee: A rationale for treatment. *Clin Orthop Relat Res* (1978) 132: 206-218.
- Hughston JC and Barrett GR: Acute anteromedial rotatory instability. Long-term results of surgical repair. *J Bone Joint Surg Am* (1983) 65: 145-153.
- Shelbourne KD and Porter DA: Anterior cruciate ligament- medial collateral ligament injury: non operative management of medial collateral ligament tear with anterior cruciate ligament reconstruction-a preliminary report. *Am J Sports Med* (1992) 20: 283-286.
- Woo SL, Vogrin TM and Abramowitch SD: Healing and repair of ligament injuries in the knee. *J Am Acad Orthop Surg* (2000) 8: 364-372.
- Hughston JC and Eilers AF: The role of the posterior oblique ligament in repairs of acute medial collateral ligament tears of the knee. *J Bone Joint Surg Am* (1973) 55: 923-940.
- Rubin DA, Kettering JM, Towers JD and Britton CA: MR imaging of knee having isolated and combined ligament injuries. *Am J Roentgenol* (1998) 170: 1207-1213.
- Bassett LW, Grover JS and Seeger LL: Magnetic resonance imaging of the knee trauma. *Skeletal Radiol* (1990) 19: 401-405.
- Mink JH and Deutsch AL: Magnetic resonance imaging of the knee. *Clin Orthop Relat Res* (1989) 244: 29-47.
- Turner DA, Prodromos CC, Petasnick JP and Clark JW: Acute injury of the ligament of the knee: Magnetic resonance evaluation. *Radiology* (1985) 154: 717-722.
- Gallimore GW and Harms SE: Knee injuries: High-resolution MR imaging. *Radiology* (1986) 160: 457-461.
- Petermann J, Garrel T and Gotzen L: Non-operative treatment of acute medial collateral ligament lesions of the knee joint. *Knee Surg Sports Traumatol Arthrosc* (1993) 1: 93-96.
- Schweitzer ME, Tran D, Deely DM and Hume EL: Medial collateral ligament injuries: evaluation of multiple signs, prevalence and location of associated bone bruises, and assessment with MR imaging. *Radiology* (1995) 194: 825-829.
- Mirowitz SA and Shu HH: MR imaging evaluation of the knee collateral ligaments and related injuries: comparison of T1-weighted, T2-weighted, and Fat-saturated T2-weighted sequences-correlation with clinical findings. *J Magn Reson Imaging* (1994) 4: 725-732.
- Warren LA, Marshall JL and Girgis F: The prime static stabilizer of the medial side of the knee. *J Bone Joint Surg Am* (1974) 56: 665-674.
- Grood ES, Noyes FR, Butler DL and Suntay WJ: Ligamentous and capsular restraints preventing straight medial and lateral laxity in intact human cadaver knees. *J Bone Joint Surg Am* (1981) 63: 1257-1269.
- Nakamura N, Horibe S, Toritsuka Y, Mitsuoka T, Yoshikawa H and Shino K: Acute grade III medial collateral ligament injury of the knee associated with anterior cruciate ligament tear. The usefulness of magnetic resonance imaging in determining a treatment regimen. *Am J Sports Med* (2003) 31: 261-267.
- Burger RS and Larson RL: Acute ligamentous injury; in *The knee*, Larson RL and Grana WA eds, PA Saunders, Philadelphia (1993) pp 514-598.
- Larson RL: Evaluation and decision making for ligamentous injury; in *The knee*, Larson RL and Grana WA eds, PA Saunders, Philadelphia (1993) pp 492-500.
- Andrish JT: Ligamentous injuries of the knee. *Prim Care* (1984) 11: 77-88.
- Garvin GJ, Munk PL and Vellet AD: Tears of the medial collateral ligament: Magnetic resonance imaging findings and associated injuries. *Can Assoc Radiol J* (1993) 44: 199-204.
- De Maeseneer M, Shahabpour M, Vanderdood K, van Roy F and Osteaux M: Medial meniscocapsular separation: MR imaging criteria and diagnostic pitfalls. *Eur J Radiol* (2002) 41: 242-252.
- Yao L, Dungan D and Seeger LL: MR imaging of tibial collateral ligament injury: Comparison with clinical examination. *Skeletal Radiol* (1994) 23: 521-524.
- Rasenberg EI, Lemmens JA, van Kampen A, Schoots F, Bloo HJ, Wagemakers HP and Blankevoort L: Grading medial collateral ligament injury: comparison of MR imaging and instrumented valgus-varus laxity test-device. A prospective double-blind patient study. *Eur J Radiol* (1995) 21: 18-24.
- Stoller DW: *Magnetic resonance imaging in orthopaedics and sports medicine*, 2nd Ed, Lippincott-Raven, Philadelphia (1997) pp 1355-1356.

