

Original Article

Venous Velocity of the Right Femoral Vein Decreases in the Right Lateral Decubitus Position Compared to the Supine Position: A Cause of Postoperative Pulmonary Embolism?

Itaru Nagahiro^{a*}, Yutaka Watanuki^b, Shizou Sato^a, and Akira Nakashima^a

^aDepartment of Surgery, and ^bUltrasonic Laboratory, Himeji Red Cross Hospital, Himeji, Hyogo 670-8540, Japan

The right lateral decubitus position is a risk factor for postoperative pulmonary embolism. We examined postural changes of femoral vein velocity in order to elucidate the mechanism. Thirty patients scheduled for general thoracic surgery were enrolled in this study. The common femoral veins on both sides were examined by color-duplex ultrasound for venous caliber and velocity when the patients were in the right lateral, left lateral, and supine positions. The maximum diameters of the right femoral vein in the right lateral decubitus position and the left femoral vein in the left decubitus position were significantly larger than those in the other positions. The venous velocity of the right femoral vein in the right lateral decubitus position was significantly smaller than that in the supine position, while the velocity of the left femoral vein in the left lateral decubitus position was not significantly decreased. We speculate that the decreased venous velocity of the right femoral vein in the right lateral decubitus position could result in a deep venous thromboembolism in the right leg, making this position a possible risk factor for postoperative pulmonary embolism.

Key words: pulmonary embolism, deep venous thromboembolism, femoral vein velocity, lateral decubitus position, operative position

Postoperative pulmonary embolism (PE) is an often fatal complication in general thoracic surgery as well as other surgical procedures. Tremendous effort has been employed to reduce the risk of PE by such methods as subcutaneous injection of heparin and/or application of an intermittent pneumatic compression (IPC) device. We routinely apply IPC to all patients undergoing surgical procedures at our institution, but prior to the use of routine IPC we sometimes experience fatal postopera-

tive PE. In a previous report we reviewed the clinical records of patients who underwent general thoracic surgery and confirmed the efficacy of IPC in the prevention of postoperative PE [1]. In that study we also determined that placing the patient in the right decubitus position during the operation is a risk factor for postoperative PE. Although we were not able to determine the cause for this added risk, certain postural, anatomical, and physiological reasons were suspected, such as iliac compression syndrome (May-Thurner syndrome). In addition, alterations in blood flow in the lower extremities in the lateral decubitus position have not been clearly demonstrated. Therefore, we investigated changes in the

Received August 3, 2006; accepted October 31, 2006.

*Corresponding author. Phone: +81-79-294-2251; Fax: +81-79-296-4050
E-mail: inagahiro@hrc-hp.com (I. Nagahiro)

venous velocity based on body positioning to determine the mechanism of postoperative PE that frequently occurs in patients in the right lateral decubitus position.

Patients and Methods

Thirty patients scheduled to undergo general thoracic surgery were enrolled in this study (Table 1). None of the patients had previously experienced any episodes of deep venous thrombosis (DVT), varicose veins in the lower extremities, or PE. Written informed consent was obtained from all patients. We used color-duplex ultrasound (Aplio, 7.5 MHz linear probe, Toshiba Co. Ltd, Tokyo, Japan) to examine the venous blood flow. The maximum caliber and venous velocity in the common femoral vein was measured during normal quiet respiration in a draught-

free room at 21 °C (Fig. 1). The measurement was performed for both legs in the supine position, the right lateral decubitus position, or the left lateral decubitus position for each patient. During the measurement, the patients' legs were left extended in a horizontal position. Data were analyzed by one-way ANOVA with Tukey-Kramer's test or by the Mann-Whitney u-test. A probability value of less than 0.05 was considered significant.

Results

The diameters of the right femoral vein in the right lateral decubitus position (1.31 ± 0.27 cm) and left femoral vein in the left decubitus position (1.21 ± 0.31 cm) were significantly larger than those in the other positions (Fig. 2). The venous velocity of the left femoral vein increased in the right lateral decubitus position (11.7 ± 8.5 cm/sec), but decreased in the left decubitus position (8.1 ± 4.3 cm/sec) compared to the supine position (11.1 ± 5.0 cm/sec). There was a significant difference between the venous velocity of the right and left lateral decubitus positions, but no difference between the lateral decubitus and supine positions (Fig. 3). In contrast, the venous velocity of the right femoral vein in the right lateral decubitus position (7.3 ± 0.5 cm/sec) was significantly smaller than that of the supine position (11.3 ± 6.4 cm/sec), and the velocity of the left lateral decubitus position (10.1 ± 5.7 cm/sec) was the

Table 1 Patient characteristics

| | | |
|-----------------|-----------|-----------------|
| Gender | Male | 14 |
| | Female | 16 |
| Age | | 62.4 ± 13.6 |
| Body Mass Index | | 21.0 ± 3.0 |
| Disease | Malignant | 16 |
| | Benign | 14 |

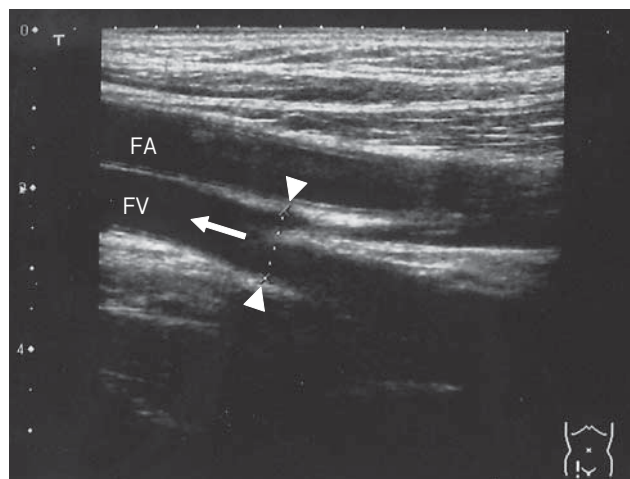


Fig. 1 Ultrasonography of the right common femoral vein. The maximum diameter of the femoral vein (arrow head) and the velocity of the femoral vein (arrow) were detected. FA, femoral artery; FV, femoral vein.

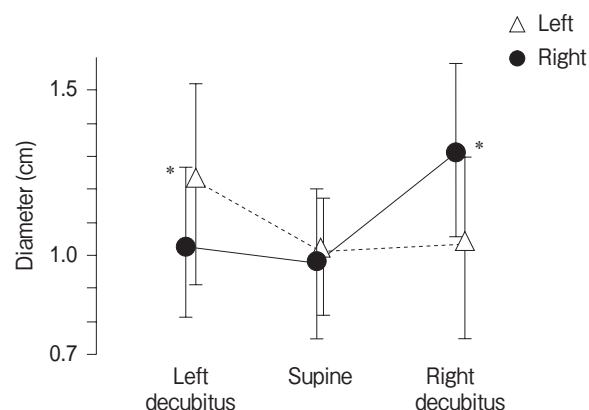


Fig. 2 The diameter of the common femoral veins in the right lateral, left lateral, and supine positions. Data are expressed as a mean \pm standard deviation of the mean. *: $p < 0.05$ compared to other positions.

same as that of the supine position. There was no significant difference between the venous velocity of the right and left lateral decubitus positions (Fig. 3). Additionally, to examine the relationship between the change in the venous velocity and body mass index (BMI), the patients were divided into 2 groups according to their BMI (low: BMI \leq 22, n = 19, high: BMI > 22, n = 11). The venous velocity in the high BMI group significantly increased in the lateral positions where the femoral vein was in the above

side (*i.e.* the right femoral vein in the left decubitus position and the left femoral vein in the right decubitus position) compared to the velocity in the below side (*i.e.* the right femoral vein in the right decubitus position and the left femoral vein in the left decubitus position), but it was not seen in the low BMI group (Fig. 4). There was a significant difference between the velocities of the right femoral vein in the right lateral decubitus or supine position in the low BMI group (7.7 ± 2.8 and 11.4 ± 6.2 cm/sec, respectively), but the difference was not seen in the high BMI group.

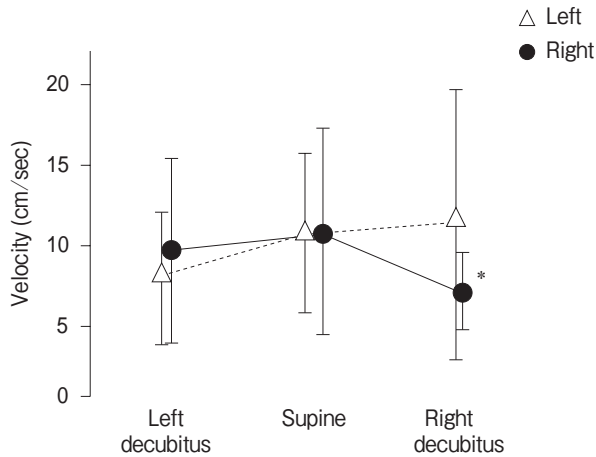


Fig. 3 The venous velocity of the common femoral veins in the right lateral, left lateral, and supine positions. Data are expressed as a mean \pm standard deviation of the mean. *: $p < 0.05$ compared to the supine position.

Discussion

Many acquired risk factors of DVT have been previously defined, including recent malignancy, major surgical procedures, trauma, prolonged immobilization, pregnancy or use of oral contraceptives, an underlying inflammatory state, or a previous history of venous thromboembolism [2]. We have previously reported that the incidence of postoperative PE is 2% in patients who have undergone general thoracic surgery, and have also determined that the right lateral decubitus position is a risk factor for PE [1]. We have suspected that postural changes of venous velocities in the lower extremities are affected, making the right lateral decubitus position a risk factor for PE. We are aware of some limitations in the present study: Firstly, all data were

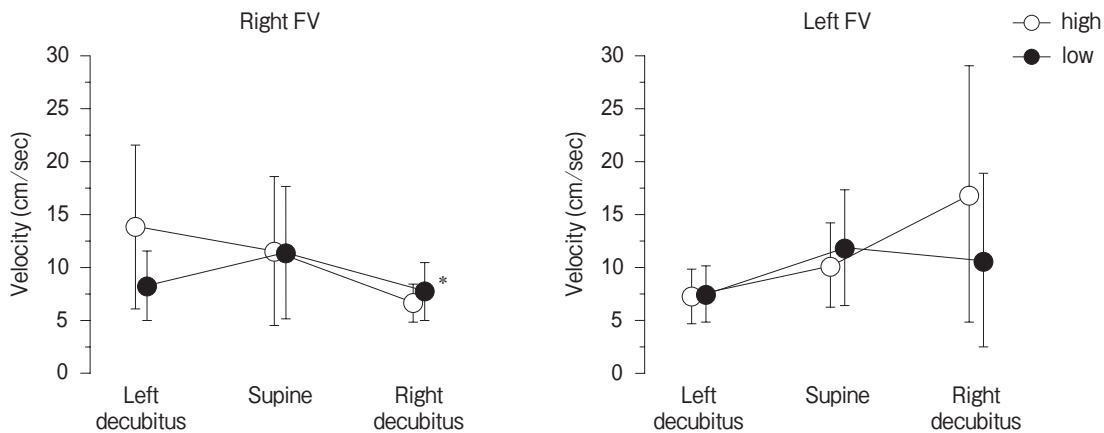


Fig. 4 The venous velocity of the common femoral veins divided by body mass index (BMI) of the patients (low: BMI \leq 22, n = 19, high: BMI > 22, n = 11). Data are expressed as a mean \pm standard deviation of the mean. *: $p < 0.05$ compared to the supine position. FV, femoral vein.

obtained from awake and spontaneously breathing patients. General anesthesia and mechanical ventilation undoubtedly influence venous return and venous tone, causing some changes in the venous velocity of the femoral veins. Secondly, both legs were extended in this study for easier measurement, but the leg on the lower side in the lateral position was routinely flexed slightly in practical operations. The difference in leg position might also influence the femoral vein velocities. Despite these limitations, it is worthwhile to understand the postural alteration of venous velocity in the femoral veins.

The results confirmed venous dilatation due to gravity, which was expected, but the postural changes in venous velocity were complicated. Velocity changes in the left femoral vein were linear, *i.e.* highest at the right lateral decubitus position and lowest at the left lateral decubitus position, and there was no significant difference between the velocities in the left decubitus or supine positions. In contrast, the venous velocity of the right femoral vein was lowest at the right decubitus position, similar to the left side, but was significantly lower than the velocities in the supine position. Additionally, the velocity in the left decubitus position was at the same level as the velocity in the supine position and did not increase, as seen in the left femoral vein in the right lateral decubitus position. We speculated that the difference in velocities between the right and left femoral veins was not induced from iliac vein compression syndrome since it affected only the left femoral vein [3, 4]. It has previously been demonstrated that the venous velocity of the femoral veins in the supine position increases linearly when the legs are tilted to 12° [5]. In the present study, the change in velocity of the left femoral vein was also linear. Thus, the linear change in velocity of the left femoral vein is influenced primarily by gravity and not by iliac compression syndrome. In contrast, the change in venous velocity of the right femoral vein was not linear, but was significantly decreased in the right lateral decubitus position and did not increase in the left lateral decubitus position when compared to the supine position. This nonlinear change may be a result of the position of the inferior vena cava (IVC). Since the IVC lies to the right of the vertebral column [6], the pressure gradient between the right femoral vein and the IVC might be lower in the left

lateral decubitus position than the gradient between the left femoral vein and IVC in the right lateral decubitus position. This pressure gradient may explain why the venous velocity of the right femoral vein did not increase as it did in the left femoral vein in the left decubitus position.

The cause of the significant decrease in venous velocity seen in the right femoral vein in the right lateral decubitus position when compared to the supine position could not be determined. However, it is speculated that 1) the IVC may be compressed by abdominal viscera in the right lateral decubitus position, resulting in decreased blood return from the lower extremities; or 2) sympathetic tone is lower in the right decubitus position [7] and peripheral venous dilatation may occur, which may decrease venous return and velocity. Further studies are necessary to elucidate the mechanism of decrease. Obesity is an obvious risk factor for PE, and some differences in the change in venous velocity according to the BMI were demonstrated in this study. Unfortunately, there were no significant differences between the velocities of the right femoral vein in the supine or right decubitus position in the high BMI group, which may be attributable to the small number of patients.

Decreased venous velocity is an important factor in venous thromboembolism, and increased venous velocity was confirmed in many prophylactic measures, including IPC devices [5, 8–11]. Given the present results, we speculate that decreased venous velocity of the right femoral vein in the right lateral decubitus position may cause development of DVT in the right leg during surgery. Thus, the right lateral decubitus position may be a risk factor for postoperative PE after general thoracic surgery.

References

1. Nagahiro I, Andou A, Aoe M, Sano Y, Date H and Shimizu N: Intermittent pneumatic compression is effective in preventing symptomatic pulmonary embolism after thoracic surgery. *Surg Today* (2004) 34: 6–10.
2. Fraser JD and Anderson DR: Deep venous thrombosis: Recent advances and optimal investigation with US. *Radiology* (1999) 211: 9–24.
3. Forauer AR, Gemmete JJ, Dasika NL, Cho KJ and Williams DM: Intravascular ultrasound in the diagnosis and treatment of iliac vein compression (May-Thurner) syndrome. *J Vasc Interv Radiol* (2002) 13: 523–527.

4. Fraser DG, Moody AR, Martel A and Morgan PS: Re-evaluation of iliac compression syndrome using magnetic resonance imaging in patients with acute deep venous thromboses. *J Vasc Surg* (2004) 40: 604-611.
5. Ashby EC, Ashford NS and Campbell MJ: Posture, blood velocity in common femoral vein, and prophylaxis of venous thromboembolism. *Lancet* (1995) 345: 419-421.
6. Clemente CD: *Anatomy*. 3rd Ed, Urban & Schwarzenberg, Baltimore (1987) Fig. 321.
7. Martin-Du Pan RC, Benoit R and Girardier L: The role of body position and gravity in the symptoms and treatment of various medical diseases. *Swiss Med Wkly* (2004) 134: 543-551.
8. Flam E, Berry S, Coyle A, Dardik H and Raab L: Blood-flow augmentation of intermittent pneumatic compression systems used for the prevention of deep vein thrombosis prior to surgery. *Am J Surg* (1996) 171: 312-315.
9. Iwama H, Obara S and Ohmizo H: Changes in femoral vein blood flow velocity by intermittent pneumatic compression: calf compression device versus planter-calf sequential compression device. *J Anesth* (2004) 18: 232-233.
10. Fujimoto K, Sengoku K, Takahata O and Iwasaki H: Effects of positions on the foot pump (A-V impulse system) produced blood velocity in the common femoral vein. *Rinsho Masui (J Clin Anesth, Tokyo)* (2003) 27: 1465-1469 (in Japanese).
11. Kohro S, Yamakage M, Takahasi T, Kondo M, Ota K and Namiki A: Intermittent pneumatic compression prevents venous stasis in the lower extremities in the lithotomy position. *Can J Anesth* (2002) 49: 144-147.