

Case Report

Posterior Cervical Spine Arthrodesis with Laminar Screws: A Report of Two Cases

Kazuo Nakanishi*, Masato Tanaka,
Yoshihisa Sugimoto, and Toshifumi Ozaki

*Department of Orthopaedic Surgery, Okayama University Graduate School of Medicine,
Dentistry and Pharmaceutical Sciences, Okayama 700-8558, Japan*

We performed fixation using laminar screws in 2 patients in whom lateral mass screws, pedicle screws or transarticular screws could not be inserted. One was a 56-year-old woman who had anterior atlantoaxial subluxation (AAS). When a guide wire was inserted using an imaging guide, the hole bled massively. We thought the re-insertion of a guide wire or screw would thus increase the risk of vascular injury, so we used laminar screws. The other case was an 18-year-old man who had a hangman fracture. Preoperative magnetic resonance angiography showed occlusion of the left vertebral artery. A laminar screw was inserted into the patent side (*i.e.*, the right side of C2). Cervical pedicle screws are the most biomechanically stable screws. However, their use carries a high risk of neurovascular complications during screw insertion, because the cervical pedicle is small and is adjacent laterally to the vertebral artery, medially to the spinal cord, and vertically to the nerve roots. Lateral mass screws are also reported to involve a risk of neurovascular injuries. The laminar screw method was thus thought to be useful, since arterial injuries could thus be avoided and it could also be used as a salvage modality for the previous misinsertion.

Key words: laminar screw, neurovascular complications, lateral mass screw, pedicle screw, transarticular screw

Surgical fixation for instability of the upper cervical spine is performed by various techniques, such as the Brooks method [1] and the Gallie method [2]. However, fixation using a wire induces pseudoarthrosis with a high frequency [3, 4] and is prone to problems related to the stiffness of the fixation. Recently, in posterior fusion for instability of the cervical spine, fixation using a lateral mass [5, 6], a pedicle [7] or transarticular [8] screws has been

widely used. However, the position of the foramen transversarium of the cervical spine and the size of the pedicle of the vertebral arch vary between individuals, and some cases show either asymmetry or hypoplasia of the vertebral artery. Therefore, the insertion of these screws carries a high risk of injuring either the adjacent vertebral artery or spinal cord. Vertebral artery injuries can cause serious complications, such as brain infarction, in the regions of the cerebellum and posterior cerebral artery, as well as life-threatening brain stem infarction [9-11]. In 2004, Wright reported a new method to avoid such vertebral artery injuries, in which a

Received August 23, 2006; accepted December 4, 2006.

*Corresponding author. Phone: +81-86-235-7273; Fax: +81-86-223-9727
E-mail: kazu17@md.okayama-u.ac.jp (K. Nakanishi)

screw was inserted crosswise to the lamina of C2 [12]. We herein describe our method for performing fixation using laminar screws in 2 patients in whom lateral mass screws, pedicle screws or transarticular screws could not be inserted.

Case Report

Case 1. A 56-year-old woman had anterior atlantoaxial subluxation (AAS). She had been treated for rheumatoid arthritis for the past 25 years. However, she started to experience neck pain 2 years after that treatment had begun. Since the pain was worsening and the patient's range of neck motion

was limited (Ranawat II) in the past year, she was admitted for treatment. Atlantoaxial fixation was performed by the Magerl method. When a guide wire was inserted using an imaging guide, the hole bled massively. The hemorrhaging was controlled by plugging the hole with bone wax and compressing it. Since the re-insertion of the guide wire or a screw could have caused vascular injury, a laminar screw system was selected to carry out atlantoaxial fixation.

From the day after the operation, the patient was able to walk while wearing a soft neck brace (Fig.1). At 1 year after the operation, her neck pain was improved and rigid fixation had been achieved.

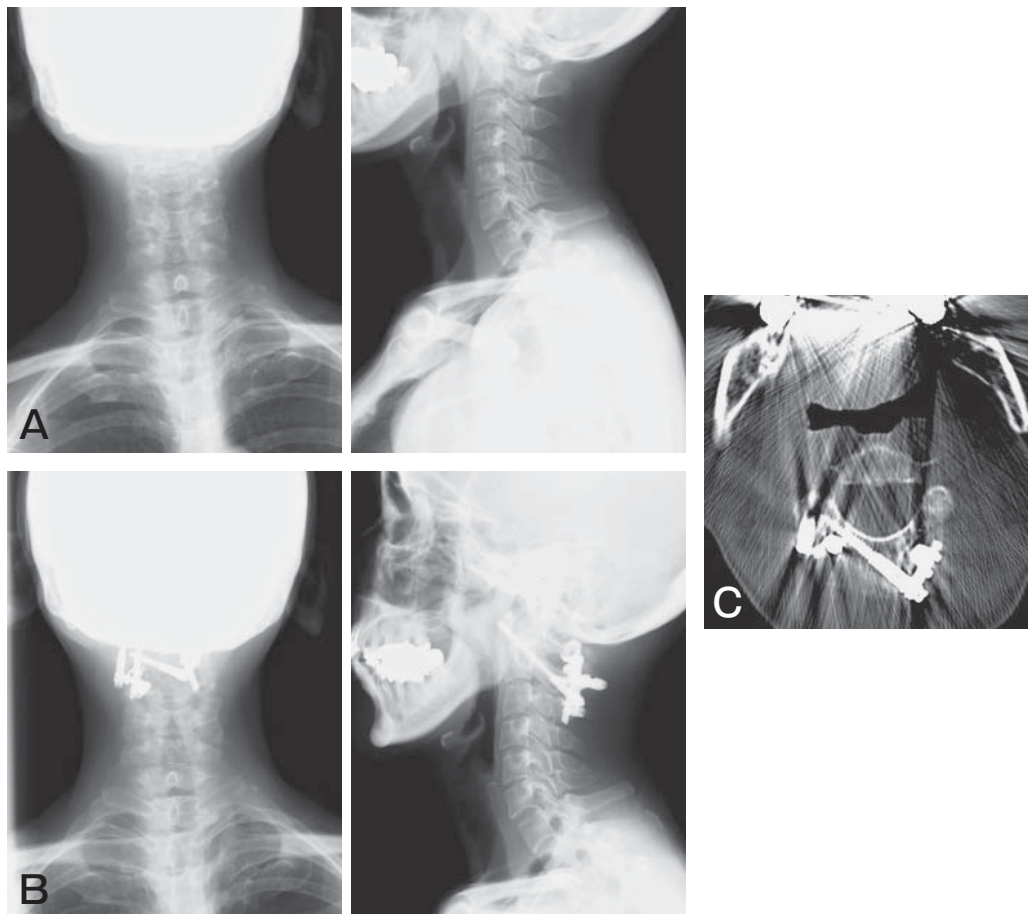


Fig. 1 Roentgenogram and CT. **A**, Preoperative roentgenogram: A 56-year-old woman with anterior atlantoaxial subluxation (AAS); **B**, Postoperative roentgenogram; **C**, Postoperative CT: During the atlantoaxial fixation by the Magerl method, massive bleeding was observed during insertion of a trans-articular screw, so we used laminar screws instead.

Case 2. An 18-year-old man presented with a hangman fracture. In August 2005, he was in the front passenger seat of a car that fell into a river 2 meters below the road. He was urgently transferred to a regional medical center. At the time of injury, paresthesia in the upper right inferior limb was observed, as were incomplete paralysis and numbness in the left superior limb. After 1 month of bed rest, he was able to walk while wearing a brace. Approximately 2 months after injury, he was discharged. However, instability between C2 and C3 thereafter increased, and he was thus introduced to

our hospital. Radioscopy showed an anterior slip of C2, and magnetic resonance angiography (MRA) showed occlusion of the left vertebral artery (Fig. 2). Four months after the injury, posterior fusion for C2-3 was performed. A laminar screw was thus inserted into the patent side (*i.e.*, the right side of C2), and a pars screw into the occluded side (*i.e.*, the left side of C2). Lateral mass screws were then inserted into both sides of C3 (Fig. 3).

From the day after the operation, the patient could walk while wearing a soft neck brace. At 9 months after the operation, no instability of the cer-

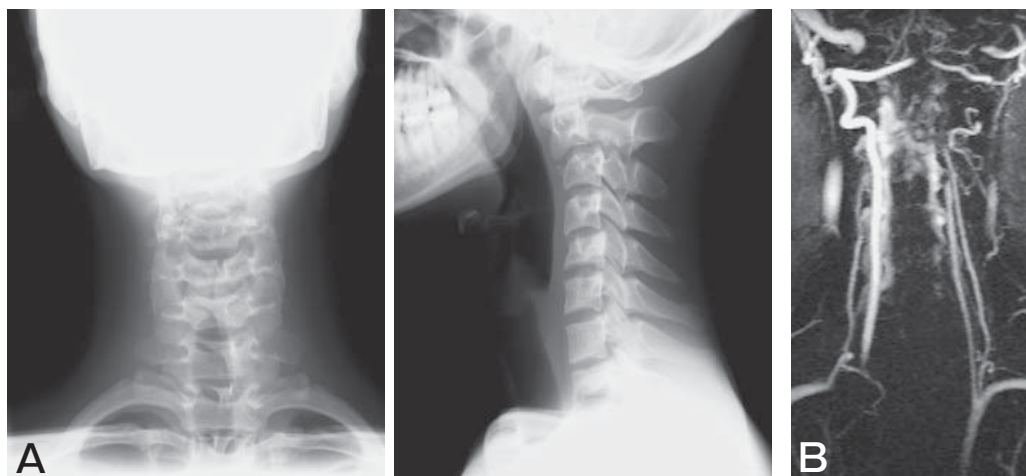


Fig. 2 Preoperative roentgenogram and magnetic resonance angiography. **A**, Roentgenogram shows anterior slip of C2; **B**, Magnetic resonance angiography shows occlusion of the left vertebral artery.

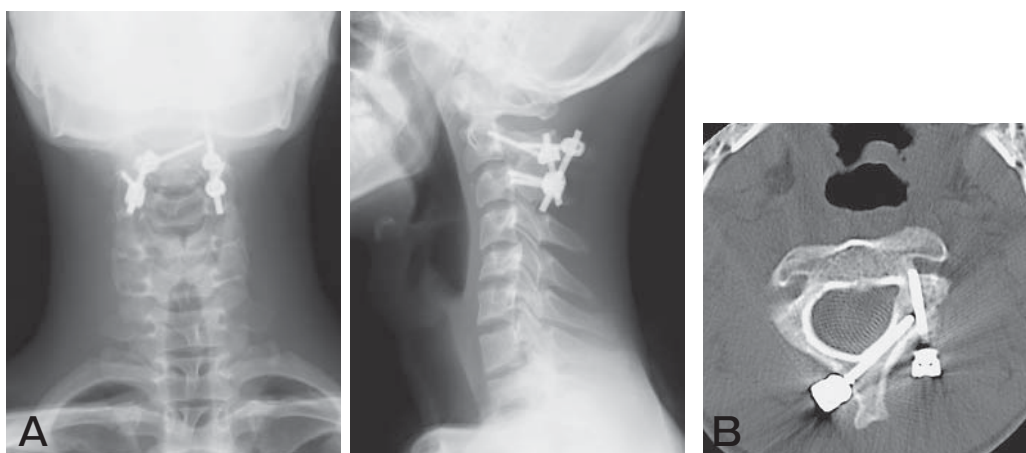


Fig. 3 Postoperative roentgenogram and CT. **A**, Postoperative roentgenogram: A laminar screw was inserted into the patent side (*i.e.*, the right side of C2), and a pars screw was inserted into the occluded side (*i.e.*, the left side of C2). Lateral mass screws were inserted into both sides of C3; **B**, Postoperative CT shows insertion of a laminar screw.

vical spine was observed and rigid fixation had been achieved.

Discussion

Since Abumi *et al.* clinically applied cervical pedicle screws in 1994 [7], such screws have been broadly used for the unstable cervical spine and spinal deformity in place of posterior wiring, which has been reported to induce pseudoarthrosis and non-union with a high frequency (approximately 18%) [3, 4]. Cervical pedicle screws are the most biomechanically stable screws [13]. However, their use carries a high risk of neurovascular complications accompanied by screw insertion, because the cervical pedicle is small and is laterally adjacent to the vertebral artery, medially adjacent to the spinal cord, and vertically adjacent to the nerve roots [14]. In cadaveric studies, an anomaly that prevents screw insertion is observed in approximately 20% of cases [15]. Furthermore, pedicle screws are reported to induce injuries to the vertebral artery with a probability of approximately 4% in a clinical setting [16]. Lateral mass screws are also reported to pose a risk for neurovascular injuries [17, 18].

There are 2 ways to induce vertebral artery injury. In some cases, the vertebral artery is directly injured and hemorrhaging can thus occur during the operation, or the blood flow can be blocked due to compression by screws. In other cases, an embolism of the basilar artery due to thrombus occurs subsequent to injury of the intima of the vessel after operation. Many of the latter cases tend to show a late onset. Therefore, to avoid injury to the vertebral artery pedicle screws basically should not be used for the following cases: a small pedicle of the vertebral arch to which even a screw 3.5 mm in diameter cannot be inserted, cases with remarkably severe osteosclerosis of the pedicle of vertebral arch that has no medullary space, the dominant side of the asymmetric vertebral arteries, the opposite side of unilateral vertebral artery occlusion, or patients with a seriously high-riding vertebral artery [14].

For lesions of the unstable cervical spine, the use of screws makes it possible to perform robust internal fixation, and postoperative external fixation can thus be simplified. However, the potential risk for

neurovascular injuries upon screw insertion is high. Furthermore, the stiffness of the fixation is reduced if a screw cannot be inserted into the proper position in a single procedure. The screws can be inserted safely by the use of a recent navigation system, but such systems are not always available at all facilities. There are more than a few cases whose vertebral arteries are asymmetric, or whose unilateral vertebral artery is occluded. In such cases, screw insertion still poses a high risk of vascular injury even when a navigation system is used. When the vertebral artery is injured and hemorrhage occurs due to a misinsertion of a screw during operation, such hemorrhaging can be controlled by plugging the screw hole with bone wax and then compressing it. However, the re-insertion of such a screw is difficult.

In 2004, Wright reported a laminar screw method in which 2 screws are inserted crosswise into the lamina of the axis, avoiding vertebral artery injuries and safely performing fixation between the axis and cervical spines [12]. Besides avoiding such injuries, this method has another advantage: a navigation system is not necessary, since the screws can be inserted under direct vision of the lamina. On the other hand, one disadvantage of this method is that injuries to the spinal canal located in the ventral area cannot be easily observed. Wright predicted that the diameter of the axis lamina is greatest in the cervical spine, and he thus suggested this laminar screw method can be applied to most patients who require axis fixation.

In addition, Lapsiwala *et al.* in 2006 reported on the stiffness of a laminar screw [19]. When they fixed C1 and C2 using either a pedicle screw, transarticular screw or laminar screw (wire fixation is combined with each screw), the transarticular screws demonstrated the most favorable fixation. They reported that a laminar screw has almost the same strength of fixation as a pedicle screw with both forward and backward flexion, but less strength with rotation. We also recently studied differences in the strength of fixation among the screws while focusing on the diameter of the lamina of the cervical spine; we found the laminar diameter to differ greatly among individuals (*e.g.*, 2.9 and 7.0 mm).

We therefore preoperatively measured the laminar diameter and evaluated the vertebral arteries by CT and MRA.

To avoid vascular injuries, we used laminar screws, rather than pedicle or lateral mass screws, on the dominant side of the asymmetric vertebral arteries and the opposite side of the unilaterally occluded vertebral artery. Furthermore, when it was highly possible that such cases might suffer vertebral artery injury due to an intra-operative misinsertion, we did not insert the screws again into the pedicle of the vertebral arch or lateral mass, but instead used laminar screws.

Wright performed a 6-week external fixation, while we used fixation for only for 2 weeks and still obtained good bone union. Few investigators have compared the stabilizing ability of laminar screw with those of other types of screws [19]. However, we still need to investigate the influence of laminar diameter on the stabilizing ability in further studies. Nevertheless, the laminar screw method was found to be useful for avoiding arterial injuries, and this method could thus be used as a salvage treatment modality after a misinsertion. We should further closely investigate both the indications and limitations of laminar screws when treating such cases.

References

- Brooks AL and Jenkins EB: Atlanto-axial arthrodesis by the wedge compression method. *J Bone Joint Surg* (1978) 60: 279-284.
- Dickman CA, Sonntag VK, Papadopoulos SM and Hadley MN: The interspinous method of posterior atlantoaxial arthrodesis. *J Neurosurg* (1991) 74: 190-198.
- Coyne TJ, Fehlings MG, Wallace MC, Bernstein M and Tator CH: C1-C2 posterior cervical fusion: long-term evaluation of results and efficacy. *Neurosurgery* (1995) 37: 688-693.
- Reilly TM, Sasso RC and Hall PV: Atlantoaxial stabilization: clinical comparison of posterior cervical wiring technique with transarticular screw fixation. *J Spinal Disord Tech* (2003) 16: 248-253.
- Taniguchi M and Maruo S: Posterior Lower Cervical Spine Arthrodesis with Lateral Mass Fixatio. *Spine & Spinal Cord* (1998) 11: 217-224.
- Tokuhashi Y: Posterior Lateral Mass Plate Fixation of the Cervical Spine. *Spine & Spinal Cord* (2001) 14: 934-944.
- Abumi K, Itoh H, Taneichi H and Kaneda K: Transpedicular screw fixation for traumatic lesions of the middle and lower cervical spine: description of the techniques and preliminary report. *J Spinal Disord* (1994) 7: 19-28.
- Jeanneret B and Magerl F: Primary posterior fusion C1/2 in odontoid fractures: indications, technique, and results of transarticular screw fixation. *J Spinal Disord* (1992) 5: 464-475.
- Becker KJ, Monsein LH, Uiatowski J, Mirski M, Williams M and Hanley DF: Intraarterial thrombolysis in vertebrobasilar occlusion. *AJNR* (1996) 17: 255-262.
- Louw JA, Mafoyané NA, Small B and Nesar CP: Occlusion of the vertebral artery in cervical spine dislocation. *J Bone Joint Surg* (1990) 72: 679-681.
- Vaccaro AR, Klein GR, Flanders AE, Albert TJ, Balderston RA and Cotler JM: Longterm evaluation of vertebral artery injuries following cervical spine trauma using magnetic resonance angiography. *Spine* (1998) 23: 789-794.
- Wright NM: Posterior C2 Fixation Using Bilateral, crossing C2 laminar screws: case series and technical note. *J Spinal Disord Tech* (2004) 17: 158-162.
- Kotani Y, McNulty PS, Abumi K, Cunningham BW, Kaneda K and McAfee PC: The role of anteromedial foraminotomy and the uncovertebral joints in the stability of the cervical spine. *Spine* (1998) 23: 1559-1565.
- Taneichi H: Placement Technique of Cervical Screws and Prevention of its Complications. *Spine & Spinal Cord* (2005) 18: 1043-1052.
- Madawi AA, Casey AT, Solanki GA, Tuite G, Veres R and Crockard HA: Radiological and anatomical evaluation of the atlantoaxial transarticular screw fixation technique. *J Neurosurg* (1997) 86: 961-968.
- Wright NM and Lauryssen C: Vertebral artery injury in C1-2 transarticular screw fixation: results of a survey of the AANS/CNS section on disorders of the spine and peripheral nerves. American Association of Neurological Surgeons/Congress of Neurological Surgeons. *J Neurosurg* (1998) 88: 634-640.
- Graham AW, Swank ML, Kinard RE, Lowery GL and Dials BE: Posterior cervical arthrodesis and stabilization with a lateral mass plate: clinical and computed tomographic evaluation of lateral mass screw placement and associated complications. *Spine* (1996) 21: 323-329.
- Deen HG, Birch BD, Wharen EH and Reimer R: Lateral mass screw-rod fixation of the cervical spine: a prospective clinical series with 1-year follow-up. *Spine J* (2003) 3: 489-495.
- Lapsiwala SB, Anderson PA, Oza A and Resnick DK: Biomechanical comparison of four C1 to C2 rigid fixative techniques: anterior transarticular, posterior transarticular, C1 to C2 pedicle, and C1 to C2 intralaminar screws. *Neurosurgery* (2006) 58: 516-521.