

Case Report

Successful Thoracoscopic Lobectomy for Lung Cancer in a Patient with Anatomic Variation of the Left Inferior Pulmonary Vein

Kanji Minamoto*, Takahiko Misao, Seiki Takashima, and Hideharu Nakano

Department of Surgery, Kagawa Prefectural Central Hospital, Takamatsu, Kagawa 760-8557, Japan

We present a case of primary lung cancer with a rare distribution pattern of left inferior pulmonary vein (PV), encountered in the thoracoscopic left lower lobectomy. Thoracoscopic observation revealed 2 trunks of inferior PV (ventral and dorsal branch) at the stem level. The ventral trunk consisted of a branch of vein (V⁵) from the lingular segment and venous ramifications (V^{8a}, V⁹ and V^{10a}) from the basal segment. On the other hand, a branch of vein (V⁶) from the superior segment in the lower lobe and other veins (V^{8b} and V^{10b} + c) from the basal segment emptied together into the dorsal trunk. We successfully carried out a thoracoscopic left lower lobectomy without excision of the aberrant vein (V⁵). Retrospective review of the preoperative chest CT demonstrates the double trunk inferior PV and the aberrant lingular branch emptying with V^{8a} into the ventral trunk. Knowledge of the branching variations of PV from preoperative evaluations leads to appropriate thoracoscopic procedures for lung cancer.

Key words: anatomic variation, aberrant branch, pulmonary vein, lung cancer, and video-assisted thoracoscopic surgery (VATS)

Video-assisted thoracoscopic surgery (VATS) has become a preferred and representative approach to treating lung cancer. As the reliability of VATS procedures, based on the proficiency of the surgical techniques, determines the result of the therapeutic efficacy, physicians must obtain deep insight into the anatomic variations of pulmonary venous ramification.

Case Report

A 74-year old male who underwent endoscopic

mucosal resection of esophageal tumor in a diagnosis of early esophageal cancer was indicated to have an abnormal shadow in the left lower lung field on chest X-ray film. The thoracic computer-assisted tomogram (CT) revealed a small nodule in the area S¹⁰ of the left lower lobe (Fig. 1A). The patient was diagnosed with CT guided lung biopsy as a primary adenocarcinoma, and surgery was recommended as radical treatment. The left lower lobectomy was performed under VATS. The anatomic variation of inferior pulmonary vein (PV) was encountered on disclosure of the left hilum through the posterior aspect. The inferior PV was bifurcated into front (ventral) and rear (dorsal) trunks on the stem level. First of all, the tops of the segmental branches of the inferior PV were carefully separated and dis-

Received June 20, 2006; accepted October 26, 2006.

*Corresponding author. Phone: +81-863-31-2101; Fax: +81-863-32-4278
E-mail: km382jp@yahoo.co.jp (K. Minamoto)

Table 1 Abbreviations used in this paper

PV	pulmonary vein	V ^{8b}	basal ramification of ventrobasal inferior PV
VATS	video-assisted thoracoscopic surgery	V ⁹	laterobasal inferior PV
V ⁴	superior lingular PV	V ^{10a}	dorsal ramification of dorsobasal inferior PV
V ⁵	inferior lingular PV	V ^{10b}	lateral ramification of dorsobasal inferior PV
V ⁶	superior ramification of inferior PV	V ^{10c}	medial ramification of dorsobasal inferior PV
V ^{8a}	lateral ramification of ventrobasal inferior PV	S ¹⁰	dorsobasal segment

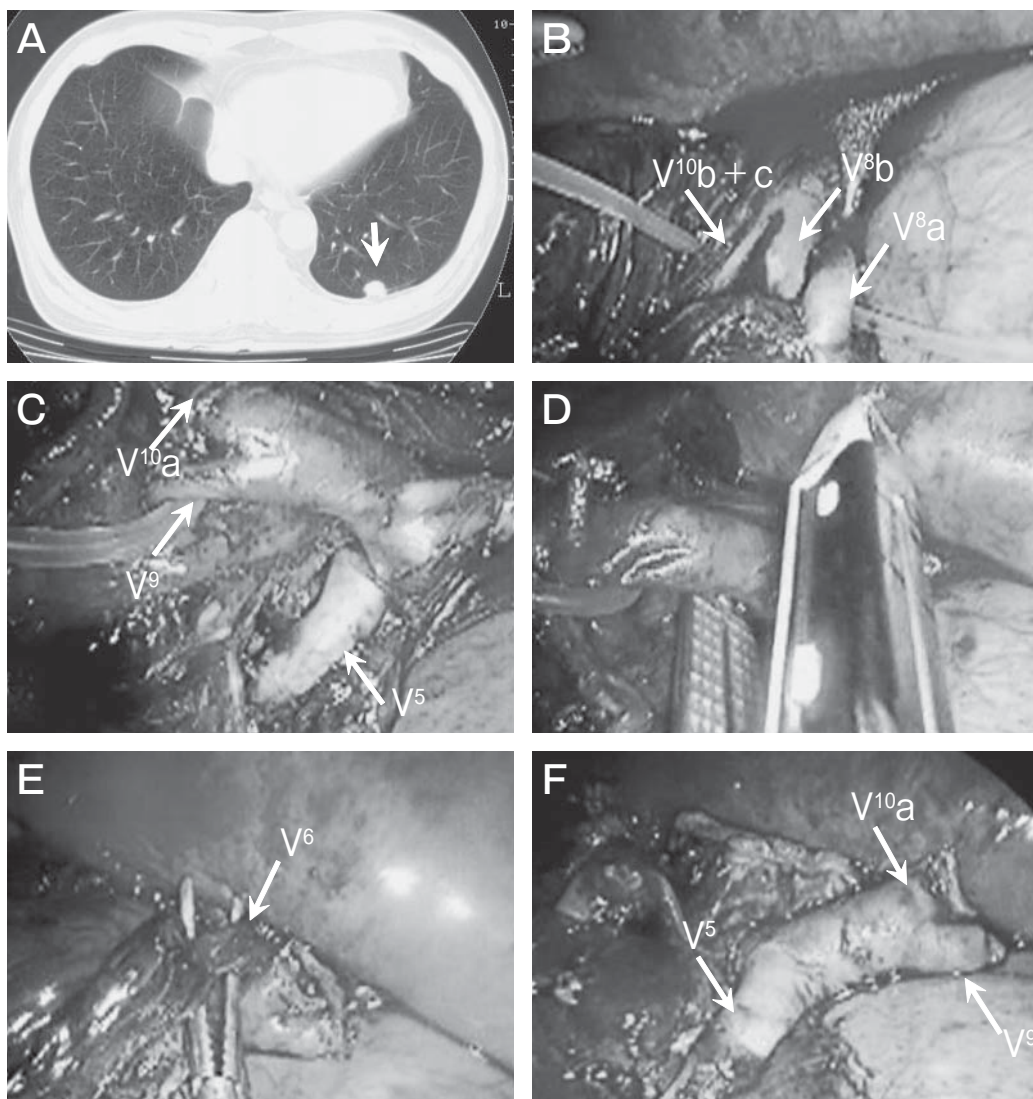


Fig. 1 A, Preoperative chest CT shows tumor localization (arrow) in area S¹⁰ of the left lower lobe; B, The branches of left V^{8b} and V^{10b} + c emptying into the dorsal trunk and the additional branch of V^{8a} into the ventral trunk were divided; C, An aberrant ramification from the lingular segment is observed emptying into the proximal ventral trunk, in which V⁹ and V^{10a} empty at the distal level; D, The branch of V⁹ + V^{10a} was divided; E, V⁶ empties into the stem of the dorsal trunk, which was divided; F, The aberrant lingular branch (V⁵) is preserved in the left lower lobectomy. For abbreviations, see Table 1.

closed. Those branches of V^{10b+c} and V^{8b} emptying into the dorsal trunk and the additional branch of V^{8a} emptying into the ventral trunk were divided with a suturing instrument (Fig. 1B). This procedure exposed the distal branch of the ventral trunk, into

which V^9 and V^{10a} empty, and an aberrant ramification (V^5) from the lingular segment draining into the proximal ventral trunk (Fig. 1C). The branch of $V^9 + V^{10a}$ was then divided at the distal to the branch of the aberrant vein (V^5 , Fig. 1D). Thereafter, an additional vein (V^6) from the superior segment in the lower lobe draining into the dorsal trunk was detected, which was also divided (Fig. 1E). Finally, the thoracoscopic left lower lobectomy and mediastinal lymph node dissection were performed, completely preserving the aberrant ramification from the lingular segment (Fig. 1F). The distribution pattern of the PV was identified according to the anatomical terminology observed in the resected specimen (Fig. 2A, 2B, and 2C). Retrospective review of the preoperative chest CT shows the double (ventral and dorsal) trunk of the inferior PV and the aberrant ramification from the lingular segment emptying with V^{8a} into the ventral trunk (Fig. 3). The patient was discharged on day 14 following the surgery without any postoperative complications.

Discussion

Endoscopic rather than macroscopic procedures have become an indispensable approach to performing thoracic surgery. The proficiency of the thoracoscopic treatment facilitates local observation in the field and detection of significant variations of pulmo-

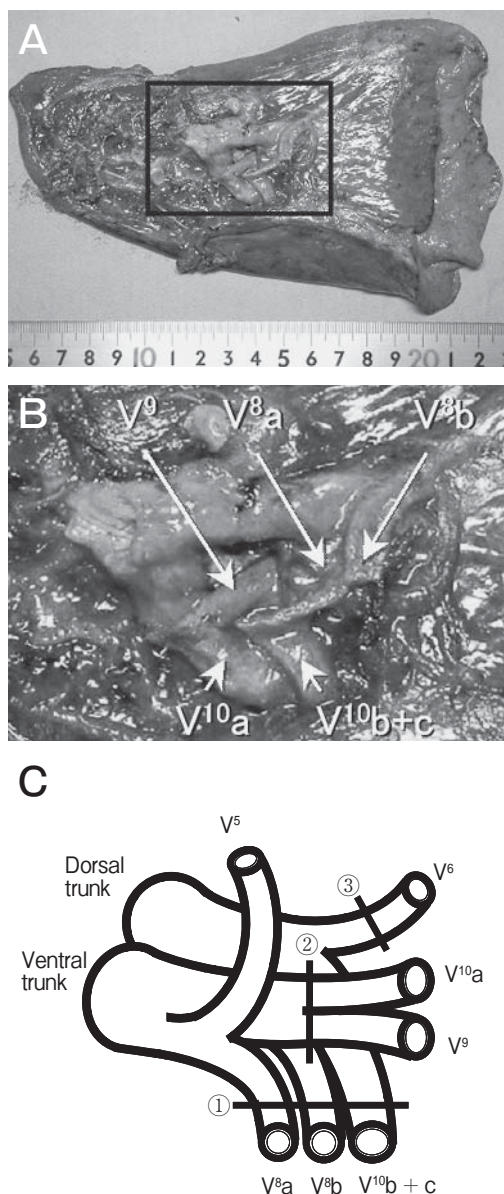


Fig. 2 A, The distribution pattern of the PV is identified in the resected specimen; B, The naming of the veins according to the anatomical terminology; C, The presence of an anatomic branching variation of the inferior PV in the current case. The branches of the PV were divided in the order shown as a circled number.

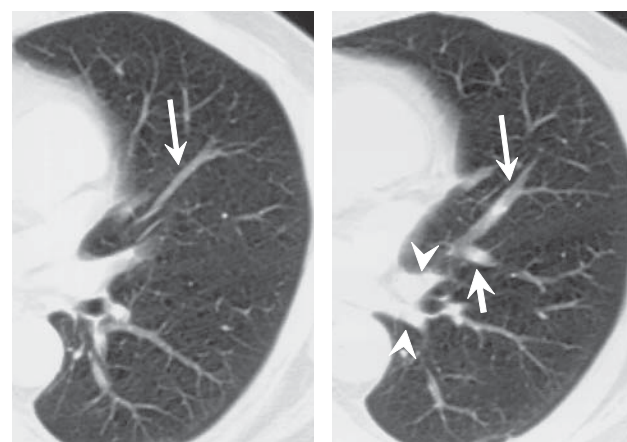


Fig. 3 Retrospective review of the preoperative chest CT shows that the lingular vein (long arrow) merging with V^{8a} (short arrow) empties into the ventral trunk of the inferior PV. Two stems of the inferior PV are detectable in the CT (arrowheads).

nary vessels in the resection of lung cancer. In addition to skill in carrying out the procedure, comprehension of the possible branching variations of the pulmonary vessels leads to successful prediction of aberrant anatomy. In this case, endoscopic observation revealed double trunk inferior PV with an aberrant lingular branch, and thoracoscopic lower lobectomy was successfully performed without excision of the aberrant vein (V^5) from the lingular segment. Dividing both trunks of the PV without identifying the possible anatomic variations may cause segmental dysfunction of the upper lobe as a postoperative complication.

The distribution pattern of the lingular venous branch in the left upper lobe appears to be more complex than the branch in the right middle lobe. The venous branch from the lingular segment empties into the superior PV in most cases. In reported cases, V^{4+5} enters the left inferior PV as a single stem at a frequency of 2.5%. Either branch of V^4 or V^5 enters the superior or inferior PV as 2 stems at a frequency of 8.2% [1]. Anatomic venous variation

in the right middle lobe draining to the right inferior PV has been described [2] to occur at a frequency of 4.8% [1]. The frequency of these variations is quite notable on the pulmonary surgery.

In the current case, anatomic variation of the inferior PV was confirmed with the retrospective review of the preoperative chest CT. It clearly demonstrates double trunk inferior PV and the lingular ramification emptying with V^8a into the ventral trunk (Fig. 3). In order to perform reliable procedures under VATS, it is necessary for thoracic surgeons not only to visualize the exact features of the pulmonary vessels from the preoperative evaluations, but also to be aware of the considerable branching variations.

References

1. Yamashita H: Roentgenologic anatomy of the lung. Igaku-Shoin, Tokyo (1978) pp 70-107.
2. Sugimoto S, Izumiyama O, Yamashita A, Baba M and Hasegawa T: Anatomy of inferior pulmonary vein should be clarified in lower lobectomy. *Ann Thorac Surg* (1998) 66: 1799-1800.