

Original Article

Assessment of Molecular Cytogenetic Methods for the Detection of Chromosomal Abnormalities

Tomoka Une*, Yuji Yokoyama, Shinsuke Ninomiya, Masako Shinozuka, Hidehiko Maruyama, and Tsuneo Morishima

Department of Pediatrics, Okayama Graduate School of Medicine,
Dentistry and Pharmaceutical Sciences, Okayama 700-8558, Japan

Some marker chromosomes and chromosome rearrangements are difficult to identify using G-bands by Giemsa staining after trypsin treatment (G-banding) alone. Molecular cytogenetic techniques, such as spectral karyotyping (SKY) and fluorescence *in situ* hybridization (FISH), can help to detect chromosomal aberrations precisely. We analyzed the karyotypes in 6 cases of multiple congenital abnormalities and 1 case of spontaneous abortion (case 2). Three cases (cases 1, 6, and 7) had marker chromosomes, and 4 cases (cases 2-5) had chromosomal rearrangements. The karyotypes in cases 1, 2, and 3 were determined using FISH with probes based on the clinical findings and family histories. Spectral karyotyping (SKY) analysis in cases 4-7 showed that this method is useful and saves time. The combination of SKY and FISH analyses defined the range of the ring chromosome in case 7. We demonstrated that a combination of G-banding, FISH, and SKY can be applied effectively to the investigation of chromosomal rearrangement and to the detection of marker chromosome origins. We suggest the use of these methods for prenatal diagnosis, in which the inherent time limitations are particularly important.

Key words: spectral karyotyping, fluorescence *in situ* hybridization, molecular cytogenetics, marker chromosome, chromosome rearrangement

Some *de novo* marker chromosomes, which are also known as extra structurally abnormal chromosomes (ESACs), and chromosome rearrangements, such as small insertions, are often associated with neonatal malformations and mental retardation. Therefore, the identification of these aberrations is very important. ESACs occur in 1 out of 400 mentally retarded patients, 1 out of 4000 live-born individuals, and 1 out of 1000 cases at amniocentesis [1-3]; 40% of these cases are familial [4].

Chromosome structure rearrangements are detected in up to 0.1% of prenatal cytogenetic investigations. In a large multicenter study [5], abnormal phenotypic outcomes were seen in 13% of the *de novo* marker chromosomes. When small marker chromosomes or chromosome structure rearrangements are detected, the precise identification of the origins of these chromosomes or chromosomal portions is important.

Caspersson and Zech introduced chromosome banding in 1969 [6, 7], and karyotype analysis by G-banding has been the standard method for identifying numerical and structural chromosomal aberrations [4, 8]. However, chromosome-banding pat-

terns are difficult to interpret. In the case of subtle chromosomal rearrangements, *de novo* marker chromosomes confound comprehensive karyotype analysis. Molecular cytogenetic techniques such as FISH have revolutionized the clinical identification of chromosomal abnormalities [9, 10]. In FISH, a DNA probe labeled with a fluorescent substance hybridizes to the target DNA on the chromosome. FISH analysis was first used in gene mapping. Gradually, FISH analysis using a specific probe has come to be used to detect small regions that contain specific genes, such as those in Prader-Willi syndrome and Williams syndrome. In addition, α -satellite markers, including D13Z1, D18Z1, and D21Z1, are useful for the detection of supernumerary chromosomes [11–14]. The choice of probes is usually made according to the G-banding patterns. The rapid identification of the origins of complex markers can be accomplished with whole-genome chromosome painting techniques, such as SKY [15]. SKY permits the visualization of all human chromosomes in 24 different colors using painting probes labeled with different combinations of 5 fluorochromes [9, 16, 17]. SKY can be used as a screening tool to identify structural abnormalities and marker chromosomes [18, 19].

In this study, 7 cases were analyzed. All of the samples were screened initially by G-banding, followed by SKY analysis (N = 3), FISH analysis (N = 3), or the combination of FISH and SKY analyses (N = 1).

Materials and Methods

G-banding. G-banding was performed on peripheral blood lymphocytes cultured from both patients and parents. In case 2, fibroblasts from amniotic fluid cells and chorionic villous samples were also analyzed. Cells in metaphase or prometaphase were collected by adding colcemid to a final concentration of 0.05 $\mu\text{g}/\text{ml}$. Two hours before harvesting, the peripheral blood cells were treated with ethidium bromide at a final concentration of 10 $\mu\text{g}/\text{ml}$ [20]. Hypotonic treatment was performed in 0.075 M KCl for 15 min at room temperature, and the cells were fixed in methanol:acetic acid (3:1). The slides were held at an angle of 60–80° down from the horizontal position, and one drop of suspension was allowed to run quickly down the slide. The

slides were allowed to dry completely in the slanted position for 24 h. Each slide was rinsed with water and treated with 0.01% trypsin, and then stained with 3% Giemsa for 5 min.

SKY analysis. SKY analysis was performed on cultured peripheral blood lymphocytes by SRL, Tokyo, Japan. The chromosome-specific probes were conjugated to a specific combination of 5 different fluorophores: Cy2, Spectrum green, Cy3, Texas Red, and Cy5.

FISH analysis. FISH was performed in cases 1, 2, 3, and 7. In case 7, FISH was performed with the BAC923C6 probe, which maps to 1p12, and the RR6 probe, which maps to 1q12 heterochromatin. These 2 probes were kind gifts of Dr. D. F. Callen [21]. The remaining FISH analyses were performed by SRL, and FISH analyses were performed using the following probes: WCP3 and WCP22, paint probe, and LIS1 (maps to 17p13.3), and D14Z1/D22Z1 probes [22, 23]. The slides were denatured in 70% formamide/2 \times SSC (20 \times SSC = 3.0 M NaCl, 0.3 M Sodium citrate) at 70 °C for 2 min, followed by dehydration in ethanol. Ten microliters (0.5 ng/ μl) of the probe were applied to the slide, which was then coverslipped and sealed. Following incubation at 37 °C for 16 h, the slide was washed 3 times in 50% formamide/2 \times SSC at 45 °C for 10 min, once in 2 \times SSC for 10 min at 45 °C, once in 2 \times SSC/0.1% NP-40 for 5 min at 45 °C, and once in 2 \times SSC for 10 min at room temperature. The slides were counterstained with DAPI (4', 6'-diamidino-2-phenylindole dihydrochloride) [10, 24].

Results

Case 1. The proband was from an 8-month-old girl. She was born at 38 weeks of gestation as the first child of a 38-year-old mother and an unrelated 45-year-old father. Her birth weight was 2,510 g. Immediately after birth, the girl was identified as having anal atresia and total anomalous pulmonary venous connection, and she underwent surgery. After the operation, the subject was referred to us for evaluation of multiple congenital malformations. Physical examination showed brachycephaly, low nasal bridge, hypertelorism, downward-slanted palpebral fissure, microtia, preauricular fistula, small hands and feet, long fingers, and developmental

delay. There was no evidence of coloboma of the iris or renal malformation.

The subject had a supernumerary marker chromosome (Fig. 1A-a). The karyotypes of the parents were normal. With regard to the detection of the marker chromosome by G-banding, the D or G group was suspected. The clinical findings suggested cat eye syndrome. The FISH method was performed to detect the chromosomal origin, and the signal was detected using 14/22 α -satellite probes and the chromosome 22 probe (Figs. 1A-b, c). The karyotype was diagnosed as 47, XX, +mar. ish idic (22)(q11.2) (D14Z1/D22Z1).

Case 2. The proband was from a couple consisting of a 30-year-old woman and a 29-year-old man. They did not have any malformations. Previously, the female had had 3 spontaneous abortions and 1 artificial abortion.

G-banding analysis of the chorionic villous sample was submitted at the time of the third natural miscarriage, and it was suspected of being 47, XX, +add (6)(p21.3). The possibility existed that the husband or the wife had a reciprocal translocation, and chromosome analysis was performed. The husband was 46, XY, t(6; 17)(p24; p13). After consultation for prenatal diagnosis, amniocentesis was performed at week 16 of the fifth pregnancy. The rearranged segments were too small for precise karyotyping of the amniotic fluid cells by the G-banding method alone. Therefore, we also performed FISH. The combination of G-banding and FISH revealed the same reciprocal translocation as observed in the father (Figs. 1B-a, b).

Case 3. The proband was from a 5-month-old girl. She was born at 38 weeks of gestation as the first child of a 30-year-old mother and an unrelated 30-year-old father. Her birth weight was 2,264 g. The subject was referred to us for evaluation of multiple congenital malformations. Physical examination showed brachycephaly, bushy eyebrows, hypertelorism, inverted epicanthus, anteverted nostril, depressed nasal bridge, down-turned corners of the mouth, long philtrum, and mild developmental delay. The subject did not exhibit heart malformations or internal organ abnormalities.

G-banding showed an additional small region on chromosome 3q (Fig. 1C-a), the origin of which was not defined. The karyotype of each parent was nor-

mal. FISH using the whole chromosome 3 probe showed that the additional small region was derived from chromosome 3 (Fig. 1C-b). The karyotype was designated as 46, XX, dup(3)(q24q26.2).

Case 4. The proband was from a girl aged 1 year and 7 months. She was born at 38 weeks of gestation as the first child of a 31-year-old mother and an unrelated 34-year-old father. Her birth weight was 2,892 g. She was referred to us for evaluation of multiple congenital malformations. Physical examination showed a prominent forehead, hypertelorism, epicanthus, low nasal bridge, large mouth with widely spaced teeth, clinodactyly of the fingers, and developmental delay. In addition, the subject was epileptogenic. There was no heart malformation or internal abnormality. Computed tomography of the brain revealed no abnormalities.

G-banding analysis showed an additional segment on 8p (Fig. 1D-a). The karyotype of each parent was normal. Using the SKY method, the additional portion of 8p was identified as being from chromosome 8 (Fig. 1D-b). The karyotype was designated as 46, XX, dup(8)(p23p12).

Case 5. The proband was from a girl aged 1 year and 4 months, who was born at 40 weeks of gestation. Her birth weight was 3,949 g. The subject was referred to us for evaluation of multiple congenital malformations. Physical examination showed flat occiput, coarse hair, round face, up-slanted palpebral fissure, hypertelorism, prominent anteverted nose, low-set ear, simian crease, webbed neck, thorax deformity, cubitus valgus, hypotonia, delayed dental eruption, and developmental delay. The echocardiogram showed a ventricular septal defect. Computed tomography of the brain revealed agenesis of the corpus callosum.

G-banding analysis revealed an additional fragment of unknown origin on the short arm of chromosome 20 (Fig. 1E-a). The karyotype of each parent was normal. Since SKY showed the extra material to be from chromosome 20 (Fig. 1E-b), the karyotype of this patient was identified as 46, XX, dup(20)(p11.2p13).

Case 6. The proband was from a 26-year-old woman. She was born at term as the first child of a 27-year-old mother and an unrelated 29-year-old father. After the birth, physical examination showed cleft palate, atrial septal defect, congenital disloca-

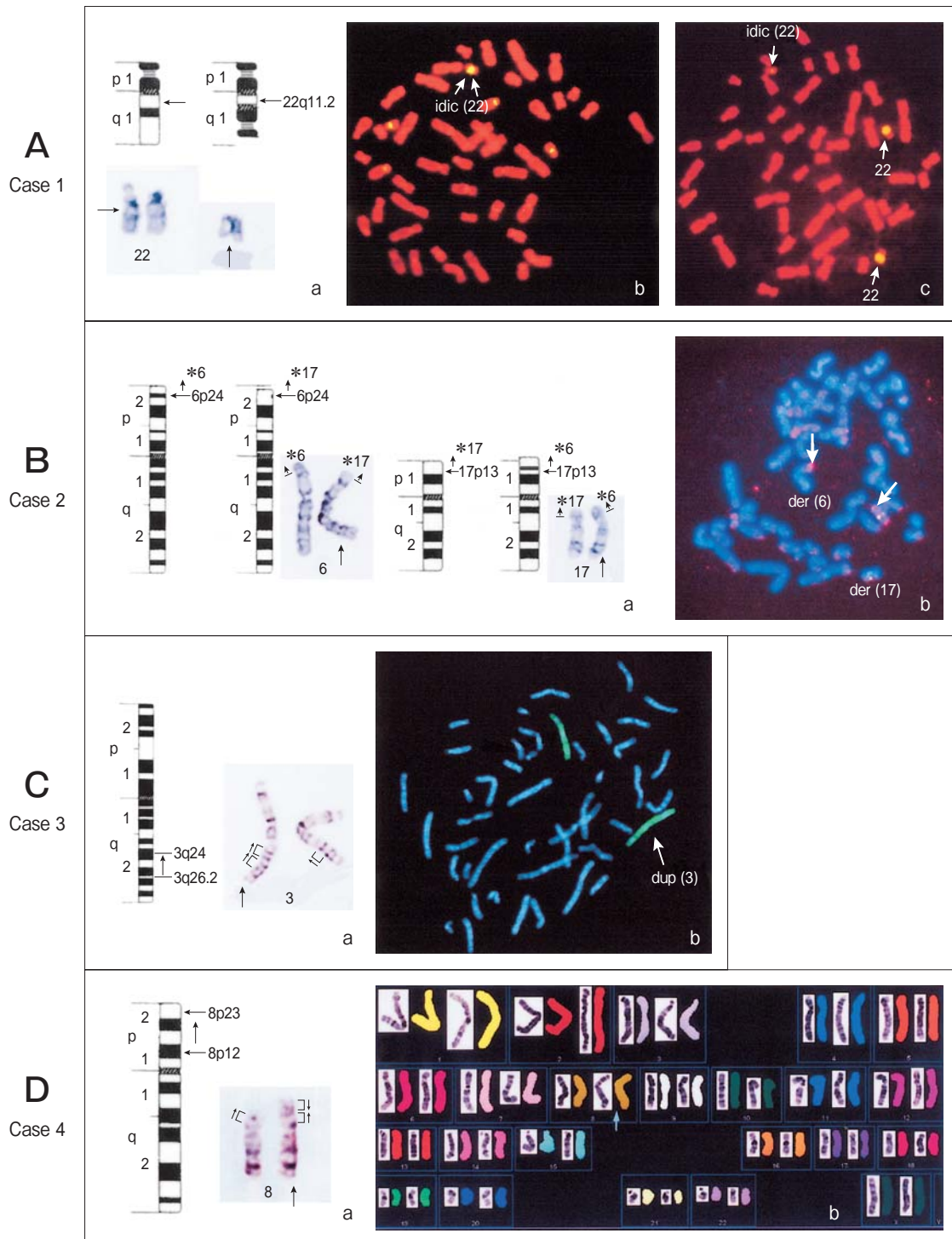


Fig. 1 Legend on the opposite page.

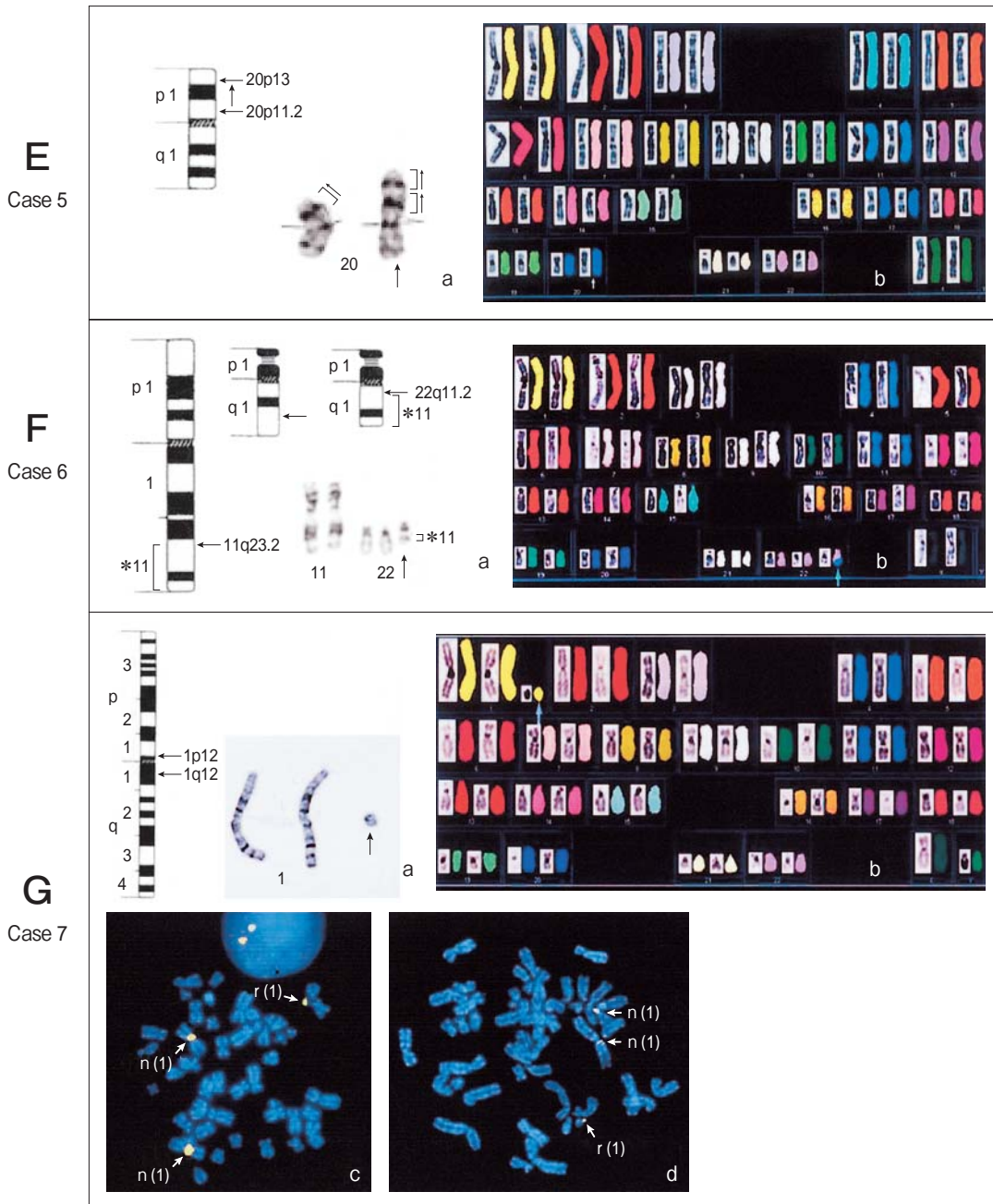


Fig. 1 A-a, Partial G-banded karyotypes in case 1; A-b, FISH using 14/22 α -satellite probes shows 2 positive signals on the marker chromosome (arrow); A-c, FISH using 22 whole-chromosome painting probes shows positive signals on the marker chromosome (arrow); B-a, Partial G-banded karyotypes in case 2; B-b, FISH using LIS1 (17p13.3 probe) shows a positive signal (arrow); C-a, Partial G-banded karyotypes in case 3; the abnormal chromosome 3 (arrow) is longer than the normal chromosome 3; C-b, Chromosome 3 painting probe stains both chromosomes in a homogeneous fashion (arrows); D-a, Partial G-banded karyotypes in case 4. The abnormal chromosome 8 (arrow) is longer than the normal chromosome 8; D-b, In the SKY analysis, the abnormal chromosome 8 (arrows) shows consistent hybridization along its entire length; E-a, Karyotyping in case 5 showing abnormal chromosome 20; E-b, In the SKY analysis, the abnormal chromosome 20 (arrows) shows consistent hybridization along its entire length; F-a, Partial G-banded karyotypes in case 6; F-b, SKY analysis showing abnormal chromosome 22 (arrows); G-a, Partial G-banded karyotypes in case 7; G-b, SKY analysis showing abnormal chromosome 1 (arrows); G-c, d, Representative FISH experiments. Fluorescent signals are detected for probes BAC923C6 (1p12) (C) and RR6 (1q12 heterochromatin) (D).

tion of the hip joint, and mental retardation. At the age of 1 year and 6 months, the subject was diagnosed with a chromosome 13 abnormality and did not undergo any further chromosome analysis. She received medical treatment at home and, at the age of 26 years, entered an institution for the mentally and physically disabled, with advanced disease. The subject was referred to us for evaluation of multiple congenital malformations. The physical findings were asymmetric face, downward-slanted palpebral fissure, hypertelorism, low nasal bridge, long philtrum, preauricular fistula, long and slender fingers, and scoliosis.

The subject had a supernumerary chromosome, which was suspected to be of the G group (Fig. 1F-a). Based on the clinical presentation, der (22) (11q; 22q) was suspected, but the subject had been previously diagnosed as having a chromosome 13

abnormality. Her parents would not agree to participate in chromosome analysis. Therefore, lymphocytes from the subject were analyzed by the SKY method. Using this method, a fragment of chromosome 11 was detected on chromosome 22 (Fig. 1F-b). The karyotype was designated as 47, XX, + der (22) t (11; 22) (q23.2; q11.2).

Case 7. The proband was a 3-year-old boy. He was born at 38 weeks of gestation to a 25-year-old mother and an unrelated 29-year-old father. His birth weight was 2,650 g. At 1 year of age, the subject was diagnosed as having mild developmental delay and physical abnormality. At 2 years of age, he started to walk but could not utter any meaningful words. The subject was referred to us for evaluation of multiple congenital malformations. Physical examination showed microcephaly, hypertelorism, almond-like palpebral fissure, protruding ears, anteverted

Table 1 Summary of the G-banding, spectral karyotyping (SKY), and fluorescence *in situ* hybridization (FISH) results and clinical findings.

Case No.	G-banding	FISH	SKY	Clinical Findings	Karyotype
1	+	+	-	Anal atresia, total anomalous pulmonary venous connection, brachycephaly, low nasal bridge, hypertelorism, downward-slanted palpebral fissure, microtia, preauricular fistula, small hands and feet, long fingers, developmental delay.	47, XX, + mar. ish idic (22) (q11.2) (D14Z1/D22Z1)
2	+	+	-	None.	46, XX, t (6; 17) (p24; p13)
3	+	+	-	Brachycephaly, bushy eyebrows, hypertelorism, inverted epicanthus, anteverted nostril, depressed nasal bridge, down-turned corners of the mouth, long philtrum, mild developmental delay.	46, XX, dup (3) (q24q26.2)
4	+	-	+	Prominent forehead, hypertelorism, epicanthus, low nasal bridge, large mouth with widely spaced teeth, clinodactyly of the fingers, developmental delay.	46, XX, dup (8) (p23p12)
5	+	-	+	Flat occiput, coarse hair, round face, up-slanted palpebral fissure, hypertelorism, prominent anteverted nose, low-set ear, simian crease, webbed neck, thorax deformity, cubitus valgus, hypotonia, delayed dental eruption, developmental delay, ventricular septal defect, Agenesis of the corpus callosum.	46, XX, dup (20) (p11.2p13)
6	+	-	+	Cleft palate, atrial septal defect, congenital dislocation of the hip joint, mental retardation, asymmetric face, downward-slanted palpebral fissure, hypertelorism, low nasal bridge, long philtrum, preauricular fistula, long and slender fingers, scoliosis.	47, XX, + der (22) t (11; 22) (q23.2; q11.2)
7	+	+	+	Microcephaly, hypertelorism, almond-like palpebral fissure, protruding ears, anteverted nostrils, brachyclinodactyly of the fifth fingers, tapering fingers, developmental delay.	47, XY, + r (1) (p12q12)/46, XY

nostrils, brachyclinodactyly of the fifth fingers, and tapering fingers.

The subject had a supernumerary marker chromosome, which was identified as 47, XY, +r/46, XY (7%/93%), although the origin of the supernumerary ring chromosome could not be determined (Fig. 1G-a). The parental karyotypes were normal. SKY analysis clearly demonstrated that the small marker chromosome was derived from chromosome 1 (Fig. 1G-b). FISH with the BAC923C6 (1p12) and RR6 (1q12 heterochromatin) probes was used to extend the cytogenetic analysis. The fluorescent signals were positive for both probes (Figs. 1G-c, d), which suggested the 47, XY, +r(1) (p12q12)/46, XX karyotype.

The results obtained for all seven cases are summarized in Table 1.

Discussion

In this study, we describe the application of molecular cytogenetic methods to the characterization of chromosome structure abnormalities that had been previously detected by conventional cytogenetic analysis. By combining molecular cytogenetic methods with conventional G-banding analysis, we were able to precisely identify the karyotypes of all seven cases, four of which (cases 2-5) had chromosomal rearrangements and three of which (cases 1, 6, and 7) had small marker chromosomes.

In general, when a chromosomal aberration is detected, the recommended order of steps in the analysis is (1) G-banding, (2) SKY, and (3) FISH [25, 26]. In cases 1 and 3, the clinical findings and G-banding patterns provided useful information. In case 1, the clinical findings suggested cat eye syndrome [27], and we found a partial tetrasomy of the region that spans the p-arm and part of 22q11, which is characteristic of cat eye syndrome. In case 3, the clinical evaluation revealed mild but typical features of dup (3q) syndrome, as has been previously described [28]. Dup (3q) syndrome individuals are trisomic for segments of the long arm of chromosome 3, most often within the region 3q21 to 3qter; a further minimal critical region has been defined at 3q26.3-q27. Case 3 did not exhibit trisomy for this critical region; therefore, the clinical findings were mild.

In cases of ESAC, the FISH probes must be selected according to the G-banding pattern associated with the karyotype of the patient. Therefore, if the information on the banding pattern is insufficient, the process of choosing the appropriate probes for diagnosis may be time-consuming, and precise identification of the marker may not be possible. Alternatively, SKY provides a unique color display of all the human chromosomes, and it is very useful for rapid characterization of the origin of a chromosome, which facilitates timely counseling. Therefore, this approach can serve as a screening tool for the identification of structural abnormalities and marker chromosomes [15, 16]. SKY analysis in cases 4-7 demonstrated that this method is useful and time-saving. Case 4 was an inverted duplication of 8p, case 5 involved a 20p trisomy, and case 7 was a ring chromosome 1 mosaicism. The clinical features of these conditions have been previously reported [29, 30, 31] and were similar to our findings. The major causes of trisomy 20 are familial translocations or inversion. Case 5 was extremely rare because it resulted from a tandem duplication of the whole short arm of chromosome 20. As our case is an example of pure trisomy of 20p, the features were important in helping to delineate the syndrome. Based on the clinical presentation, case 6 was suspected of being der(22) t(11q; 22q), owing to a 3:1 meiotic non-disjunction event [32]. Case 6 had been previously diagnosed as having a chromosome 13 abnormality, so we used SKY analysis to obtain an immediate diagnosis.

Although SKY is valuable for refining chromosomal aberrations, it has some limitations. In particular, SKY is limited to detecting chromosomal aberrations in the range of 1.5 Mb [7, 16]. Furthermore, although SKY gives approximate sizes for marker chromosomes and rearranged segments, it cannot detect the segments of the chromosome precisely.

In case 7, the marker chromosome consisted of only chromosome 1; therefore, further analysis using FISH was performed. There has been a wide range of phenotypic variability in past cases of ring chromosome 1. Thus, in looking for the origin of a clinical picture, it is important to elucidate the range of the ring chromosome by FISH analysis. In such cases, we recommend a combinatorial approach to karyotyping that takes advantage of the strengths of each methodology while minimizing the disadvantages

of each method.

In case 2, as the couple had a history of habitual spontaneous abortion, a chromosome analysis was routinely performed. The father showed a balanced translocation, and each translocation segment was similar in size and banding pattern. This makes it difficult to recognize the karyotype analysis of amniotic fluid cells by G-banding alone. FISH using LIS1 (17p13.3 probe) gave a positive signal on normal chromosome 17 and derivative chromosome 6, but did not show a positive signal on derivative chromosome 17. The combination of G-banding and FISH immediately revealed the same reciprocal translocation as in the father. The combination of accurate karyotyping and knowledge of the associated natural history, prognosis, and future complications facilitates reliable genetic counseling.

We conclude that the strategy of using conventional cytogenetic techniques to detect marker chromosomes and chromosome structure rearrangements in combination with molecular cytogenetic methods is useful when the identification of chromosome origin by G-banding analysis is unsuccessful. In particular, prenatal diagnosis has the problem of a limited amount of sample material, which might not allow multiple analysis, and advancing gestational age poses serious time limitations. It is necessary to introduce molecular cytogenetic methods to analyze prenatal diagnosis precisely and quickly.

References

1. Ferguson-Smith MA and Yates JRW: Maternal age-specific rates for chromosome aberrations and factors influencing them: a report of collective European study on 52965 amniocenteses. *Prenat Diagn* (1984) 4: 5-44.
2. Hook EB and Cross PK: Extra structurally abnormal chromosomes (ESAC) detected at amniocentesis: frequency in approximately 75,000 prenatal cytogenetic diagnoses and association with maternal and paternal age. *Am J Hum Genet* (1987) 40: 83-101.
3. Warburton D: De novo balanced chromosome rearrangements and extra marker chromosomes identified at prenatal diagnosis: clinical significance and distribution of breakpoints. *Am J Hum Genet* (1991) 49: 995-1013.
4. Sachs ES, Van Hemel JO, Den Hollander JC and Jahoda MG: Marker chromosomes in a series of 10,000 prenatal diagnoses. *Cytogenetics and follow-up studies. Prenat Diagn* (1987) 7: 81-89.
5. Gravholt CH and Friedrich U: Molecular cytogenetic study of supernumerary marker chromosomes in an unselected group of children. *Am J Med Genet* (1995) 56: 106-111.
6. Caspersson T, Zech L, Modest EJ, Foley GE, Wagh U and Simonsson E: Chemical differentiation with fluorescent alkylating agents in *Vicia faba* metaphase chromosomes. *Exp Cell Res* (1969) 58: 128-140.
7. Caspersson T, Zech L and Johansson C: Differential binding of alkylating fluorochromes in human chromosome. *Exp Cell Res* (1970) 60: 315-319.
8. Brondum-Nielsen K and Mikkelsen M: A 10-year survey, 1980-1990, of prenatally diagnosed small supernumerary marker chromosomes, identified by FISH analysis. Outcome and follow-up of 14 cases diagnosed in a series of 12,699 prenatal samples. *Prenat Diagn* (1995) 15: 615-619.
9. Jauch A, Daumer C, Lichter P, Murken J, Schroeder-Kurth T and Cremer T: Chromosome in situ suppression hybridization of human gonosome and autosomes and its use clinical cytogenetics: *Hum Genet* (1990) 85: 145-150.
10. Trask BJ: Fluorescence in situ hybridization: applications in cytogenetics and gene mapping. *Trends Genet* (1991) 7: 149-154.
11. Blennow E, Brondum-Nielsen K, Telenium H, Carter N, Kristoffersson U, Hoimberg E, Gillberg C and Nordenskjold M: Fifty probands with extra structurally abnormal chromosomes characterized by fluorescence in situ hybridization. *Am J Med Genet* (1995) 55: 85-94.
12. Callen DF, Eyre H, Yip MY, Freemantle J and Haan EA: Molecular cytogenetic and clinical studies and clinical studies of 42 patients with marker chromosomes. *Am J Med Genet* (1992) 43: 709-715.
13. Popp S, Jauch A, Schindler D, Speicher MR, Lengauer C, Donis-Keller H, Riethman HC and Cremer T: A strategy for the characterization of minute chromosome rearrangements using multiple color fluorescence in situ hybridization with chromosome-specific DNA libraries and YAC clones. *Hum Genet* (1993) 92: 527-532.
14. Wegner RD, Schrock E, Obladen M, Becker R, Stumm M and Sperling K: Partial trisomy/monosomy 6q in fetal cells and CVS long-term culture not present in CVS short-term culture. *Prenat Diagn* (1996) 16: 741-748.
15. Schrock E, Veldman T, Padilla-Nash H, Ning Y, Spurbeck J, Jalal S, Shaffer LG, Papenhausen P, Kozma C, Phelen MC, Kjeldsen E, Schonberg SA, O'Brien P, Biasecker L, du Manoir S and Ried T: Spectral karyotyping refines cytogenetic diagnostics of constitutional chromosomal abnormalities. *Hum Genet* (1997) 101: 255-262.
16. Veldman T, Vignon C, Schrock E, Rowley J and Ried T: Hidden chromosome abnormalities in haematological malignancies detected multi color spectral karyotyping. *Nat Genet* (1997) 15: 406-410.
17. Schrock E, du Manoir S, Veldman T, Schoell B, Wienberg J, Ferguson-Smith MA, Ning Y, Ledbetter DH, Bar-Am I, Soenksen D, Garini Y and Ried T: Multicolor spectral karyotyping of human chromosome. *Science* (1996) 273: 494-497.
18. Haddad BR, Schrock E, Meck J, Cowan J, Young H, Ferguson-Smith MA, du Manoir S and Ried T: Identified of de novo chromosome markers and derivatives by spectral karyotyping. *Hum Genet* (1998) 103: 619-625.
19. Yaron Y, Carmon E, Goldstein M, Voskoboinik N, Ochshorn Y, Gelman-Kohan Z and Orr-Urtreger A: The clinical application of spectral karyotyping (SKY) in the analysis of prenatally diagnosed extra structurally abnormal chromosomes (ESACs). *Prenat Diagn* (2003) 23: 74-79.
20. Ikeuchi T and Sasaki M: Accumulation of early mitotic cells in ethidium bromide-treated human lymphocyte cultures. *Proc Japan*

- Acad (1979) 55: 15–18.
21. Callen DF, Eyre H, Fang YY, Guan XY, Veleba A, Martin NJ, McGill J and Haan EA: Origins of accessory small ring marker chromosome derived from chromosome 1. *J Med Genet* (1999) 36: 847–853.
 22. Reeser SL, Donnenfeld AE, Miller RC, Sellinger BS, Emanuel BS and Driscoll DA: Prenatal diagnosis of the derivative chromosome 22 associated with cat eye syndrome by fluorescence in situ hybridization. *Prenat Diagn* (1994) 14: 1029–1034.
 23. Sakamoto M, Ono J, Okada S, Masuno M, Nakamura Y and Kurahashi H: Alteration of LIS1 gene in Japanese patients with isolated lissencephaly sequence or Miller-Dieker syndrome. *Hum Genet* (1998) 103: 586–589.
 24. Reddy KS, Wang S, Groh S and Gonatos J: SKY Assessment of two karyotypes with 0–6 supernumerary marker/ring chromosome and review of previously reported cases with two or more markers. *Am J Med Genet A* (2003) 118: 156–171.
 25. Heng HHQ, Ye CJ, Yang F, Ebrahim S, Liu G, Bremer SW, Thomas CM, Ye J, Chen TJ, Tuck-Muller C, Yu JW, Krawetz SA and Johnson A: Analysis of marker or complex chromosomal rearrangements present in pre- and post-natal karyotypes utilizing a combination of G-banding, spectral karyotyping and fluorescence in situ hybridization. *Clin Genet* (2003) 63: 358–367.
 26. Guanciali-Franchi P, Calabrese G, Morizio E, Fantasia D, Colosimo A, Rinaldi MM, Cristini L, Simonelli A, Lonardo F, Turci A, Zatterale A, Lagana C, Stuppia L, Sabatino G and Palka G: Identification of 14 rare marker chromosomes and derivatives by Spectral karyotyping in prenatal and postnatal diagnosis. *Am J Med Genet A* (2004) 127: 144–148.
 27. Schinzel A, Schmid W, Fraccaro M, Tiepolo L, Zuffardi O, Opitz JM, Lindsten J, Zetterqvist P, Enell H, Baccichetti C, Tenconi R and Pagon RA: The “cat eye syndrome”: dicentric small marker chromosome probably derived from a no. 22 (tetrasomy 22pter to q11) associated with a characteristic phenotype. Report of 11 patients and delineation of the clinical picture. *Hum Genet* (1981) 57: 148–158.
 28. Wilson GN, Dasouki M and Barr M Jr.: Further delineation of the dup (3q) syndrome. *Am J Med Genet* (1985) 22: 117–123.
 29. Guo WJ, Callif-Daley F, Zapata MC and Miller ME: Clinical and cytogenetic findings in seven cases of inverted duplication of 8p with evidence of a telomeric deletion using fluorescence in situ hybridization. *Am J Med Genet* (1995) 58: 230–236.
 30. Grammatico P, Cupilari F, Di Rosa C, Falcolini M and Del Porto G: 20 p duplication as a result of parental translocation: familial case report and a contribution to the clinical delineation of the syndrome. *Clin Genet* (1992) 41: 285–289.
 31. Tonnie H, Hennies HC, Spohr HL and Neitzel H: Characterization of the first supernumerary trisentric ring chromosome 1 mosaicism by conventional and molecular cytogenetic techniques. *Cytogenet Genome Res* (2003) 103: 28–33.
 32. Lin AE, Bernar J, Chin AJ, Sparkes RS, Emanuel BS and Zackai EH: Congenital heart disease in supernumerary der (22), t (11; 22) syndrome. *Clin Genet* (1986) 29: 269–275.