

Case Report

Solitary Mandibular Metastasis as an Initial Manifestation of Hepatocellular Carcinoma

Katsunobu Teshigawara^a, Satoru Kakizaki^{a*}, Naondo Sohara^a,
Tetsu Hashida^a, Yoshio Tomizawa^a, Ken Sato^a, Hitoshi Takagi^a,
Masatomo Mori^a, Keiko Hoshino^b, and Kenji Mogi^b

Departments of ^aMedicine and Molecular Science, and ^bStomatology and Maxillofacial Surgery,
Gunma University Graduate School of Medicine, Maebashi, Gunma 371-8511, Japan

Oral metastases from hepatocellular carcinoma are very rare. We encountered a case of hepatocellular carcinoma with a solitary metastasis to the mandible as an initial manifestation. The patient was a 76-year-old man who was admitted for left mandibular swelling. A biopsy specimen of mandible was suspected to be a metastatic tumor. The histological findings, abdominal computed tomography, bone scintigraphy, and F-18 fluorodeoxyglucose-positron emission tomography (FDG-PET) revealed it to be a solitary metastasis from hepatocellular carcinoma. As a result, he was diagnosed to have liver cirrhosis due to a hepatitis C virus infection and hepatocellular carcinoma with a solitary metastasis to the mandible. The primary lesion was treated with transcatheter arterial embolization (TAE), and the metastasis to the mandible was surgically resected. The patient survived for 9 months after treatment without recurrence.

Key words: hepatocellular carcinoma, mandibular metastasis, oral metastasis

Hepatocellular carcinoma (HCC) most frequently metastasizes to the lung, lymph nodes, bone, and adrenal glands [1, 2]. Metastases of HCC to the oral cavity and jaws are uncommon, with only 70 cases being reported in the literature [3-24] since its first description by Dick *et al.* [4] in 1957. Only 1-3% of oral malignancies are metastatic carcinomas from a distant primary [25]. We experienced a rare case of HCC with a solitary metastasis to the mandible as a first manifestation.

Case Report

A 76-year-old man was admitted to the Department of Stomatology and Maxillofacial Surgery, Gunma University Hospital, because of left mandibular swelling and pain. The patient reported that numbness of the left mandible had been present for approximately 10 months, during which time the lesion had exhibited progressive growth. Computed tomography (CT) revealed an osteolytic lesion in the left mandible (Fig. 1A). An oral incisional biopsy was performed, with a subsequent histopathologic examination revealing a malignant neoplasm that appeared to be a metastatic tumor (Fig. 2A). A whole-body examination with F-18 fluorodeoxyglucose-positron emission tomography (FDG-PET)

revealed a high uptake in the left mandible and the liver. The standardized uptake values (SUV) of FDG were 4.77 and 3.42 in the left mandible and liver, respectively (Fig. 1B, Fig. 3A). Abdominal CT revealed 2 liver tumors located in the right anterior lobe, measuring 3 and 5 cm in diameter, respectively. The laboratory examination findings were as follows: hemoglobin, 12.0 g/dl; platelet, $15.7 \times 10^4/\text{mm}^3$; prothrombin time, 89%; albumin, 3.9 g/dl; total bilirubin, 0.7 mg/dl; aspartate transaminase, 37 IU/l; alanine transaminase, 33 IU/l; alkaline phosphatase, 298 IU/l; γ -glutamyl transferase, 51 IU/l; blood urea nitrogen, 19 mg/dl; creatinine, 0.8 mg/dl; amylase, 120 IU/l; total cholesterol 162 mg/dl. In addition, the serum alpha-fetoprotein (AFP); 1096.4 ng/ml and protein induced by vitamin K antagonist (PIVKA)-II; 3,078 AU/ml were elevated. He was negative for hepatitis B surface antigen and positive for hepatitis C antibody. A biopsy specimen from the liver tumor (Fig. 2B) revealed moderately differentiated hepatocellular carcinoma identical to the biopsy specimen of mandibular tumor (Fig. 2A). Bone scintigraphy and FDG-PET showed no obvious metastasis other than that found in the mandible. CT angiography (Fig. 3B, 3C, 3D) showed the typical findings of HCC. He was thus diagnosed to have HCC with a solitary metastasis to the mandible. He was also complicated with liver cirrhosis due to a hepatitis C virus infection. The liver function was classified as Child-Pugh grade A. Swelling of the mandible, pain, and bleeding from the tumor impeded the patient from eating. Because the metastasis was solitary and he had relatively well-preserved liver function, we selected radical treatment of mandibular metastasis instead of palliation therapy with radiation. After treatment, the patient's eating functions as well as his oral hygiene dramatically improved. Although simultaneous resection for liver tumors was also considered, the patient's age led us to select transcatheter arterial embolization (TAE) for the primary liver tumors. Although he received additional TAE for 6 months after the first treatment, the local control of HCC was good and there was no distant metastasis at 9 months after the initial treatment.

Discussion

Oral metastases from HCC are very rare [3-24]. The most common metastatic sites from HCC are the lung, lymph nodes, bone, and adrenal glands [1, 2]. HCC metastases to the oral cavity and jaws have been reported in only 62 cases, according to a review by Pires *et al.* [3] in 2004. We have identified an additional 8 cases. As a result, our case was the 71st case of metastatic HCC to the oral cavity. Regarding oral tumors, only 1-3% of oral malignancies are metastatic carcinomas from a distant primary site, in decreasing order, from the breast, adrenal gland, colorectal system, genital organs, and the thyroid gland in women; and from the lung, prostate, kidney, bone, and adrenal gland for men [25].

The establishment of a diagnosis of metastatic HCC in the oral region may be difficult, particularly when the primary tumor has not yet been identified. Pires *et al.* [3] have reported noting a metastatic oral tumor before the primary hepatic lesion in 66% of patients (41 of 62). Because of a lack of symptoms other than mandibular swelling, our case was initially considered to be a primary mandibular tumor until the biopsy results were revealed. We analyzed all 71 cases of metastatic HCC to the oral region, including our case, reported until now. The mean age of these 71 patients was 62.0 ± 12.0 years old; the median age was 63 years old; and the age ranged from 16 to 88 years old. Males were predominant (male:female:unknown, 58:7:6, respectively), and the most common site of metastasis is the mandible, especially the posterior mandible, followed by the gingiva. Metastasis to the maxilla is quite rare in comparison to the mandible. In addition, the oral tumor was found before the primary HCC in 42 of 71 cases. The oral tumor was found after the diagnosis of HCC in 23 cases (6 cases were unknown).

The way that HCC can disseminate into intraosseous mandibular metastasis has been thoroughly discussed in the literature [8]. Basically, there are 2 pathways from the liver to the maxillofacial territory [8]. When the hepatic artery and the portal vein are affected, metastatic dissemination must reach the lung first, and it may later reach the maxillofacial area [8]. According to such evidence, most of the registered cases of HCC with mandibular metastasis

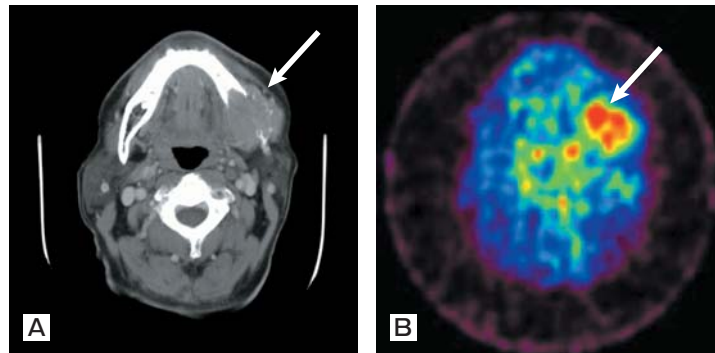


Fig. 1 A, Computed tomography (CT) findings of the left mandible revealed an osteolytic lesion with expanding growth; B, FDG-PET showed a strong accumulation in the left mandible. The standardized uptake value (SUV) of FDG was 4.77.

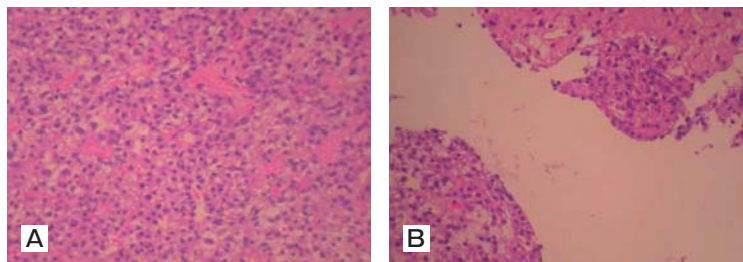


Fig. 2 A, A biopsy specimen from the tumor of the mandible. The proliferation of atypical cells with high N/C ratio and clear cytoplasm were observed; B, The biopsy specimen from liver tumor revealed moderately differentiated hepatocellular carcinoma identical to that found in the mandibular tumor (Fig. 2A).

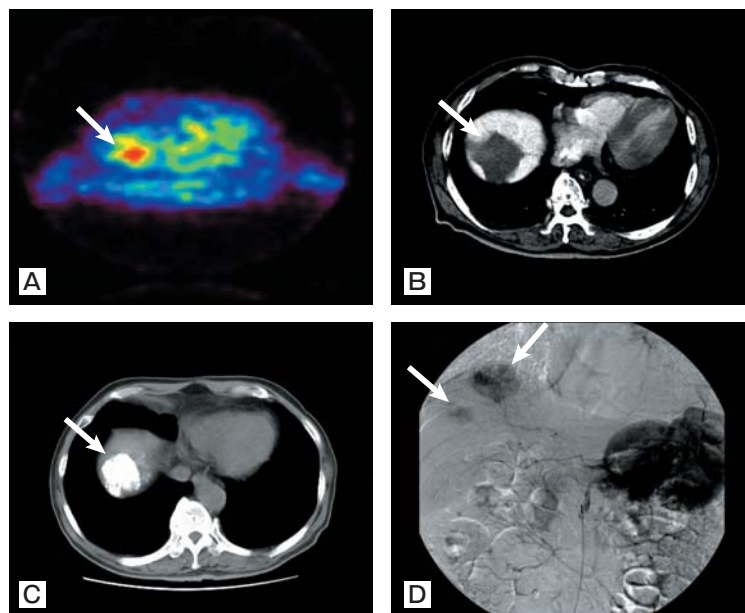


Fig. 3 Abdominal CT and angiography revealed the liver tumors to be located in the right upper lobe, which was thus compatible with HCC. A, FDG-PET showed a strong accumulation in the liver tumor. The standardized uptake value (SUV) of FDG was 3.42. B, CT angiography; C, CT hepatic angiography, early phase; D, digital subtraction angiography.

tend to be accompanied by lung metastasis [6, 9]. However, no lung metastases were identified in our case. To explain this mandibular affectation, it has been postulated that there is a connection between the azygos or hemiazygos veins and the vertebral venous plexus (Batson's plexus) [10, 26]. The solitary mandibular metastasis in our case may further confirm this hypothesis.

The high vascularity of the metastatic lesion with HCC, accompanied by concurrent coagulopathy caused by primary liver disease and often associated with this group of patients, can lead to hemorrhagic episodes, particularly in bone lesions [6, 11, 12]. Hemorrhagic events arising in the oral and maxillofacial region can usually be managed with hemostatic agents, compression, and wide sutures [6, 11–13]. However, the hemorrhaging may occasionally be severe, thus requiring the use of complex procedures such as external carotid ligation [11, 13]. Fortunately, the parameters of coagulation were within normal limits in the case presented herein; more specifically, the patient was able to undergo surgical resection. When such a case is not suitable for surgery, then local radiation therapy with higher fractionated doses appears to be useful for achieving partial control of tumor growth and hemorrhaging [11, 12].

Although the prognosis of patients with HCC has recently improved, the prognosis of those with advanced stage HCC including distant metastases remains unsatisfactory [27]. The prognosis of patients with oral metastatic HCC is very poor, with only palliative treatment frequently indicated to improve the local function [11]. Most patients die within 2 years after a diagnosis of oral metastasis [3]. In our case, a metastatic tumor was completely resected by surgery and the primary lesions were well-controlled with TAE. However, we have continually checked for the appearance of new metastases. Fortunately, the clinical course of our patient was relatively good. However, the indications of radical treatment should be carefully considered because the prognosis of HCC depends on not only the tumor stage of HCC but also on the preserved liver function. A radical resection of metastasis will improve the quality of life only for patients with sufficiently preserved liver function. Although a simultaneous resection for liver tumors was considered, the

patient's age led us to select transcatheter arterial embolization (TAE) for the primary liver tumors. A flexible treatment strategy based on the effect and degree of invasiveness must be carefully taken into account when treating elderly patients.

In conclusion, oral metastatic HCC should be included in the differential diagnosis of rapidly growing oral tumors, particularly in patients with a history of chronic liver disease. Even though most such cases tend to be clinically advanced, an improved quality of life can be obtained by a radical resection of the metastatic oral lesion.

References

1. Katyal S, Oliver JH 3rd, Peterson MS, Ferris JV, Carr BS and Baron RL: Extrahepatic metastases of hepatocellular carcinoma. *Radiology* (2000) 216: 698–703.
2. Kaczynski J, Hansson G and Wallerstedt S: Metastases in cases with hepatocellular carcinoma in relation to clinicopathologic features of the tumor. An autopsy study from a low endemic area. *Acta Oncol* (1995) 34: 43–48.
3. Pires FR, Sagarra R, Correa ME, Pereira CM, Vargas PA and Lopes MA: Oral metastasis of a hepatocellular carcinoma. *Oral Surg Oral Med Oral Pathol Oral Radiol Endod* (2004) 97: 359–368.
4. Dick A, Mead SG, Mensh M and Schatten WE: Primary hepatoma with metastasis to the mandible. *Am J Surg* (1957) 94: 846–850.
5. Arai R, Otsuka T, Mori K, Kobayashi R, Tomizawa Y, Sohara N, Kakizaki S, Hirokawa T, Kanda D, Nakayama H, Nakajima T, Takagi H and Mori M: Metastasis of hepatocellular carcinoma to the supramaxillary gingiva and right ventricle. *Hepato-gastroenterology* (2004) 51: 1159–1161.
6. Marker P and Clausen PP: Metastases to the mouth and jaws from hepatocellular carcinomas. A case report. *Int J Oral Maxillofac Surg* (1991) 20: 371–374.
7. Chin A, Liang TS and Borislow AJ: Initial presentation of hepatocellular carcinoma as a mandibular mass: case report and review of the literature. *Oral Surg Oral Med Oral Pathol Oral Radiol Endod* (1998) 86: 457–460.
8. Junquera L, Rodriguez-Recio C, Torre A, Sanchez-Mayoral J and Fresno MF: Hepatocellular carcinoma metastatic to the mandible: a case involving severe hemorrhage. *Med Oral* (2004) 9: 345–349.
9. Takinami S, Yahata H, Kanoshima A, Yamasaki M, Funaoka K, Nakamura E, Fujiwara T and Totsuka Y: Hepatocellular carcinoma metastatic to the mandible. *Oral Surg Oral Med Oral Pathol Oral Radiol Endod* (1995) 79: 649–654.
10. Yoshimura Y, Matsuda S and Naitoh S: Hepatocellular carcinoma metastatic to the mandibular ramus and condyle: report of a case and review of the literature. *J Oral Maxillofac Surg* (1997) 55: 297–306.
11. Ashar A, Khateery SM and Kovacs A: Mandibular metastatic hepatocellular carcinoma: a case involving severe postbiopsy hemorrhage. *J Oral Maxillofac Surg* (1997) 55: 547–552.
12. Papa F, Ferrara S, Felicetta L, Lavorgna G, Matarazzo M, Staibano S, De Rosa G, Troisi S and Claudio PP: Mandibular

- metastatic hepatocellular carcinoma: report of a case involving severe and uncontrollable hemorrhage. *Anticancer Res* (2001) 21: 2121–2130.
13. Okada H, Kamino Y, Shimo M, Kitamura E, Katoh T, Nishimura H, Akimoto Y, Kaneda T, Hinata M and Yamamoto H: Metastatic hepatocellular carcinoma of the maxillary sinus: a rare autopsy case without lung metastasis and a review. *Int J Oral Maxillofac Surg* (2003) 32: 97–100.
 14. Niedzielska I, Langowska-Adamczyk H, Pajak J, Kajor M, Niedzielski Z and Golka D: Mandible metastasis of hepatocellular carcinoma. *Wiad Lek* (2004) 57: 392–394.
 15. English JC 3rd, Meyer C, Lewey SM and Zinn CJ: Gingival lesions and nasal obstruction in an immunosuppressed patient post-liver transplantation. *Cutis* (2000) 65: 107–109.
 16. Doval DC, Kannan V, Kumaraswamy SV, Reddy BK, Bapsy PP and Rao CR: Mandibular metastasis in hepatocellular carcinoma. *Int J Oral Maxillofac Surg* (1992) 21: 97–98.
 17. Wu YT: Metastatic carcinoma to the oral tissues and jaws: a study of 25 cases. *Zhonghua Kou Qiang Yi Xue Za Zhi* (1990) 25: 258–261.
 18. Horie Y, Suou T, Hirayama C, Urabe N, Yamamoto T, Ikoma H, Hashimoto K and Gomyoda M: Hepatocellular carcinoma metastatic to the oral cavity including the maxilla and the mandible: report of two cases and review of the literature. *Gastroenterol Jpn* (1985) 20: 604–610.
 19. Vigneul JC, Nouel O, Klap P and Al Helali M: Metastatic hepatocellular carcinoma of the mandible. *J Oral Maxillofac Surg* (1982) 40: 745–749.
 20. Ciola B: Pathologic fractures of the mandible following invasive oral carcinomas. *Oral Surg Oral Med Oral Pathol* (1978) 46: 725–731.
 21. Goveia G and Bahn S: Asymptomatic hepatocellular carcinoma metastatic to the mandible. Report of a case. *Oral Surg Oral Med Oral Pathol* (1978) 45: 424–430.
 22. Sarrazin A, Bousquet O, Vaillant JM, Brocheriou C and Trinh-Dinh-Hy: Mandibular metastasis revealing a hepatoma. *Ann Med Interne (Paris)* (1974) 125: 61–64.
 23. Yacabucci JE, Mainous EG and Kramer HS: Hepatocellular carcinoma, diagnosed following metastasis to the mandible. Report of a case. *Oral Surg Oral Med Oral Pathol* (1972) 33: 888–893.
 24. Appenzeller J, Weitzner S and Long GW: Hepatocellular carcinoma metastatic to the mandible: report of case and review of literature. *J Oral Surg* (1971) 29: 668–671.
 25. Hirshberg A, Leibovich P and Buchner A: Metastases to the oral mucosa: analysis of 157 cases. *J Oral Pathol Med* (1993) 22: 385–390.
 26. Batson OV: The function of the vertebral veins and their role in the spread of metastases. 1940. *Clin Orthop* (1995) 312: 4–9.
 27. Kaizu T, Karasawa K, Tanaka Y, Matuda T, Kurosaki H, Tanaka S and Kumazaki T: Radiotherapy for osseous metastases from hepatocellular carcinoma: a retrospective study of 57 patients. *Am J Gastroenterol* (1998) 93: 2167–2171.