

Case Report

Fibular Osteoadiposal Flap for Treatment of Tibial Adamantinoma: A Case Report

Yuzaburo Namba^{a*}, Yoshihiro Kimata^a, Isao Koshima^b,
Shinsuke Sugihara^c, and Tohru Sato^c

^a*Department of Plastic and Reconstructive Surgery, Okayama University Graduate School of Medicine, Dentistry and Pharmaceutical Sciences, Okayama 700–8558, Japan,*

^b*Department of Plastic and Reconstructive Surgery, Graduate School of Medicine and Faculty of Medicine, the University of Tokyo, Bunkyo-ku, Tokyo 113–0033, Japan, and*

^c*Department of Orthopaedic Surgery, Okayama University Graduate School of Medicine, Dentistry and Pharmaceutical Sciences, Okayama 700–8558, Japan*

We treated a case with left tibial adamantinoma by use of a contralateral fibular osteoadiposal flap. The donor site of conventional fibular osteocutaneous flap must be covered with a skin graft because if we close the donor skin defect directly, compartment syndrome might occur. We were able to close the donor skin defect because this combined type flap included only a small monitoring skin paddle. We present herein the utility of the osteoadiposal flap and show the value of a skin-sparing approach with a minimal aesthetic defect.

Key words: adamantinoma, fibular osteoadiposal flap, skin-sparing flap harvest

Adamantinoma frequently develops in the facial bones and sometimes in the long bones. In the latter cases, the patients usually complain of pain, and pathological fractures occur in some cases. When these tumors are not completely resected, they frequently recur. Radical resection is therefore recommended [1, 2]. When only a bony defect remains after a radical bone tumor resection, vascularized bone grafts using the fibula, iliac bone, or scapular have been used for reconstruction. When both a long bone and a large soft tissue defect remains, an osteocutaneous flap such as a fibular osteocutaneous flap has traditionally been used for the complex defect.

Case Report

A 49-year old woman was diagnosed left tibial adamantinoma (Fig. 1, 2). After radical tumor resection along with the middle two-thirds of the left tibia, the surrounding muscles, and the tibialis anterior artery (Fig. 3). The resected tibia was treated with pasteurization (boiling at 60 °C for 30 min) and repositioned. The fibular osteoadiposal flap with a small monitoring skin paddle taken from the right leg was elevated (Fig. 4). The transferred fibula was intercalarized into the vacant bone marrow of the treated tibia and long plate fixation was done (Fig. 5). The adiposal portion of the flap was covered with a mesh skin graft taken from the right inguinal region, and the skin graft donor was closed directly (Fig. 6). To simultaneously reconstruct the tibialis anterior artery and the peroneal artery, vein grafts were

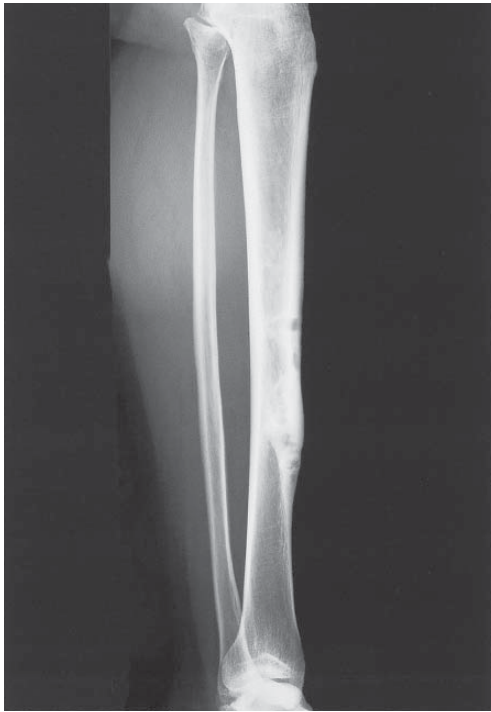

Fig. 1 Preoperative X-P

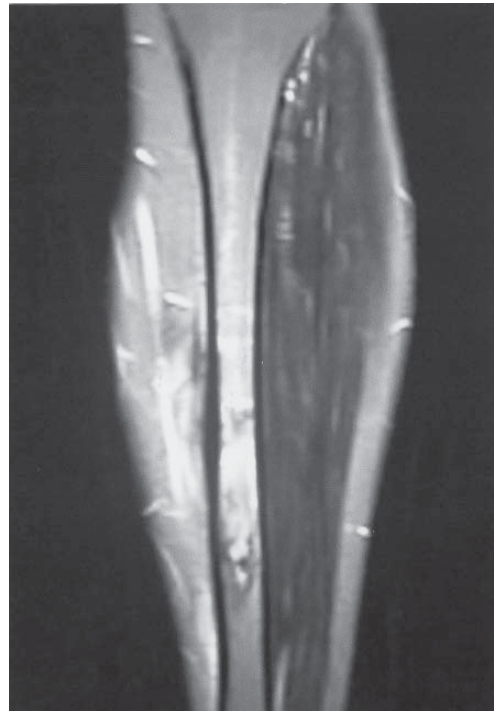

Fig. 2 Preoperative MRI

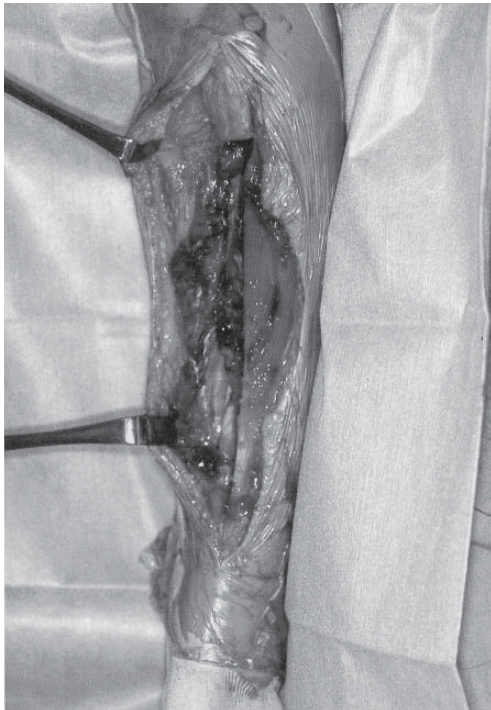


Fig. 3 After radical tumor resection

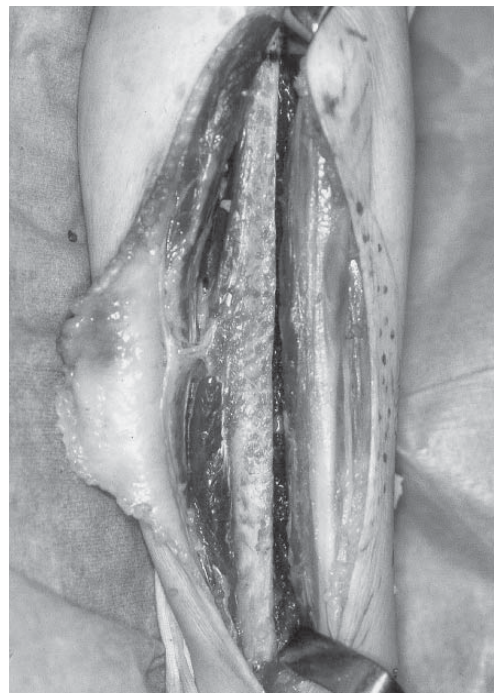

Fig. 4 Fibular osteoadiposal flap

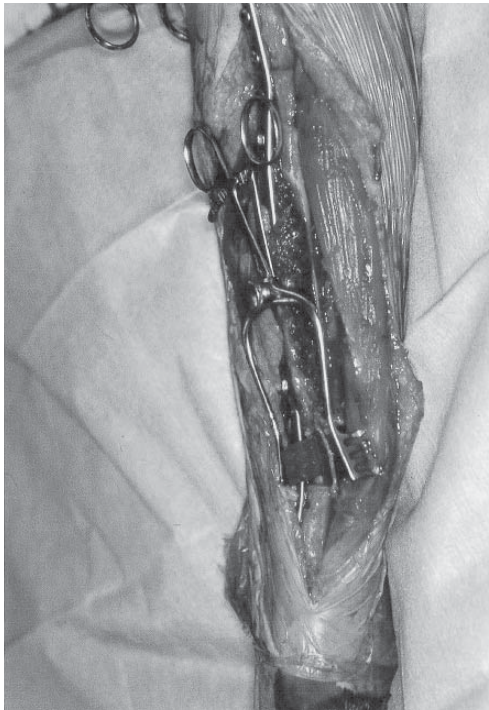

Fig. 5 Vascular anastomosis and long plate fixation

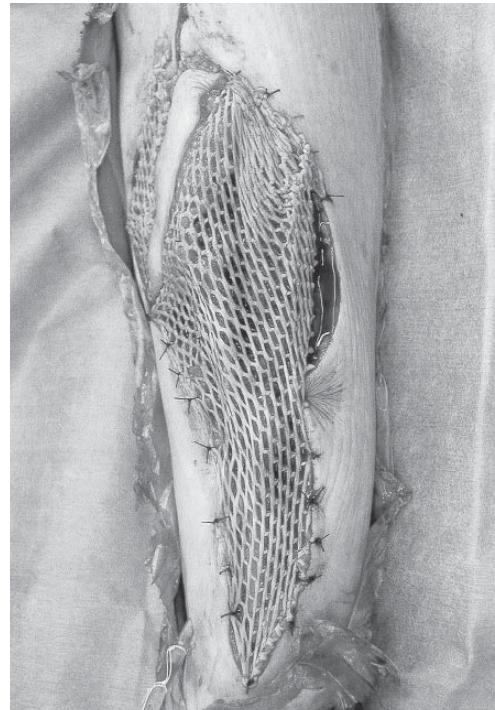


Fig. 6 Mesh skin graft on the adiposal portion

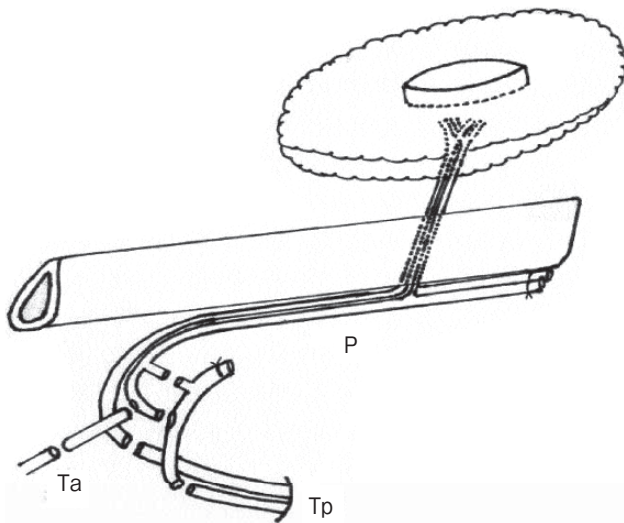


Fig. 7 Schema of the vein grafts and vascular anastomoses P, peroneal vessel; Ta, Tibialis anterior vessel; Tp, Tibialis posterior vessel.

interpositioned between the tibialis posterior artery and the peroneal artery as well as between the tibialis posterior artery and the tibialis anterior artery (Fig. 7). The flap donor site could be closed directly

(Fig. 8). Three months later, the patient could walk with full-weight bearing without crutches (Fig. 9). Four years later, there has been no recurrence, and bony reconstruction is complete (Fig. 10).

Use of the fibular osteocutaneous flap is advantageous in that we can get both a vascularized long bone and a skin flap with one source of vessels (the peroneal artery and veins). It is therefore very useful for the reconstruction of bone and soft tissue defects in the extremities. However, if we take a large skin flap, the donor site must be covered with a skin graft. An ugly skin-grafted scar in the lower leg might not be acceptable to girls and young ladies, so we have introduced the concept of skin-sparing flap harvest. If we use a fibular osteoadiposal flap instead of an osteocutaneous flap, the donor site can be closed directly and we can greatly minimize the donor site morbidity. The osteoadiposal flap is also useful for augmentation plasty [3]. The same concept can be applied to the other flaps such as the deep inferior epigastric artery perforator adiposal flap [4]. With the recent advances in supermicrosurgery [5], we can successfully perform true perforator flaps transfer, which is another way of minimiz-

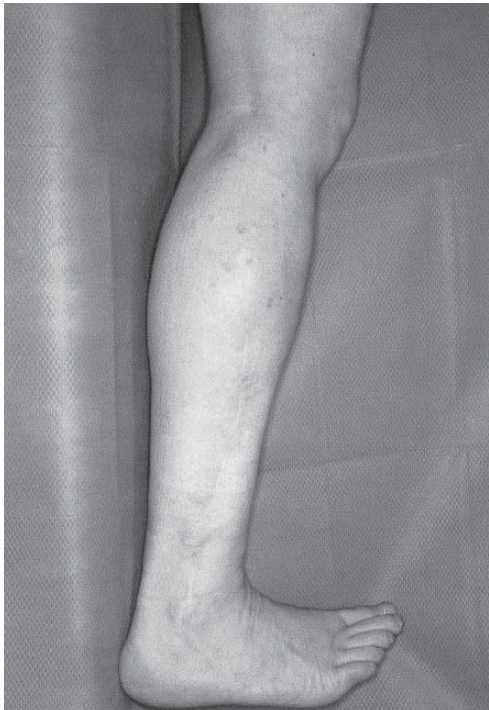

Fig. 8 Donor site (4 years after surgery)

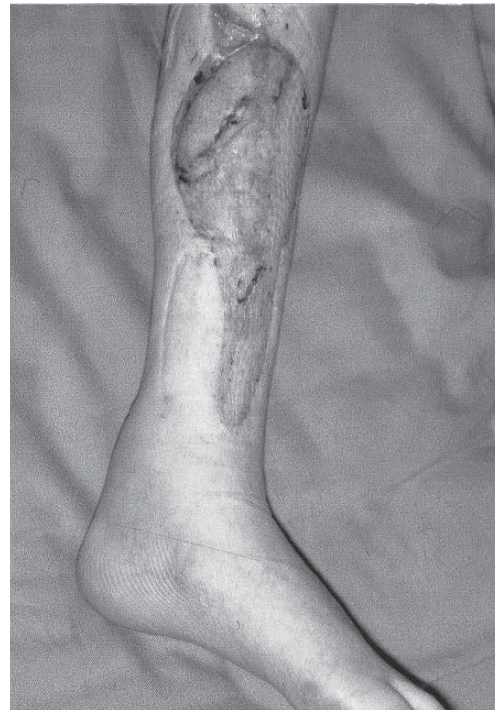

Fig. 9 Clinical appearance (6 months after surgery)

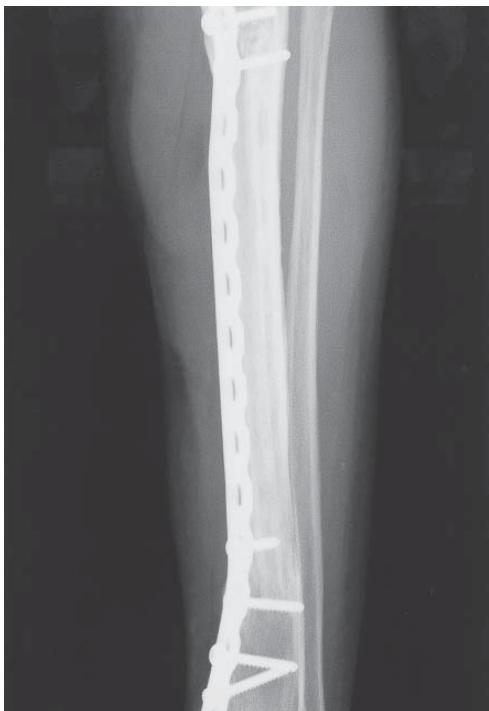

Fig. 10 X-P (4 years after surgery)

ing the donor site morbidity. We herein present a new concept of skin-sparing flap harvest to minimize the donor site morbidity.

References

1. Keeney GL, Unni KK, Beabout JW and Pritchard D J: Adamantinoma of long bones. A clinicopathological study of 85 cases. *Cancer* (1989) 64: 730-737.
2. Mohler DG, Yaszay B, Hong R and Wera G: Intercalary tibial allografts following tumor resection: the role of fibular centralization. *Orthopedics* (2003) 26: 631-637.
3. Namba Y, Ito S, Tsutsui T and Koshima I: Facial augmentation with groin osteoadiposal flap transfer. *J Reconstr Microsurg* (2005) 21: 25-28.
4. Koshima I, Inagawa K, Urushibara K, Ohtsuki M and Moriguchi T: Deep inferior epigastric perforator dermal-fat or adiposal flap for correction of craniofacial contour deformities. *Plast Reconstr Surg* (2000) 106: 10-15.
5. Koshima I, Namba Y, Tsutsui T and Takahashi Y: Medial plantar perforator flaps with supermicrosurgery. *Clin Plastic Surg* (2003) 30: 447-455.