

Case Report

Intraatrial Extension of Thyroid Cancer: A Case Report

Seiichiro Sugimoto^{a*}, Hiroyoshi Doihara^a, Yutaka Ogasawara^a, Motoi Aoe^a,
Shunji Sano^b, and Nobuyoshi Shimizu^a

*Departments of ^aCancer and Thoracic Surgery, and ^bCardiovascular Surgery,
Okayama University Graduate School of Medicine, Dentistry and
Pharmaceutical Sciences, Okayama 700-8558, Japan*

A 61-year-old man, who was diagnosed with superior vena cava syndrome by papillary thyroid carcinoma, was referred to our hospital. A bulky thyroid tumor with tracheal invasion extended from the left neck to the right atrium without distant metastases. The risk of sudden death due to airway occlusion, tumor embolism or obstruction of the tricuspid valve led us to elect surgery. Extended resection of thyroid cancer was performed with cardiopulmonary bypass. Peritoneal dissemination was found via laparotomy. A histological diagnosis of anaplastic carcinoma arising from transformation of papillary carcinoma was made. After the operation, bilateral ureteral occlusion by peritoneal dissemination and multiple lung metastases were detected. The patient died with acute renal failure on postoperative day 12. Intraatrial extension of thyroid cancer is rare, and only 12 cases have been reported in the literature. We present a case of thyroid cancer with intraatrial extension.

Key words: superior vena cava syndrome, thyroid cancer, cardiopulmonary bypass

Superior vena cava syndrome (SVCS) by intravascular invasion is an uncommon complication of thyroid cancer. In particular, intraatrial extension via superior vena cava (SVC) of the tumor has rarely been described and, to our knowledge, only 12 cases have been reported [1-6]. Surgical treatment to remove the tumor thrombus was performed in 5 of these cases, and cardiopulmonary bypass (CPB) was used in only one case, in which pulmonary dissemination after the treatment with CPB was reported [5]. The use of CPB for cardiopulmonary support in operations for malignancies makes extended resection possible; however, one of the disadvantages of using CPB is the hematogenous dissemination of tumor cells, and so the application of

CPB to oncologic surgery is still controversial [5]. We herein describe a surgical case of thyroid cancer with intraatrial extension and rapid tumor spread after an operation with CPB was performed.

Case Report

A 61-year-old man, who was diagnosed with SVCS and thyroid papillary carcinoma by fine-needle aspiration biopsy cytology, was referred to our hospital for treatment. The patient had a growing anterior neck mass for a year, hoarseness and dysphagia for 10 months, and head and neck edema for 3 months. He had stridor, a fist-sized neck tumor involving the left supraclavicular fossa, dilated veins in the anterior chest wall and edema of the face, neck, and bilateral arms suggesting SVCS. Laboratory tests showed a mild elevation of C-reactive protein and fibrinogen, but the patient's

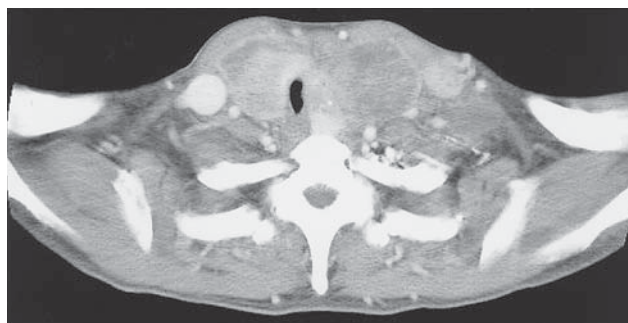white blood cell (WBC) count, thyroglobulin, triiodothyronine, thyroxine and thyroid-stimulating hormone were within normal limits (Table 1). A large bulky thyroid tumor with tracheal invasion and extensive nodal involvement in the neck and upper mediastinum, which extended into the left internal jugular vein, the bilateral brachiocephalic veins, the SVC, and the right atrium with thrombosis, was revealed by chest computed tomography (CT) (Fig. 1), magnetic resonance imaging (MRI) (Fig. 2), ^{131}I -scintigraphy, and venography. Fiberoptic bronchoscopy demonstrated the left vocal cord palsy and tracheal mucosa invasion. The patient's electrocardiogram was normal and transthoracic echocardiography showed the tumor invasion attached

to the tricuspid valve. There was no evidence of brain, bone, lung or liver metastases as determined by brain MRI, bone scintigraphy, and chest and abdominal CT. The patient was preoperatively diagnosed with SVCS by intraatrial extension of thyroid papillary carcinoma. Consideration of these factors, as well as the risk of sudden death from airway occlusion, tumor embolism or obstruction of the tricuspid valve, led us to elect surgical treatment.

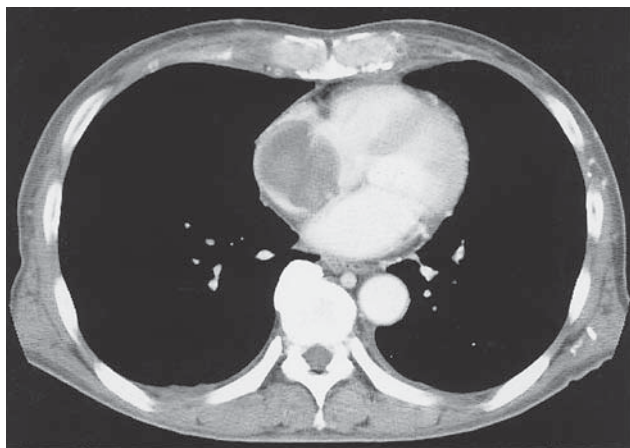
The patient was anesthetized and intubated safely despite tracheal invasion of the tumor, though preparations had been made to place him on CPB. Total thyroidectomy and bilateral modified neck dissection were performed through an extended collar incision,

Table 1 Laboratory data on admission

White blood cell	6600/ μl	Na	142mEq/l
Red blood cell	$350 \times 10^4/\mu\text{l}$	K	3.8mEq/l
Hemoglobin	10.4g/dl	Cl	103mEq/l
Hematocrit	31.50%	Ca	8.9mg/dl
Platelet	$20.4 \times 10^4/\mu\text{l}$	Blood urea nitrogen	12.5mg/dl
		Creatinine	0.66mg/dl
Total protein	7.04g/dl	Fasting blood glucose	73mg/dl
Albumin	3.07g/dl	Fibrinogen	527mg/dl
Total bilirubin	0.50mg/dl	C-reactive protein	3.8mg/dl
Aspartate aminotransferase	16IU/l	Free triiodothyronine	1.75pg/dl
Alanine aminotransferase	11IU/l	Free thyroxine	1.36ng/dl
Alkaline phosphatase	159IU/l	Thyroid-stimulating hormone	4.21 $\mu\text{U/ml}$
γ -glutamyl transpeptidase	22IU/l	Thyroglobulin	14.3ng/ml
Lactate dehydrogenase	255IU/l		



A



B

Fig. 1 Chest computed tomography. A large bulky thyroid tumor with tracheal invasion extended into the left internal jugular vein (A) and the right atrium (B).

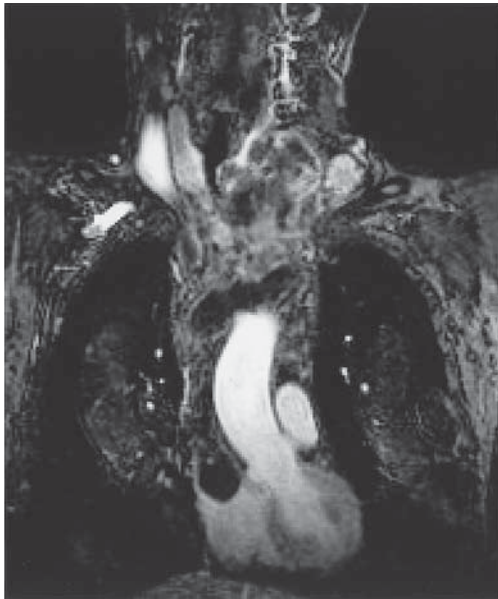
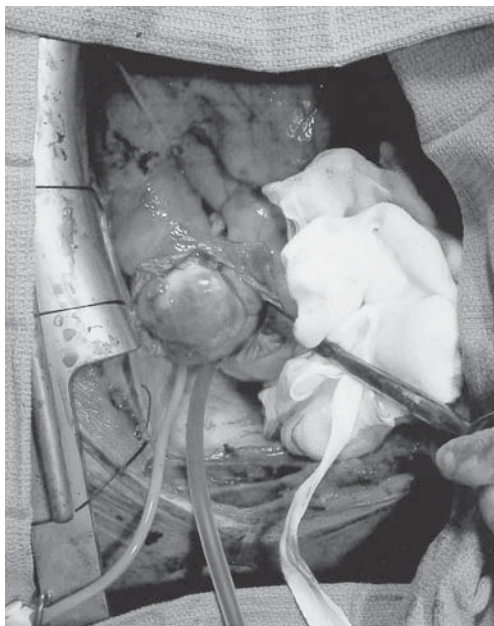

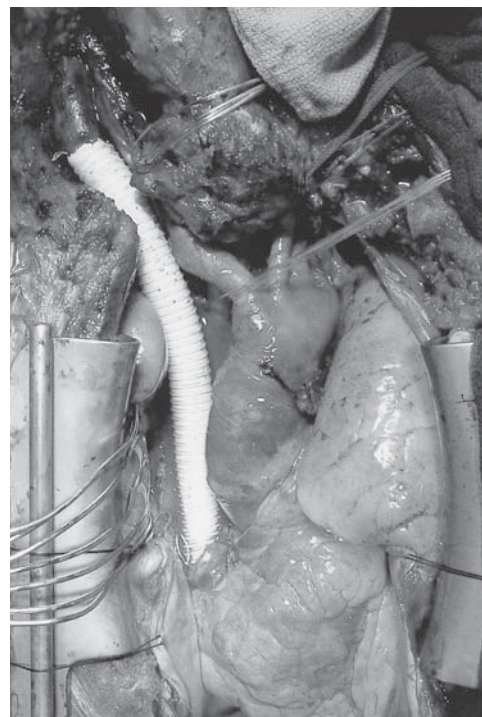
Fig. 2 Magnetic resonance imaging. The tumor extended into the left internal jugular vein, the bilateral brachiocephalic veins, the superior vena cava and the right atrium.

and then median sternotomy was performed. The bilateral brachiocephalic veins and SVC were filled with the tumor thrombus and were dilated widely, and thus they had to be resected because of their total occlusion and adherence of the tumor thrombus to the venous wall. A right atriotomy was performed and the great veins with the tumor, hanging like a pear into the right atrium and nearly obstructing the tricuspid valve (Fig. 3A), were removed by using CPB via femoral-femoral cannulation. The right phrenic nerve was resected with SVC. A vascular graft (expanded polytetrafluoroethylene; Gore-Tex) was interposed between the right internal jugular vein and the right atrium to reconstruct the venous vascular system (Fig. 3B). Sleeve resection of the trachea and tracheostomy were performed after the patient was weaned from CPB. Peritoneal dissemination was then found during laparotomy for tube jejunostomy.

Macroscopically, a large tumor replaced the whole thyroid lobes and invaded into the tracheal



A



B

Fig. 3 Operative findings. **A**, The tumor, hanging like a pear into the right atrium, was exposed; **B**, A vascular graft was interposed between the right internal jugular vein and the right atrium to reconstruct the venous vascular system.

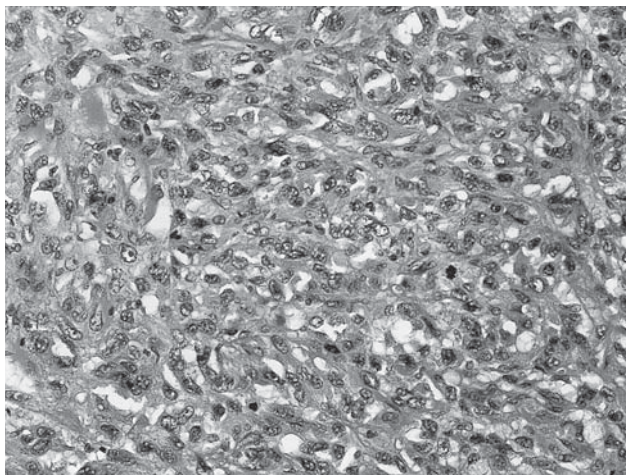
mucosa. The bilateral brachiocephalic veins and

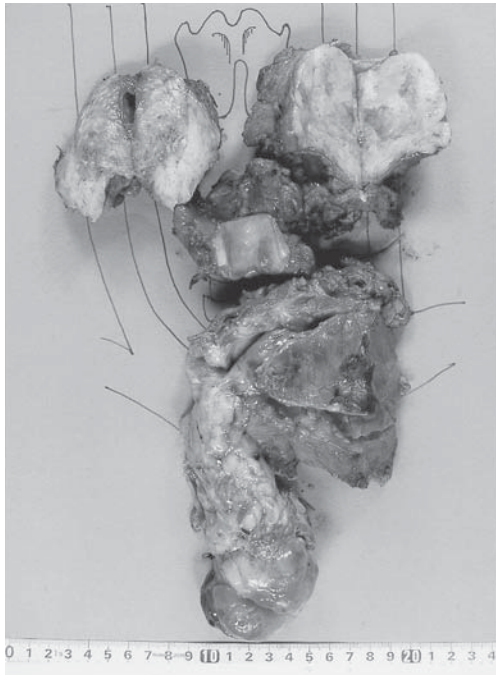

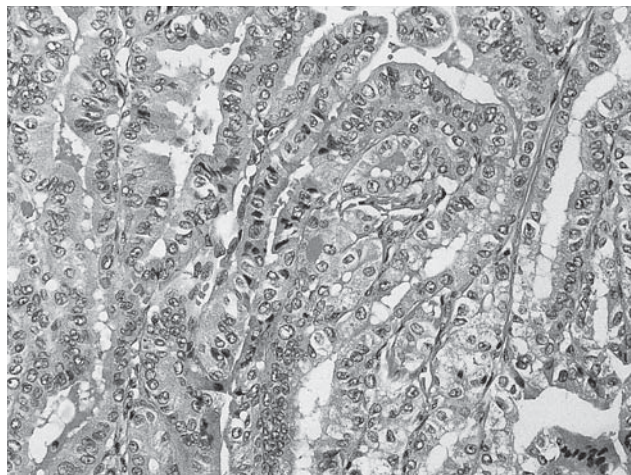
Fig. 4 Macroscopic findings of the resected specimen. A large thyroid tumor invaded the tracheal mucosa, and the bilateral brachiocephalic veins and superior vena cava were filled with the tumor, which was fixed firmly to the venous wall.

SVC were filled with the tumor, which was fixed firmly to the venous wall (Fig. 4). Microscopically, the majority of the tumor was composed of spindle-shaped cells with high mitotic figures and areas of necrosis, suggesting undifferentiated carcinoma (Fig. 5A). The tumor cells consisted of papillary carcinoma and undifferentiated carcinoma around the trachea (Fig. 5B). Therefore, the pathological diagnosis was spindle-cell anaplastic thyroid carcinoma arising from the transformation of papillary carcinoma. Immunohistochemical examination revealed that the tumor cells were stained with a polyclonal antibody against granulocyte colony stimulating factor (G-CSF).

After surgery, weaning from a ventilator was performed on postoperative day (POD) 4 as a result of left phrenic nerve palsy. Leukocytosis without signs of infection was observed in the postoperative course. Suddenly, renal dysfunction appeared on POD 10, and marked leukocytosis over $30,000/\text{mm}^3$ was revealed at that time. Computed tomography showed multiple lung metastases, bilateral ureteral occlusion and hydronephrosis by peritoneal dissemination. Metastasis, ischemia or thrombosis of the renal vessels causing intrinsic acute renal failure were not seen in either kidney. In spite of the ureteral stent insertion, the patient died due to



A



B

Fig. 5 Histological findings of the resected specimen. **A**, The majority of the tumor was composed of spindle-shaped cells with high mitotic figures and areas of necrosis, suggesting undifferentiated carcinoma (hematoxylin and eosin, $\times 200$); **B**, Tumor cells consisted of papillary carcinoma and undifferentiated carcinoma around the trachea (hematoxylin and eosin, $\times 200$).

Table 2 Review of 13 cases: intraatrial extension of thyroid cancer

Author	Year	Sex	Age	Symptom	Diagnosis	Extension	Pathology	Treatment	Outcome
Kaufmann ¹	1879	F	58	G, SVCS	At autopsy	SVC, RA	MC	None	Died 2 months
Billroth ¹	1898	F	51	G	At autopsy	SVC, RA	GC	Subtotal thyroidectomy	Died after surgery
Springer ¹	1901	F	44	G, SVCS	At autopsy	SVC, RA, RV	SC	Tracheostomy	Died 2 months
Wylegschnanin ¹	1930	F	52	G, SVCS	At autopsy	SVC, RA	FC	None	Died 2 months
Holt ¹	1934	M	72	G, SVCS	At autopsy	SVC, RA, RV, IVC	AC	None	Died 5 days
Mencarelli ³	1934	M	56	SVCS	At autopsy	SVC, RA, RV	NTC	None	Sudden death
Kim ²	1966	M	64	G, SVCS	At autopsy	SVC, RA, RV, PO	FC	None	Died 14 days
Thompson ³	1978	F	67	G, SVCS	Venography	SVC, RA	FC	Tumor thrombectomy	Alive 36 months
Niederle ⁴	1990	M	57	G, SVCS	Venography, CT	SVC, RA	FC	Tumor thrombectomy	Died 13 months
		F	79	G, SVCS	At surgery	SVC, RA	FC	Tumor thrombectomy	Alive 50 months
		F	53	G, SVCS	Venography, CT	SVC, RA	FC	Tumor thrombectomy	Died 8 months
Hasegawa ⁵	2002	F	78	G	At surgery	SVC, RA	PC	Extended resection	Died 36 days
Sugimoto	present	M	61	G, SVCS	CT, Venography	SVC, RA	UC	Extended resection	Died 12 days

G, goiter; SVCS, superior vena cava syndrome; CT, computed tomography; SVC, superior vena cava; RA, right atrium; RV, right ventricle; IVC, inferior vena cava; PO, pulmonary outflow; MC, medullary cancer; GC, giant cell; SC, sarcoma; FC, follicular cancer; AC, adenocarcinoma; NTC, nontypical thyroid cancer; PC, papillary cancer; UC, undifferentiated cancer.

postrenal acute renal failure caused by bilateral ureteral obstruction on POD 12. An autopsy was not performed.

Discussion

SVCS by intraluminal extension is an uncommon complication of thyroid cancer. SVCS is more commonly produced by external compression caused by a malignant retrosternal goiter or lymph node metastases [4]. Intraatrial extension of the tumor has seldom been described. To our knowledge, only 12 cases have been reported in the literature. A review of these cases and ours (Table 2) shows that 11 of 13 patients had SVCS, the most common clinical presentation of patients with thyroid cancer extending into the great veins [3]. Only one patient had distant metastases preoperatively [4]. Intraatrial extension of thyroid cancer shows high mortality rates; however, 4 patients underwent tumor thrombectomy involving a great vein tumor thrombus [6] and survived from 8 to 50 months. The last 2 patients, including our case, underwent extended resection with CPB and had early postoperative tumor dissemination. Pathologically, 6 of 13 were diagnosed as follicular carcinoma, which has a well-documented microscopic characteristic of angioinvasion.

Thompson *et al.* [3] reported that there were 2 types of involvement of the heart in thyroid cancer. In the first type, the right cardiac chambers may be

filled with a tumor extending directly through the thyroid veins by way of SVC. Intraluminal infiltration of cancer cells into a great vein initiates the deposition of fibrin on the cells, which allows their continued growth into the lumen of the vessel [4]. It is rare for remote metastases to occur in this type of involvement [3]. The second type has the character of a truly remote metastasis and usually involves widespread metastases, especially of the lungs and bone. Cardiac metastases occur in no more than 1% of patients who die from thyroid carcinoma [3]. In our case, the intraatrial extension was the same as in the first type, and peritoneal dissemination was seen during the operation, though distant metastases rarely occur in this type. The pathologic diagnosis might account for the cause of the rare metastases, for anaplastic thyroid carcinoma is a locally and systemically aggressive disease in contrast to well-differentiated thyroid carcinoma. Anaplastic thyroid carcinoma has occasionally produced G-CSF [7]. Although the WBC count in this case was within normal limits preoperatively, leukocytosis without signs of infection was observed after surgery, suggesting that the tumor may have produced G-CSF. We could not measure the serum level of G-CSF, but immunostaining disclosed that the tumor was positive for G-CSF. In addition, CPB may favor the onset of leukocytosis. Misoph M *et al.* [8] reported that a significant increase in leukocyte counts was detected during CPB, resulting in a

marked leukocytosis postoperatively. CPB might increase the risk of leukocytosis without signs of infection in this case.

The clinical course of differentiated thyroid cancer is usually good, and the presence of massive intravascular invasion is no contraindication for aggressive surgical treatment [4]. In this case, preoperative evidence showed that the patient had a papillary carcinoma without any distant metastases, though the tumor extended from the neck to the right atrium. The risk of sudden death from airway occlusion, tumor embolism or obstruction of the tricuspid valve led us to elect surgery. In general, when an endocrine tumor extends into the venous lumen, the actual tumor mass will be within a fibrous capsule; as a result, the tumor may not invade into the endothelium [4]. However, it was impossible to remove the tumor thrombus by thrombectomy because of the total occlusion and adherence to the venous wall, and the extended resection with CPB had to be performed. We believe that the intraatrial extension of differentiated thyroid cancer is no contraindication for surgical treatment because of the good prognosis with adjuvant radioiodine, but we do not elect surgery with the preoperative diagnosis of anaplastic thyroid carcinoma because of the poor survival rate. The most important factor is the preoperative histological type of thyroid cancer. We should have performed a preoperative needle biopsy of the intraluminal tumor in the left internal jugular vein or intraoperative incisional biopsy of the tumor before the extended resection.

The use of CPB in oncologic surgery is still controversial because of the likelihood of hematogenous tumor dissemination. Hasegawa *et al.* [5] reported 2 possible mechanisms of this dissemination. First, tumor cells contaminating the reservoir blood might spread through the arterial cannula, particularly in situations involving a long CPB period, the re-use of suctioned blood, or the intravascular extension of the tumor, though CPB might be used without increasing the risk of hematogenous tumor dissemination [9]. Second, modification of homeostasis by CPB may liberate tumor cells that have already been spread preoperatively, but whose growth or migration has been suppressed by the host defense

system. In our case, intravascular invasion with thrombosis and intraatrial extension was seen. Although suctioned blood from the surgical field was re-used through the Cell-Saver System, it is strongly suspected that CPB played a significant role in the postoperative spread of the tumor. CPB should only be applied to patients without distant metastasis or dissemination, and exploratory thoracotomy or laparotomy should be performed to confirm pleural or peritoneal dissemination intraoperatively before using CPB.

In conclusion, it is possible to use CPB to resect intraatrial extension of thyroid carcinoma that cannot be removed by tumor thrombectomy. This extensive operation can prevent sudden death due to tumor embolism or obstruction of the tricuspid valve, and yet the prognosis for this disease may still be extremely poor.

References

1. Holt WL: Extension of malignant tumors of thyroid into great veins and right heart. *JAMA* (1934) 102: 1921-1924.
2. Kim RH, Mautner L, Henning J and Volpe R: An unusual case of thyroid carcinoma with direct extension to great veins, right heart and pulmonary arteries. *Can Med Assoc J* (1966) 94: 238-243.
3. Thompson NW, Brown J, Orringer M, Sisson J and Nishiyama R: Follicular carcinoma of the thyroid with massive angioinvasion: extension of tumor thrombus to the heart. *Surgery* (1978) 83: 451-457.
4. Niederle B, Hausmaninger C, Kretschmer G, Polterauer P, Neuhold N, Mizra DF and Roka R: Intraatrial extension of thyroid cancer: technique and results of a radical surgical approach. *Surgery* (1990) 108: 951-956.
5. Hasegawa S, Otake Y, Bando T, Cho H, Inui K and Wada H: Pulmonary dissemination of tumor cells after extended resection of thyroid carcinoma with cardiopulmonary bypass. *J Thorac Cardiovasc Surg* (2002) 124: 635-636.
6. Koike E, Yamashita H, Watanabe S, Yamashita H and Noguchi S: Brachiocephalic vein thrombus of papillary thyroid cancer: report of a case. *Surg Today* (2002) 32: 59-62.
7. Iwasa K, Noguchi M, Mori K, Ohta N, Miyazaki I, Nonomura A, Mizukami Y, Nakamura S and Michigishi T: Anaplastic thyroid carcinoma producing the granulocyte colony stimulating factor (G-CSF): report of a case. *Surg Today* (1995) 25: 158-160.
8. Misoph M, Babin-Ebell J, Schwender S, Grossmann R, Keller F and Elert O: Response of the cellular immune system to cardiopulmonary bypass in vivo. *Thorac Cardiovasc Surg* (1997) 45: 217-223.
9. Akchurin RS, Davidov MI, Partigulov SA, Brand JB, Shiriaev AA, Lepilin MG and Dolgov IM: Cardiopulmonary bypass and cell-saver technique in combined oncologic and cardiovascular surgery. *Artif Organs* (1997) 21: 763-765.