

Original Article

Effects of Phlebotomy on the Growth of Ferric Nitrilotriacetate-Induced Renal Cell Carcinoma

Akiko Mizote, Akira I Hida, Mutsumi Hosako, Masayoshi Fujisawa,
Mika Kamekawa, and Shigeru Okada*

*Department of Pathological Research, Faculty of Medicine, Okayama University Graduate School of
Medicine and Dentistry, Okayama 700-8558, Japan*

The ferric nitrilotriacetate-induced carcinogenesis model is unique in that reactive oxygen species-free radicals are involved in the carcinogenic process. But the effects of iron-withdrawal in the progression of renal cell carcinoma are not well understood. We performed repeated phlebotomies on animals that had been administered ferric nitrilotriacetate in the initiation stage of renal cell carcinoma (phlebotomy group), and compared the development of renal tumors with those not receiving repeated phlebotomies (non-phlebotomy group). Ferric nitrilotriacetate-treated male Wistar rats were randomly divided into 2 groups: a phlebotomy group (21 rats) and a non-phlebotomy group (17 rats). Ten age-adjusted normal rats were also observed as a normal group. Hematocrit was maintained under 25% in the phlebotomy group. Hematocrit levels in the normal group and in the non-phlebotomy group were not significantly different. As a result, the incidence of renal cell carcinoma was not significantly different between phlebotomy and non-phlebotomy animals. However, the total weight of the renal cell carcinoma was significantly heavier in the animals from non-phlebotomy group than in those from the phlebotomy group ($23.64 \text{ g} \pm 18.54$ vs. $54.40 \text{ g} \pm 42.40$, $P < 0.05$). The present study demonstrated that phlebotomy after the administration of ferric nitrilotriacetate did not reduce the incidence of renal cell carcinoma. In addition, we showed that iron withdrawal at the promotion stage of carcinogenesis will retard tumor growth.

Key words: ferric nitrilotriacetate, renal cell carcinoma, phlebotomy

Intraperitoneal injection of ferric nitrilotriacetate (Fe-NTA) induces renal proximal tubular damage, and repeated injections ultimately lead to a high incidence of renal cell carcinoma (RCC) in rats and mice (reviewed by Okada [1]). The Fe-NTA-induced carcinogenesis is a unique animal model characterized by the following features: 1) the kidney is the sole target organ; 2) there is a high incidence of tumors (30-90%), often with

pulmonary metastases and peritoneal invasion in male rodents; and 3) reactive oxygen species-free radicals are involved in the carcinogenic process. Our study and other previous reports have shown that after Fe-NTA treatment in the kidney, an increase in oxidative DNA base modifications can take place, giving such products as 8-hydroxydeoxyguanosine [2-5], thymine-tyrosine cross-links [6], thiobarbituric acid-reactive substance [7, 8, 9], saturated and unsaturated mutagenic aldehydes *e.g.*, 4-hydroxy-2-nonenal (HNE) and malondialdehyde (MDA) [3, 10], and HNE-, MDA-modified proteins [7, 9, 10, 11]. Supplemental vitamin E and other

Received February 21, 2002; accepted March 18, 2002.

*Corresponding author. Phone: +81-86-235-7141; Fax: +81-86-235-7148
E-mail: okadas@cc.okayama-u.ac.jp (S. Okada)

radical scavengers present in food suppressed the incidence of RCC [5, 12]. Fe-NTA-induced RCC was shown to have no mutations in H-, K- and N- *ras* oncogenes, and a low incidence of mutation in the *p53* tumor suppressor gene [13, 14]. Recent data suggest that inactivation of *p15^{INK4B}* and *p16^{INK4A}* genes could be one of the major pathways responsible for Fe-NTA-induced carcinogenesis [15].

In humans as well as animals, there is no active iron excretion mechanism (reviewed by Okada [16]). Therefore, the iron injected during Fe-NTA cancer induction studies is mostly retained, and the experimental animals are thereby characteristically overloaded with iron. The effects of iron-overload in the growth of RCC are not known. We performed repeated phlebotomies in animals having received Fe-NTA, and compared growth of RCC with those observed in non-phlebotomized animals.

Materials and Methods

Animals and experimental design. Three week-old male Wistar rats were purchased from Charles River, Japan. They were fed normal rat chow (Oriental Yeast, Tokyo, Japan). Animal experiments were strictly performed in accordance with the Guidelines for Animal Experiments by Okayama University Medical School. After a week of acclimation, 42 rats received Fe-NTA, and 10 rats were left untreated throughout. Fe-NTA was administered 2 times a week for 3 months (5–7 mg/kg body weight) by intraperitoneal injection. Fe-NTA treated rats received total of 27–54 mg of iron.

Fe-NTA was prepared by the method described by Awai *et al* [17]. In brief, nitrilotriacetic acid disodium salt (NTA, Nacalai Tesque, Kyoto, Japan) and ferric nitrate 9H₂O (Wako, Osaka, Japan) were dissolved in distilled water, and the ferric solution was mixed with the NTA solution. The pH was adjusted to 7.0 with sodium bicarbonate (Ishizu, Osaka, Japan). The molar ratio Fe to NTA was 1:4.

At the termination of Fe-NTA treatment, 38 out of 42 rats treated with Fe-NTA remained alive, and all of the animals were switched to a low-iron diet (Oriental Yeast, Tokyo, Japan). The animals were randomly divided into 2 groups, namely, a phlebotomy group (21 rats) and a non-phlebotomy group (17 rats). The phlebotomy group underwent exsanguinations of 5 ml or less at a time under ether anesthesia, 2 times a week, from a retro-orbital venous plexus through a heparinized

hematocrit tube. Hematocrit was maintained under 25%.

Eighteen months from the final Fe-NTA injection, all animals were sacrificed by exsanguination under ether anesthesia. Serum was collected after centrifugation (10 min, 3000 rpm). The weight of the organs and tumors, serum iron, and total iron binding capacity (TIBC) was measured. The observation of tumor histology was performed by routine Hematoxylin-Eosin staining. Soluble iron from the liver and kidney was measured as described below.

Determination of soluble iron. Soluble iron was measured by the method of Brueckmann and Zondek [18]. To extract soluble iron, 0.1 g of liver tissue was ground in a glass homogenizer, 0.5 ml of saturated sodium pyrophosphate, and one ml of 10% trichloroacetic acid. Then, the homogenate was quantitatively transferred to a wide glass centrifuge tube. The tube was then heated in a boiling water bath for exactly 7 min, and immediately centrifuged. These extracts contained low molecular weight iron and ferritin. Iron was measured by an Fe-test kit (Wako, Osaka, Japan). All glassware was washed with 0.1 N HCl and rinsed with iron-free water.

Statistical analysis. Student's *t*-test was used for the statistical analyses.

Results

Changes in body weight during the experiment are shown in Fig. 1. In the phlebotomy group, 4 of the 21 rats died during phlebotomy or during anesthesia; one of the 17 non-phlebotomy rats died due to tumor growth

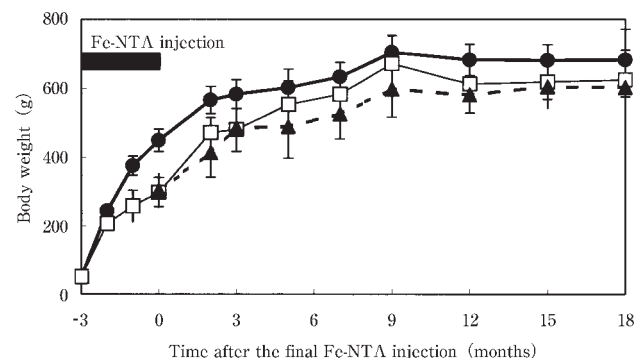


Fig. 1 Changes in body weight during the experiment. (▲) phlebotomy group (n = 21); (□) non-phlebotomy group (n = 17); (●) untreated group (n = 10). (average \pm S.D.).

during the observation period.

Serum iron was between 25 and 30 $\mu\text{g}/\text{dl}$ in the phlebotomy group during the observation period. TIBC increased from the first 12 months, but decreased with age. Hematocrit remained under 25% (Fig. 2). The final iron concentration at the end of the experiment is shown in Table 1. Animals in the phlebotomy group were slightly hypoferrinemic. However, the TIBC of the non-phlebotomy group was not significantly different from that of the normal group. Hematocrit did not significantly differ between the untreated and non-phlebotomy groups (26%–38%). Soluble iron was significantly decreased in the kidneys of the phlebotomy group ($P < 0.05$ vs. untreated and non-phlebotomy). Soluble iron in liver was not significantly different among groups (Fig. 3).

The incidence of RCC was not significantly different between the phlebotomy and non-phlebotomy animals. However, the total weight of RC tumors was significantly heavier in animals of the non-phlebotomy group than in

those of the phlebotomy group (Table 2).

Macroscopic and microscopic pictures of Fe-NTA-induced RCC in a non-phlebotomized rat are shown in Fig. 4. Microscopically, the tumors were composed of granular or clear cells, and/or revealed sarcomatoid subtypes (Fig. 4b, c). Fe-NTA-induced RCC in a phlebotomized rat is shown in Fig. 5. Generally, the tumors from phlebotomized rats were smaller than those tumors from non-phlebotomized rats. The microscopic pictures were not different among the individuals of each group (Fig. 5b).

Discussion

Fe-NTA, when injected intraperitoneally, is absorbed from the peritoneum into the portal vein. After some clearance of iron in the liver, Fe-NTA flows into the systemic circulation. Fe-NTA exists as free iron in the serum for at least a few hours after serum transferrin

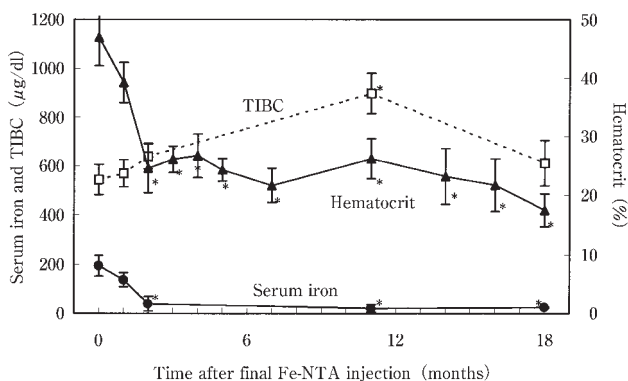


Fig. 2 Changes in serum iron, total iron binding capacity (TIBC), and hematocrit in the phlebotomy group. (\blacktriangle) hematocrit; (\square) TIBC; (\bullet) serum iron. (average \pm S.D.). *statistically significant ($P < 0.01$) from the initiation of phlebotomy.

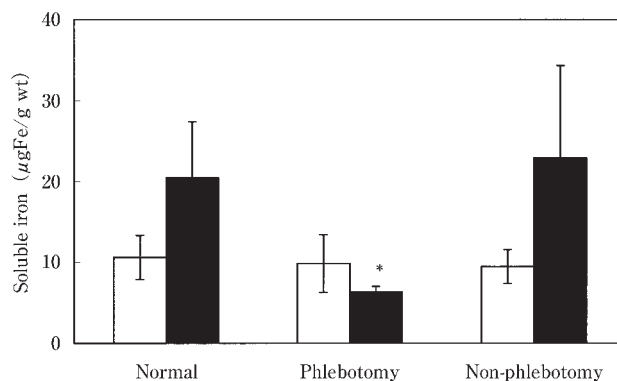


Fig. 3 Soluble iron in liver and kidney at the end of the experiment. Filled column, kidney; open column, liver. * $P < 0.05$ vs. untreated or non-phlebotomy group.

Table 1 Differences in serum iron, TIBC, and hematocrit between the 3 groups at the end of the experiment

groups	Serum iron ($\mu\text{g}/\text{dl}$)	TIBC ($\mu\text{g}/\text{dl}$)	Hematocrit (%)
Normal	136.50 \pm 66.03	634.83 \pm 65.11	36.76 \pm 3.75
Phlebotomy	22.67 \pm 2.89**	896.67 \pm 82.70*	20.33 \pm 2.60*
Non-phlebotomy	77.00 \pm 40.89	670.00 \pm 88.41	32.59 \pm 4.79

* $P < 0.01$ vs. untreated or non-phlebotomy groups. ** $P < 0.05$ vs. normal or non-phlebotomy groups.

Table 2 Incidence of renal cell carcinoma and differences in tumor weight in animals of the phlebotomy and non-phlebotomy groups

groups	Number of rats used	Number of effective rats	Incidence of RCC (%)	Tumor weights (g)
Normal	10	10	0 (0)	
Phlebotomy	21	17	9 (53)	23.64 \pm 18.54*
Non-phlebotomy	17	16	9 (56)	54.40 \pm 42.40

* $P < 0.05$ vs. non-phlebotomy.

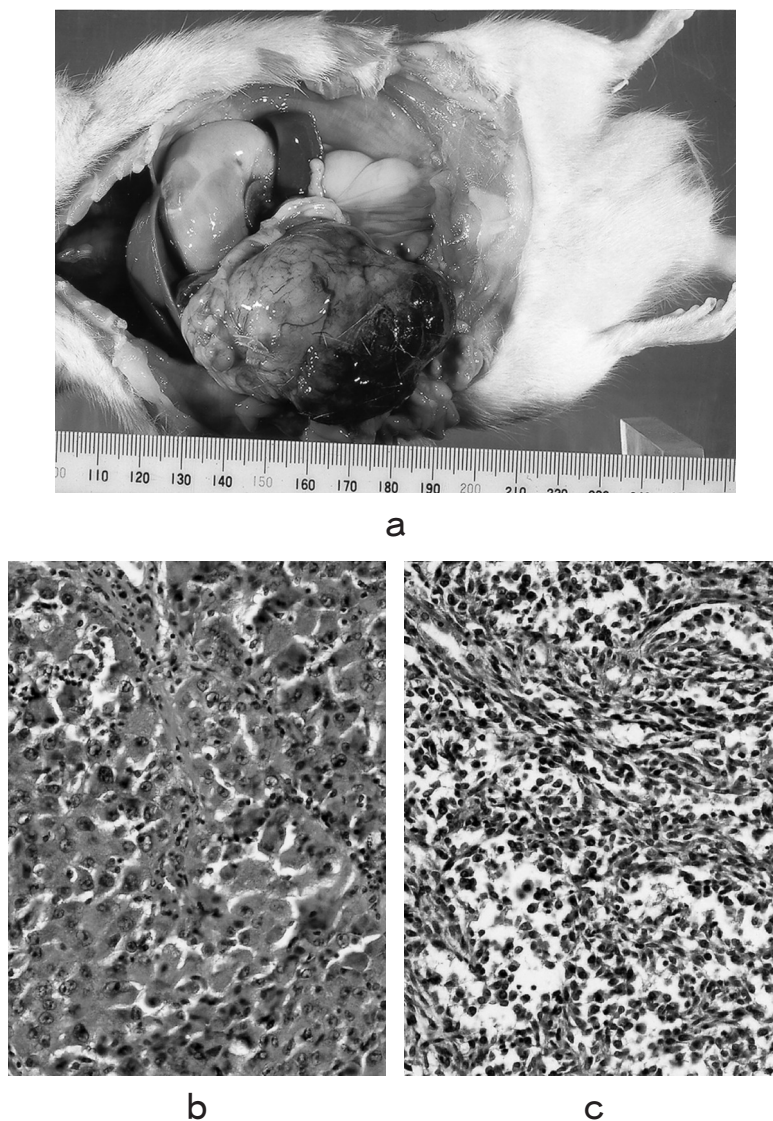
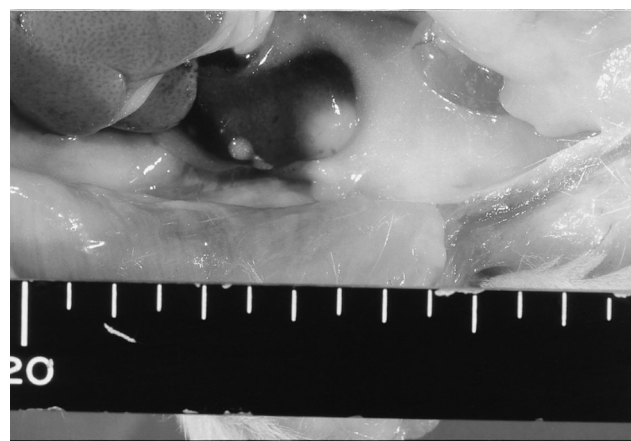


Fig. 4 Renal cell carcinoma induced by Fe-NTA in non-phlebotomized rats. (a) A large right-sided renal tumor that was observed 18 months after the final Fe-NTA treatment, and the histology of the renal cell carcinoma, (b) granular cell carcinoma, (c) sarcomatoid carcinoma.

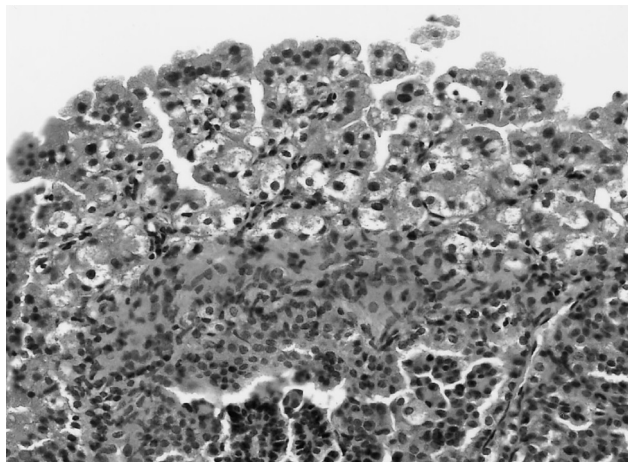
molecules are saturated; subsequent excretion of iron by the kidney then takes place [19]. Since the molecular weight of Fe-NTA is low, it is filtered through glomeruli to the lumina of the renal proximal tubules, where the lipid peroxidation reaction is induced [20, 21, 22]. For lipid peroxidation to occur, the following conditions must be met in the luminal environment in the proximal tubules: 1) an absence of albumin that works as non-specific scavenger in the urine; 2) abundant cysteine as an iron reductant by the presence of the GSH cycle; 3) neutral

pH and average ionic strength. This environment appears to be optimal for the Fenton-like reaction to occur *in vivo* [23].

When reactive oxygen species-free-radicals are generated in close proximity to DNA, they can cause point mutations, DNA cross-linking, and DNA strand breaks, and thus possess the capacity to alter normal cells [24]. Recently, Toyokuni's group reported the specific allelic loss of the *p16^{INK4A}* tumor suppressor gene as one of the early events leading to rat renal carcinogenesis due to



a



b

Fig. 5 Renal cell carcinoma induced by Fe-NTA in non-phlebotomized rats. (a) A small right-sided renal tumor that was observed 18 months after the final Fe-NTA treatment, and the microscopic picture of a renal cell carcinoma (b). The histological pictures did not differ from those obtained from non-phlebotomized rat tumors. The picture here shows a granular cell type tumor with a papillary growth pattern.

iron-mediated oxidative damage [25]. Free radicals can also activate protein kinases and growth factors and their receptors, which are both essential for tumor promotion [26]. Although 6 out of 12 renal cell carcinoma cases had either local or distant metastases according to previous longitudinal reports [14], we did not observe any metastases in the present study. This discrepancy might reflect one or more of the following 4 explanations: the use of different Wistar strains (slc: Wistar in a previous

study vs. crj: Wistar in the present study), early termination of the present study at 18 months, a higher iron dose in the previous study, or a lower iron diet after the initial Fe-NTA treatment in the present study.

Free iron is a strong mediator of free radical production [1, 24]. The potency of iron as a carcinogen is summarized in a recent review [16]. When Fe-NTA was incubated with primary culture renal cells, *in vitro* transformation of the cultured cells was observed. This strongly suggests that the effects of iron on target cells are direct [27]. Weinberg has argued that host iron status may influence the incidence and intensity of neoplasia, and that iron-withholding represents a defense against infection and neoplasia [28, 29]. Weinberg has furthermore stressed the growth advantage of neoplastic cells, and also the suppression of the host defense system in the milieu of iron overload. Our results were in accord with Weinberg's hypothesis, and growth retardation was observed under an iron-restricted environment. Neoplastic cell growth retardation is also expected under iron-restricted environment. In the culture system of the Fe-NTA-induced RK 532 cell line [27]; we will attempt to demonstrate this process in our next experiment. There remains some concern that the phlebotomy treatment itself might affect various metabolic pathways, and that the growth retardation of tumors as regards size could be interpreted as a general growth retardation affecting body mass due to the decline of the host's vital status. When we consider the body weight curve shown in Fig. 1, it is apparent that there was no growth retardation among the animals in our phlebotomy group; therefore, in this regards, no gross negative effect could have been attributed to the phlebotomy procedure itself. Recent successful trials of iron withholding and phlebotomy in patients with chronic hepatitis C have been encouraging, and there is no evidence that vital status was negatively affected by phlebotomy [30, 31].

We fed animals an iron-free diet after the initiation stage. Soluble iron in the liver was not significantly different between the phlebotomy and non-phlebotomy groups, but soluble iron in the kidney was significantly different between the 2 groups. This may mean metabolically active iron in the liver was used during body growth (Fig. 1), and was kept under homeostatic control through the production of transferrin. Soluble iron in the kidney may have been present in a local environment, and was subject to the iron status of the entire body. A non-phlebotomized, iron-rich environment is beneficial for

tumor growth [32]. Therefore, we conclude that iron withdrawal at the promotion stage of carcinogenesis will retard tumor growth.

Acknowledgement. We are grateful to Mr. H. Sakai for his respectful care of the laboratory animals.

Reference

- Okada S: Iron-induced tissue damage and cancer: The role of reactive oxygen species-free radicals. [Review] *Pathol Int* (1996) **46**, 311–332.
- Umemura T, Sai K, Takagi A, Hasegawa R and Kurokawa Y: Oxidative DNA damage, lipid peroxidation and nephrotoxicity induced in the rat kidney after ferric nitrilotriacetate administration. *Cancer Lett* (1990) **54**, 95–100.
- Toyokuni S, Tanaka T, Nishiyama Y, Okamoto K, Nakashima Y, Hamazaki S, Okada S and Hiai H: Induction of renal cell carcinoma in male Wistar rats treated with cupric nitrilotriacetate. *Lab Invest* (1996) **75**, 239–248.
- Yamaguchi R, Hirano T, Asami S, Sugita A and Kasai H: Increase in the 8-hydroxyguanine repair activity in the rat kidney after the administration of a renal carcinogen, ferric nitrilotriacetate. *Environ Health Perspect* (1996) **104** (Suppl 3), 651–653.
- Zhang D, Okada S, Yu Y, Zheng P, Yamaguchi R and Kasai H: Vitamin E inhibits apoptosis, DNA modification, and cancer incidence induced by iron-mediated peroxidation in Wistar rat kidney. *Cancer Res* (1997) **57**, 2410–2414.
- Toyokuni S, Mori T, Hiai H and Dizdaroglu M: Treatment of Wistar rats with a renal carcinogen, ferric nitrilotriacetate, causes DNA-protein cross-linking between thymine and tyrosine in their renal chromatin. *Int J Cancer* (1995) **62**, 309–313.
- Hamazaki S, Okada S, Ebina Y, Li JL and Midorikawa O: Effect of dietary vitamin E on ferric nitrilotriacetate-induced nephrotoxicity in rats. *Toxicol Appl Pharmacol* (1988) **92**, 500–506.
- Toyokuni S, Okada S, Hamazaki S, Minamiyama Y, Yamada Y, Liang P, Fukunaga Y and Midorikawa O: Combined histochemical and biochemical analysis of sex hormone dependence of ferric nitrilotriacetate-induced renal lipid peroxidation in ddY mice. *Cancer Res* (1990) **50**, 5574–5580.
- Toyokuni S, Uchida K, Okamoto K, Hattori-Nakakuki Y, Hiai H and Stadtman ER: Formation of 4-hydroxy-2-nonenal-modified proteins in the renal proximal tubules of rats treated with a renal carcinogen, ferric nitrilotriacetate. *Proc Natl Acad Sci USA* (1994) **91**, 2616–20.
- Toyokuni S, Luo XP, Tanaka T, Uchida K, Hiai H and Lehotay DC: Induction of a wide range of C (2–12) aldehydes and C (7–12) acylolins in the kidney of Wistar rats after treatment with a renal carcinogen, ferric nitrilotriacetate. *Free Rad Biol Med* (1997) **22**, 1019–1027.
- Uchida K, Itakura K, Kawakishi S, Hiai H, Toyokuni S and Stadtman ER: Characterization of epitopes recognized by 4-hydroxy-2-nonenal specific antibodies. *Arch Biochem Biophys* (1995) **324**, 241–248.
- Kimoto T, Koya S, Hino K, Yamamoto Y, Nomura Y, Micallef MJ, Hanaya T, Arai S, Ikeda M and Kurimoto M: Renal carcinogenesis induced by ferric nitrilotriacetate in mice, and protection from it by Brazilian propolis and artemisinin C. *Pathol Int* (2000) **50**, 679–689.
- Akiyama T, Hamazaki S and Okada S: Absence of ras mutations and low incidence of p53 mutations in renal cell carcinomas induced by ferric nitrilotriacetate. *Jpn J Cancer Res* (1995) **86**, 1143–1149.
- Nishiyama Y, Suwa H, Okamoto K, Fukumoto M, Hiai H and Toyokuni S: Low incidence of point mutations in H-, K- and N-ras oncogenes and p53 tumor suppressor gene in renal cell carcinoma and peritoneal mesothelioma of Wistar rats induced by ferric nitrilotriacetate. *Jpn J Cancer Res* (1995) **86**, 1150–1158.
- Tanaka T, Iwasa Y, Kondo S, Hiai H and Toyokuni S: High incidence of allelic loss on chromosome 5 and inactivation of p15^{INK4B} and p16^{INK4A} tumor suppressor genes in oxystress-induced renal cell carcinoma of rats. *Oncogene* (1999) **18**, 3793–3797.
- Okada S: Iron and carcinogenesis in laboratory animals and humans: a mechanistic consideration and review of literature. *Int J Clin Oncol* (1998) **3**, 191–203.
- Awai M, Narasaki M, Yamanoi Y and Seno S: Induction of diabetes in animals by parenteral administration of ferric nitrilotriacetate. A model of experimental hemochromatosis. *Am J Pathol* (1979) **95**, 663–673.
- Brueckmann G and Zondek SG: An improved method for the determination of non-hem iron. *J Biol Chem* (1940) **135**, 23–30.
- Liu M, Okada S and Kawabata T: Radical-promoting “free” iron level in the serum of rats treated with ferric nitrilotriacetate: Comparison with other iron chelate complexes. *Acta Med Okayama* (1991) **45**, 401–408.
- Hamazaki S, Okada S, Toyokuni S and Midorikawa O: Thiobarbituric acid-reactive substance formation of rat kidney brush border membrane vesicles induced by ferric nitrilotriacetate. *Arch Biochem Biophys* (1989) **274**, 348–354.
- Okada S, Minamiyama Y, Hamazaki S, Toyokuni S and Sotomatsu A: Glutathione cycle dependency of ferric nitrilotriacetate-induced lipid peroxidation in mouse proximal renal tubules. *Arch Biochem Biophys* (1993) **301**, 138–42.
- Kawabata T, Ma Y-X, Yamadori I and Okada S: Iron-induced apoptosis in mouse renal proximal tubules after an injection of a renal carcinogen, iron-nitrilotriacetate. *Carcinogenesis* (1997) **18**, 1389–1394.
- Toyokuni S and Sagripanti JL: Induction of oxidative single- and double-strand breaks in DNA by ferric citrate. *Free Radic Biol Med* (1993) **15**, 117–23.
- Halliwell B and Aruoma OI: DNA and Free Radicals. Ellis Horwood, West Sussex (1993)
- Hiroyasu M, Ozeki M, Kohda H, Echizenya M, Tanaka T, Hiai H and Toyokuni S: Specific allelic loss of p16^{INK4A} tumor suppressor gene after weeks of iron-mediated oxidative damage during rat renal carcinogenesis. *Am J Pathol* (2002) **160**, 419–424.
- Dreher D and Junod AF: Role of oxygen free radicals in cancer development. *Eur J Cancer* (1996) **32A**, 30–38.
- Takehashi C, Mori M, Kawabata T and Okada S: *In vitro* transformation of rat renal cells by treatment with ferric nitrilotriacetate. *Acta Med Okayama* (2001) **55**, 97–103.
- Weinberg ED: Iron withholding: A defense against infection and neoplasia. *Physiol Rev* (1984) **64**, 65–102.
- Weinberg ED: Roles of iron in neoplasia. Promotion, prevention, and therapy. *Biol Trace Elem Res* (1992) **34**, 123–140.
- Hayashi H, Takikawa T, Nishimura N, Yano M, Isomura T and Sakamoto N: Improvement of serum aminotransferase levels after phlebotomy in patients with chronic active hepatitis C and excess hepatic iron. *Am J Gastroenterol* (1994) **89**, 986–988.
- Kato J, Kobune M, Nakamura T, Kuroiwa G, Takada K, Takimoto R, Sato Y, Fujikawa K, Takahashi M, Takayama T, Ikeda T and Niitsu Y: Normalization of elevated hepatic 8-hydroxy-2'-deoxyguanosine levels in chronic hepatitis C patients by phlebotomy and low iron diet. *Cancer Res* (2001) **61**, 8697–8702.
- Weinberg ED: The role of iron in cancer. *Eur J Cancer Prev* (1996) **5**, 19–36.