

## Experimental Models of Small Intestinal Transplantation in Rats: Orthotopic versus Heterotopic Model

Atsunori Nakao<sup>a,b\*</sup>, Kazunori Tahara<sup>b</sup>, Seichiro Inoue<sup>b</sup>,  
Noriaki Tanaka<sup>a</sup>, and Eiji Kobayashi<sup>b</sup>

<sup>a</sup>Department of Surgery I, Okayama University Medical School, Okayama 700-8558, Japan, and

<sup>b</sup>Divisions of Organ Replacement Research, Center for Molecular Medicine,  
Jichi Medical School, Tochigi 329-0498, Japan

Two kinds of surgical models of small intestinal transplantation (SITx) in rats, namely heterotopic (HIT) and orthotopic transplantation (OIT), have been reviewed. In OIT, the small intestine of the recipient is removed and the transplanted intestine replaces it in continuity. On the other hand, in the HIT model, the small intestinal grafts are rendered dysfunctional without alimentary tract continuity. Histological evidence showed that acute rejection appeared earlier in HIT as compared to OIT. Hyperplasia and hypertrophy of the muscularis externa produced in the chronic rejection process were more pronounced in HIT allografts. The HIT grafts showed severe mucosal atrophy due to the lack of intraluminal trophic factors, because oral feedings can stimulate trophic hormones for mucosal growth, and provide nutrients for enterocytes. Intestinal permeability was consistently higher after HIT than after OIT. The HIT grafts demonstrated less contractility and less response to chemical stimulation than did OIT grafts. The OIT models are advantageous in studies of intraluminal nutrients, and intestinal secretions in these models might modulate the intestinal immune status and possibly delay rejection. The superior intestinal barrier function and the delayed onset of rejection in OIT rats suggest that nutrients and other factors in the succus entericus are important for the maintenance of intestinal graft function.

**Key words:** small intestinal transplantation, rat, experimental model, orthotopic, heterotopic

The unique immune response after small intestinal transplantation (SITx) has been the subject of extensive research using rat as small animal models. Rat model is a well-established, inexpensive, and ethically acceptable, and various inbred strains of rats with well-defined histocompatibility properties are available. Moreover, the existence of inbred strains allows for reproducibility and defined immunobiological conditions.

Since Monchik and Russel described the first rat model of heterotopic SITx in 1971 [1], various immunological reactions have been studied [2-13].

Generally, 2 kinds of models of rat small intestinal transplantation (SITx) including heterotopically transplanted (HIT) [6-9] and orthotopically transplanted (OIT) have been used so far [5, 10-13]. In OIT which was developed by Kort *et al.*, the small intestine of the recipient is removed and the transplanted intestine replaces it in continuity [4]. On the other hand, in HIT model, the small intestinal grafts are rendered dysfunctional without alimentary tract continuity. The recipient's

intestine is not removed in HIT.

Each model has both advantages and pitfalls, and it is important to choose appropriate models in accordance to the purpose of the study [15]. Here, we compared the advantages and disadvantages of these 2 surgical models based on the review of the previous literature and our own experiences in details.

### Surgical Procedure

**Heterotopic model (Fig. 1A).** Two different methods of HIT have been commonly used so far [16]. In one, one end of the graft is placed as an ileostoma while the other is placed as a duodenostoma in the abdominal wall of the recipients [1, 17-21]. In the other model, the anal side of the graft is anastomosed to the terminal ileum of the recipient while other is sutured to the abdominal wall as a duodenostoma [17, 18].

**Donor operation.** The aorta above and below the origin of the superior mesenteric artery (SMA) is mobilized by ligating and dividing the renal and lumbar arteries. After systemic heparinization and ligation of the

distal abdominal aorta, the donor whole small bowel is harvested based on a vascular pedicle consisting of the superior mesenteric artery with a part of aorta, and the portal vein which is transected near its bifurcation.

**Recipient operation.** After the inferior vena cava (IVC) and the aorta are released from surrounding connective tissue and cross-clamped with microvessel clips below the left renal vessels, the arterial end-to-side anastomosis is performed first under a surgical microscope using 10-0 prolene. Secondly, the donor portal vein is placed end to side into the recipient IVC by running sutures using 10-0 prolene. The ends of the small intestine are exteriorized and sutured to the abdominal wall as ileostomies. The abdominal wall is then closed.

**Orthotopic model (Fig. 1B).** Generally, there are 2 kinds of OIT: the one-stage OIT described here and two-stage OIT, where the first step is the heterotopically transplantation as described above is orthotopically set 2 or 3 weeks later [18, 19]. We use the one step operation, because its surgical mortality is comparable with two-step technique (unpublished data). The preparation of the donor and vascular anastomoses in

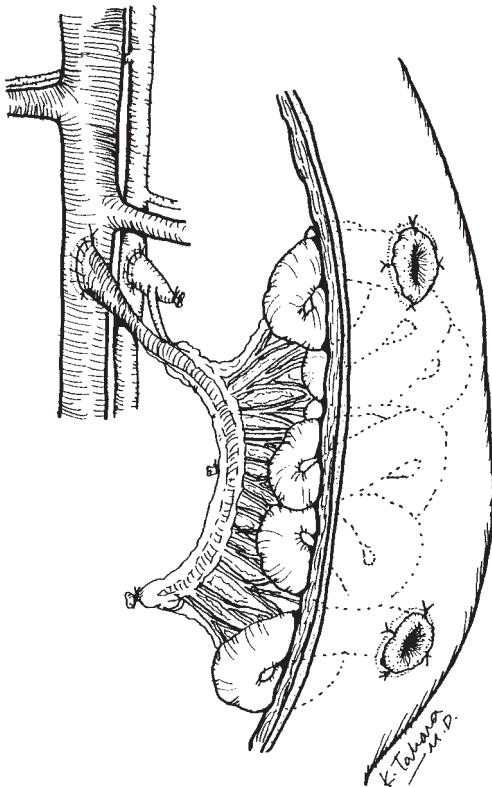


Fig. 1A Heterotopic model

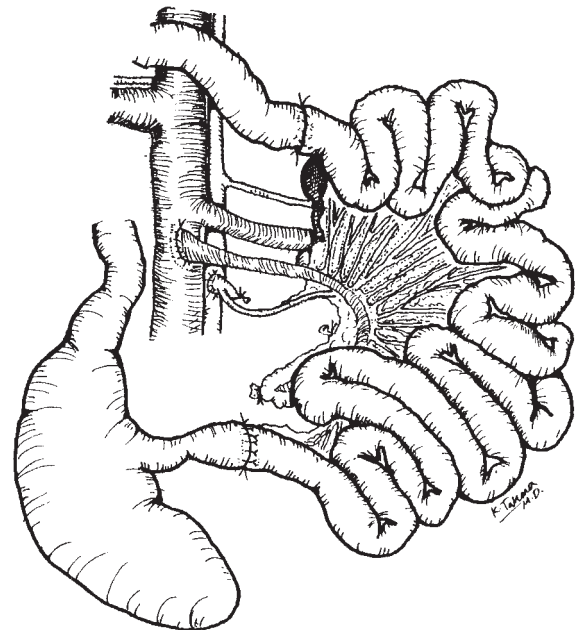


Fig. 1B Orthotopic model

**Table 1** Different susceptibilities to posttransplant events in allo-small intestinal transplantation between HIT and OIT

	Acute rejection <sup>15</sup> (5 days)	Chronic rejection <sup>25</sup> (90 days)	Muscle thickness <sup>23</sup> (90 days)	Muscle contractility <sup>28</sup> (90 days)	Permeability <sup>15</sup> (<4 week)
HIT	Mild	Severe	Severe	Poor	High
OIT	No	Moderate	Mild	Well	Low

HIT, heterotopical intestinal transplantation; OIT, orthotopic intestinal transplant.

the recipients are the same as in HIT. The operation step, which differs from HIT, consists of resection of the recipient's small intestine by ligatures of the mesenteric vessels. Then anastomosis of the oral end of the graft to the duodenum of the recipient is accomplished by an end-to-end procedure using a continuous one-layer suture of bioabsorbable material.

### Surgical Aspect

The data presented in this section are based on our own experiences. Inbred adult male ACI (RT1<sup>a</sup>) and Lewis (RT1<sup>b</sup>) rats weighing between 200–300 g were purchased from the Seiwa experimental farm (Fukuoka, Japan). For fully allogeneic SITx, ACI and Lewis rats were used as recipients and donors, respectively. Lewis rats served for syngeneic combination. No immunosuppressive drug was administered to the recipients.

One-stage OIT requires  $86 \pm 7$  min starting from the beginning of the removal of the donor intestine to the completion of its insertion into the recipients ( $n=8$ ). For HIT,  $55 \pm 4$  min was needed, which was shorter than OIT because of the lack of intestinal anastomoses ( $n=5$ ). Preissner *et al.* [22] reported that the entire OIT operation took about 120 min and long-term survival rate was more than 90% with sufficient microsurgical practice and experience. Zhong *et al.* [16] reported that the operation time needed for HIT and OIT were  $105 \pm 15$  min and  $120 \pm 14$  min, respectively, and that their success rate regarding of HIT (90%) and OIT (86%) were comparable. The technical factors reported previously were similar to those of our institute.

In syngeneic combinations including OIT ( $n=5$ ) and HIT ( $n=3$ ), all recipients were healthy and survived over 60 days with intact grafts. The OIT recipients in fully allogeneic combination died within 7 days due to rejection ( $n=4$ ), whereas 3 of 5 HIT animals could

survive over 30 days with rejected grafts. Although HIT grafts, especially segmental grafts, are severely rejected, they often become encapsulated and do not lead to recipient death [18]. The rats with rejected orthotopic grafts develop intestinal obstruction, which lead to severe dehydration, malnutrition, profound weight loss, and perforations. On the other hand, the rats with heterotopically transplanted grafts can maintain a normal intake of fluids, electrolytes, and nutrients via their native intestine, which was left intact.

The main advantage of HIT is to avoid intestinal anastomoses. The complications in intestinal anastomoses are most commonly observed in OIT, especially in fully allogeneic SITx. Especially, volvulus and distal anastomotic obstruction have been frequently reported [13]. These complications were thought to be immunologic complications rather than technical complications because they were commonly seen in lightly immunosuppressed animals and high-responder combinations [13].

Although the postoperative care of rats having undergone OIT is simple, a problem associated with HIT is that the maintenance of the stomas can be extremely complicated. In the HIT rats lose large amounts of fluid through the stomas. The early postoperative period, the transplanted intestinal lumen becomes filled with mucous secretion that needs to be irrigated out in order to prevent excessive dilatation [20, 21]. Moreover, HIT recipients need to be housed individually to prevent stomal cannibalism [22].

### Immunological Aspects

**Assessment of graft rejection.** The diagnosis of graft rejection is very important. When the transplanted grafts are acutely rejected, OIT models lead to the recipient's death. However, HIT grafts often do not impair recipient survival, as mentioned before. As it is

hard to determine graft rejection in surviving recipients in HIT models, it is widely accepted that graft survival could be diagnosed by clinical signs, palpation of the graft for induration, and examination of the stomas pallor and stomal closure [18–21]. This approach is likely to be very subjective, but no significant difference was seen between 2 method in making diagnosis of graft rejection (HIT;  $5.0 \pm 0.71$  days versus OIT;  $5.8 \pm 0.84$  days,  $P=0.07056$ , Student's *t* test). For pathologic studies, sequent biopsies taken from the ileostomy at different time points are available in the HIT model [5–8]. An endoscopic approach for the transplanted intestine is also possible in the HIT model, which is reported to be effective for early detection of rejection [9].

**Morphological changes.** Grant *et al.* [15] compared the onset of rejection using semiallogeneic combinations (Lewis-BN F1 to Lewis). Although untreated HIT grafts on POD 5 showed early and mild rejection with blunted villi and decreased numbers of goblet cells, OIT grafts demonstrated a normal appearance on POD 5 and present mild lymphocyte infiltration and sloughing of villi on POD 7. Histological evidence of acute rejection appeared earlier in HIT than in OIT.

Chronic rejection processes produced a further increase in the thickness of longitudinal and circular muscle layers. Heeckt *et al.* [23] measured the thickness of the graft's muscularis externa due to hyperplasia and hypertrophy using immunohistochemical staining with rhodamine-labeled phalloidin. They used ACI to Lewis combinations and gave 15 mg/kg of cyclosporin A (CyA) intramuscularly (POD0–6 daily, POD7–28 every other day). The muscular thickness measured on POD 90 were  $278 \pm 26.6 \mu\text{m}$  in OIT and  $456 \pm 50 \mu\text{m}$  in HIT, respectively. Thus, hyperplasia and hypertrophy of the muscularis externa were more pronounced in heterotopic grafts. They also reported microscopical findings of hematoxylin-eosin-stained cross sections of the grafts. The OIT grafts showed only moderate signs of inflammation in the crypts and sometimes a slight blunting of the villi. However, HIT grafts showed severe mucosal atrophy with intact epithelium but also expressed a marked loss of villous height.

Oral feedings can stimulate tropic hormones for mucosal growth [16], and provide nutrients for enterocytes [18]. Mucosal atrophy seen in the heterotopic allografts is most likely due to the lack of intraluminal trophic factors [24, 25]. In HIT grafts, it might be difficult for mucosa to regenerate against the insults of

rejections. Actually, it has been reported that the proliferative effects of hepatocytes under allograft rejection ameliorate the outcome of hepatic graft, since this regenerative potential can compensate for and protect rejected cells [26, 27]. It is likely that a similar explanation is valid for SITx.

**Intraluminal Bacteria.** It has been reported that bacterial translocation and the development of sepsis after small bowel transplantation may be promoted by immunological damage to the intestinal mucosa or by quantitative and qualitative changes in intestinal microflora [28, 29]. Price *et al.* [28] described a very interesting phenomenon: an overgrowth of pathogenic organisms occurs following rat heterotopic small bowel transplantation, with this overgrowth in the heterotopic graft returning to a normal bacterial profile after orthotopic transposition at 14 days following surgery. These findings suggest that early interposition of a small bowel graft into an orthotopic position may prevent an alteration in the small bowel ecology toward potentially pathogenic organisms capable of translocation. They also demonstrated that rejection and GVHD are associated with shifts in intestinal microflora toward potentially pathogenic organisms and that bacterial translocation into recipient tissues poses a major threat for the development of sepsis [29].

## Functional Aspect

The transplanted graft needs to efficiently digest and absorb a variety of nutrients in order to maintain life. Although the mucosa has a remarkable ability to regenerate, the rejection episodes are stored within the vessels, intestinal muscularis, and enteric nerve system [30]. Some reports have focused on the enteric nerve system and intestinal muscularis in HIT and OIT.

**Smooth muscle function.** Heeckt *et al.* [30] investigated alterations in the intestinal smooth muscle function of chronically rejected grafts using an ACI to Lewis combination treated with CyA, as mentioned before. Mechanical smooth muscle activity can be assessed by stimulation by bethanecol. Chronically rejected allograft muscles exhibited a marked decrease in contractile force compared to normal rat intestine. However, HIT grafts demonstrated less contractility and less response to chemical stimulation than did OIT. Mean  $EC_{50}$  values were determined as the concentration needed to generate 50% of the maximal response. Mean  $EC_{50}$  values in HIT were greater than those in OIT (50 mM

and 13.3 mM respectively).

**Graft intestine permeability (barrier function).** Grant *et al.* [15] studied gut barrier function using intestinal permeability to  $^{51}\text{Cr}$ -EDTA urinary excretion of  $^{51}\text{Cr}$ -EDTA. They gave one ml of  $^{51}\text{Cr}$ -EDTA by gavage after OIT or by catheter through the proximal stoma after HIT. Then the 24-hours urinary excretion of  $^{51}\text{Cr}$ -EDTA was measured. Normally the gastrointestinal tract is impermeable to  $^{51}\text{Cr}$ -EDTA. Once  $^{51}\text{Cr}$ -EDTA entered the circulation, it is rapidly cleared by glomerular filtration and can be easily quantified in urine. They demonstrated that intestinal permeability was consistently higher after HIT than after OIT in both syngeneic and allogeneic combinations for 4 weeks after SITx. Although heterotopic grafts suffer from a lack of luminal nutrition, which has been shown to be essential in maintaining normal mucosal function, they represent an important experimental group.

## Conclusion

We reviewed previous literature regarding the 2 different types of SITx: OIT and HIT. Although HIT models do not represent the physiologic state of small intestinal function, HIT models are used for investigations of immunologic reactions such as rejection and graft-versus-host reaction. As well, the HIT model represents a higher survival rate and involves a simple technique. In contrast, the OIT model is suitable for preclinical studies, including studies of graft function and absorption capability under normal physiologic conditions and in interaction with immunologic reactions. Furthermore, graft failure leads to the recipient's death, providing a well defined, objective marker of barrier and absorptive functions.

It has been shown that OIT models are advantageous as intraluminal nutrients, and that intestinal barrier function and the delayed onset of rejection in OIT rats suggest that nutrients and other factors in the succus entericus are important for the maintenance of intestinal graft function.

**Acknowledgment.** We are very grateful to Dr. A.N. Balamurugan, University of Pittsburgh, for his critical reading of our manuscript.

## References

- Monchik GJ and Russel PS: Transplantation of small bowel in the rat: Technical and immunological considerations. *Surgery* (1971) **70**, 693-702.
- Stauffer U: The present state of small bowel transplantation in animal research and in man. *Z Kinderchir* (1977) **22**, 241-248.
- Thiede A and Deltz E: Morphological reaction in transplanted small intestines using immunogenetically defined rat strain combinations. *Langenbecks Arch Chir* (1978) **346**, 119-127.
- Kort WJ, Westbroeck DL, MacDicken I and Lameijer LD: Orthotopic total small bowel transplantation in the rat. *Eur Surg Res* (1973) **5**, 81-89.
- Bakonyi Neto A, Ricordi C, Feo CF, Porcu A, Misiakos EP, Gandia C, Ruiz P, Bertho M, Carreno M, Esquenazi V, Miller J and Tzakis AG: Correlation between allograft survival and chimeric state after bone marrow infusion in rat small bowel transplantation. *Pediatr Transplant* (1999) **3**, 67-73.
- Bakonyi A, Bertho M, Ruiz P, Misiakos EP, Carreno M, Faria W, Sommariva A, Interardi L, Miller J, Ricordi C and Tzakis AG: Donor and recipient pretreatment conditioning with nonlethal radiation and antilymphocyte serum improves the graft survival in a rat small bowel transplant model. *Transplantation* (2001) **27**, 983-988.
- Nakao A, Kobayashi E, Sun DS, Yoshino T and Tanaka N: Impact of tacrolimus and bone marrow augmentation on intestinal allograft survival and intragraft cytokine expression in rats. *J Med* (2001) **32**, 207-230.
- Guo WH, Tian L, Yuen ZW, Chan KL, Wo JY, Nicholls G, Dallman M and Tam PK: Recipient FK506 pretreatment regimens in rat small bowel transplantation: Allograft survival, function, and systemic infection. *J Pediatr Surg* (2000) **35**, 1600-1605.
- Saito T, Kobayashi E, Toyama N, Fujimura A and Miyata M: Endoscopic findings in transplanted allo-intestine of rats after discontinuance of immunosuppressive agent. *J Gastroenterol* (1998) **33**, 336-342.
- Tanabe M, Murase N, Demetris AJ, Hoffman RA, Nakamura K, Fujisaki S, Galvao FHF, Todo S, Fung J and Starzl TE: The influence of donor and recipient strains in isolated small bowel transplantation in rats. *Transplant Proc* (1994) **26**, 4325-4332.
- Ogino Y, Kobayashi E and Fujimura A: Comparison of cyclosporin A and tacrolimus concentrations in whole blood between jejunal and ileal transplanted rats. *J Pharm Pharmacol* (1999) **51**, 811-815.
- Murase N, Ye Q, Nalesnik MA, Demetris AJ, Abu-Elmagd K, Reyes J, Ichikawa N, Okuda T, Fung J and Starzl TE: Immunomodulation for intestinal transplantation by allograft irradiation, adjunct donor bone marrow infusion, or both. *Transplantation* (2000) **70**, 1632-1641.
- Murase N, Demetris AJ, Woo J, Tanabe M, Furuya T, Todo S and Starzl TE: Graft-versus-host disease after Brown Norway to Lewis and Lewis to Brown Norway rat intestinal transplantation under FK506. *Transplantation* (1993) **55**, 1-7.
- Nakao A, Nalesnik MA, Azhipa O, Ishikawa T, Abu-Elmagd K, Starzl TE and Noriko Murase: Immunomodulation of intestinal transplantation: Antilymphocyte serum donor pretreatment vs ex vivo graft irradiation. *Transplant Proc* (2001) (in press)
- Grant D, Zhong R, Hurlbut D, Garcia B, Chen HF, Lamont D, Wang PZ, Stiller C and Duff J: A comparison of heterotopic and orthotopic intestinal transplantation in rats. *Transplantation* (1991) **51**, 948-954.
- Zhong R, Grant D, Sutherland F, Wang PZ, Chen HF, Lo S, Stiller C and Duff J: Refined technique for intestinal transplantation in the rat. *Microsurgery* (1991) **12**, 268-274.
- Deltz E and Thiede A: Experimental transplantation of small intestine: Microsurgical techniques and their applicability in research; in *Handbook of Microsurgery*, Olszewski WL ed, vol 2. CRC Press, Boca Raton, Florida (1984) pp 419-429.
- Deltz E and Thiede A: Microsurgical technique for small intestine

- transplantation; in *Microsurgical Models in Rats for Transplantation Research*, Thiede A, Deltz E, Engemann R and Hamelmann H eds, Springer-Verlag, Heiderberg (1985) pp 51–55.
19. Lee KKW and Schraut WH: Small-bowel transplantation in the rat. Graft survival with heterotopic vs orthotopic position; in *Small Bowel Transplantation. Experimental and Clinical Fundamentals*, Deltz E, Thiede A and Hamelmann H eds, Springer-Verlag, Heiderberg (1986) pp 7–13.
  20. Lee KKW and Schraut WH: Experimental models of small bowel transplantation; in *Small Bowel Transplantation*, Grant D and Wood WFM eds, Edward Arnold, Suffork (1994) pp 9–17.
  21. Miyauchi T, Ishikawa M, Tashiro S, Hisaeda H, Nagasawa H and Himeno K: Effect of donor-specific splenocytes via portal vein and FK506 in rat small bowel transplantation. *Transplantation* (1998) **65**, 27–32.
  22. Preissner WC, Schroeder P, Gundlach M, Liedgens P, Schroeder E and Deltz E: Microsurgical techniques of heterotopic and orthotopic small-bowel transplantation in rat; in *Small Bowel Transplantation. Experimental and Clinical Fundamentals*, Deltz E, Thiede A and Hamelmann H eds, Springer-Verlag, Heiderberg (1986) pp 7–13.
  23. Heeckt PF, Halfter WM, Schurer B, Schraut WH, Begger HG and Bauer AJ: Heterotopic intestinal transplantation aggravates the insult of chronic rejection. *Transplantation* (1998) **65**, 354–362.
  24. Sagor GR, Chatei MA, Al-Mukhtar MY, Wright NA and Bloom SR: Evidence for a humoral mechanism after small intestinal resection: Exclusion of gastrin but not enteroglucagon. *Gastroenterology* (1983) **84**, 902–906.
  25. Steiner M, Bourges HR, Freedman LS and Gray SJ: Effects of starvation on the tissue composition of the intestine in the rat. *Am J Physiol* (1968) **215**, 75–77.
  26. Hohnke C, Lee KS, Otani Y, Hofer M and Lie TS: The graft's own regenerative potential suppresses rejection of hepatic transplants. *Transplant Proc* (1987) **19**, 1080–1081.
  27. Ikegami T, Nishizaki T, Uchiyama H, Kakizoe S, Yanaga K and Sugimachi K: Deletion variant of hepatocyte growth factor prolongs allograft survival after liver transplantation in rats. *Surgery* (1999) **125**, 602–607.
  28. Price BA, Cumberland NS, Clark CL, Pockley AG, Lear PA and Wood RF: The effect of rejection and graft-versus-host disease on small intestinal microflora and bacterial translocation after rat small bowel transplantation. *Transplantation* (1993) **56**, 1072–1076.
  29. Price BA, Cumberland NS, Clark CL, Pockley AG and Wood RF: Evidence that orthotopic transposition following rat heterotopic small bowel transplantation corrects overgrowth of potentially pathogenic bacteria. *Transplantation* (1996) **61**, 649–651.
  30. Heeckt PF, Lee KKW, Halfter WM, Schraut WH and Bauer AJ: Functional impairment of enteric smooth muscle and nerves caused by chronic intestinal allograft rejection regresses after FK 506 rescue. *Transplantation* (1995) **59**, 159–164.