

Original Article

Therapeutic Effects of Azathioprine in Combination with Low-dose Prednisolone in Patients with Intractable Autoimmune Hepatitis Type 1

Tatsuo Takenami, Kohsaku Sakaguchi*, Mamoru Nishimura, Yasuhiro Miyake, Manabi Miyashita, Masako Terao, Akiko Fujiwara, and Takao Tsuji

Department of Medicine and Medical Science, Okayama University Graduate School of Medicine and Dentistry, Okayama 700-8558, Japan

This study evaluated the effects of azathioprine in combination with low-dose prednisolone in the management of patients with intractable autoimmune hepatitis. Thirteen patients with intractable autoimmune hepatitis who had an incomplete or arrested response to conventional prednisolone therapy, or who relapsed during prednisolone maintenance therapy were additionally administered 50 or 100 mg/day of azathioprine in combination with prednisolone. This regimen reliably induced complete remission in 12 of 13 patients, and these 12 remained in remission during the follow-up period with maintenance therapy of 50 mg/day of azathioprine in combination with 5 mg/day of prednisolone. The findings of the current study indicate that the azathioprine and low-dose prednisolone combined therapy may offer a satisfactory alternative therapy for patients with intractable autoimmune hepatitis who have an incomplete or arrested response to conventional prednisolone therapy, or who relapse during prednisolone maintenance therapy.

Key words: autoimmune hepatitis, azathioprine, prednisolone

Autoimmune hepatitis (AIH) is a chronic necroinflammatory liver disorder characterized by circulating autoantibodies and a high serum immunoglobulin (Ig) G level. Prednisolone (PSL) therapy, which has been the primary treatment option for AIH, is effective in inducing clinical, biochemical, and histological remission in most patients with autoimmune hepatitis [1-3]. However, some patients show deterioration despite conventional prednisolone therapy, or relapse after the induction of remission even if the prednisolone maintenance therapy is continued [2, 3]. These patients usually require higher than conventional doses of prednisolone to control inflammatory activity [2]. However,

the long-term administration of high doses of prednisolone might be associated with serious toxic effects [2]. Consequently, in therapy for patients with intractable autoimmune hepatitis, the administration period and dosage of prednisolone are decisive factors regulating therapeutic performance.

Azathioprine alone or in combination with prednisolone has been used for patients with autoimmune hepatitis in initial treatment [1, 2, 4], or for patients relapsing during prednisolone therapy [5]. Azathioprine might be advantageous for patients who are deteriorating despite treatment with high doses of prednisolone. However, the ability of azathioprine in combination with low-dose prednisolone to induce and maintain remission in patients with intractable autoimmune hepatitis has not been fully studied.

It is desirable to find a better regimen for the long-

term management of patients with intractable autoimmune hepatitis. Also, sophisticated therapeutic guidelines for achieving a maximal effect with a minimal adverse drug reaction must be established. The present study evaluated the therapeutic effects of azathioprine in combination with low-dose prednisolone in the management of patients with intractable autoimmune hepatitis type 1, who had an incomplete or arrested response to conventional prednisolone therapy, or who relapsed during prednisolone maintenance therapy.

Materials and Methods

Patients. Forty-one patients (2 males and 39 females, mean age; 51.8 ± 14.0 years) with autoimmune hepatitis type 1 were initially treated with prednisolone (mean dose; 29.8 ± 8.2 mg/day, median dose; 30 mg/day, range; 15–40 mg/day) in our hospital. All patients were seronegative for hepatitis B surface antigen (HBsAg), anti-hepatitis B core antibody (anti-HBc), anti-hepatitis C virus antibody (HCV Ab), and hepatitis C virus-ribonucleic acid (HCV-RNA) detected by polymerase chain reaction after reverse transcription (RT-PCR). All met the provisional criteria for the diagnosis of definite or probable autoimmune hepatitis [6]. The patients underwent diagnostic peritoneoscopic liver biopsies. The liver specimens were evaluated for histological activity and fibrosis according to the criteria of Ishak *et al.* [7], and their histological gradings and stagings were determined.

Of the 41 patients, 32 (78.0%) entered clinically and biochemically complete remission during the initial prednisolone treatment. For the purpose of this study, "complete remission (CR)" was defined as the induction of a normalization of serum alanine aminotransferase (ALT) (≤ 40 IU/l) during the initial treatment, and sustained normal levels of ALT during the maintenance therapy. Unfortunately, 8 (25.0%) of 32 patients who satisfied the criteria of complete remission relapsed when the dose of prednisolone was reduced. A "relapse" of hepatitis was defined as an increase in serum ALT levels above the normal value after the induction of complete remission. Seven (17.1%) patients had a "partial response (PR)", which was defined as a reduction of serum ALT levels to less than one-half of the pretreatment value during the initial treatment, and sustained abnormal ALT levels greater than the upper normal limit. Two (4.9%) of 41 patients showed a "nonresponse (NR)" to the conventional prednisolone treatment, which was

characterized as no significant change in ALT levels during the treatment.

Azathioprine was additionally administered to 2 patients who showed a nonresponse, 5 of 7 patients who showed partial remission, and 6 of 8 who relapsed during the maintenance therapy with prednisolone after the remission. The clinical, laboratory, and histological features of the 13 patients who received azathioprine in combination with prednisolone are shown in Table 1. These features of the 13 patients did not differ from those of patients who showed a complete response to the conventional prednisolone therapy. Informed consent was obtained from all patients.

Azathioprine and low-dose prednisolone combined therapy. Combined therapy of azathioprine and low-dose prednisolone denotes treatment with azathioprine in combination with prednisolone administered at lower than the conventional dose to induce and maintain remission in patients with intractable autoimmune hepatitis who had an incomplete or arrested response to conventional prednisolone therapy, or who relapsed during the prednisolone maintenance therapy. Two patients who showed a nonresponse to the prednisolone therapy were additionally administered 100 mg/day of azathioprine in combination with prednisolone. Also, 4 and 1 patient who showed partial remission were additionally administered 100 or 50 mg/day of azathioprine, respectively. Six patients who relapsed during the maintenance therapy with prednisolone also additionally received 50 mg/day of azathioprine.

The thirteen patients consented to a reduction in the prednisolone dose, after being in remission with the initial doses of azathioprine and prednisolone. After the reduction in the prednisolone dose to 5 mg per day, the doses of azathioprine were reduced to 50 mg per day. Patients undergoing dosage adjustments were monitored by testing serum samples.

Results

The azathioprine and low-dose prednisolone combined therapy was attempted in 7 patients (Cases 1–7) who showed a nonresponse or partial response to the prednisolone therapy, and 6 patients (Cases 8–13) who relapsed during the prednisolone maintenance therapy (Table 2). In the 7 patients showing an incomplete or arrested response to conventional therapy and the 6 patients who relapsed, the mean dose of prednisolone in

Table 1 The clinical, laboratory and histological features of patients who received azathioprine in combination with prednisolone

Case	Age	Sex	AST (IU/l)	ALT (IU/l)	IgG (mg/dl)	ANA	ASMA	HLA-DR	AIH score	Histology Grading	Staging
Nonresponse											
1	62	F	667	1,143	3,940	× 2,560	× 160	2, 6	16	2	3
2	50	F	305	456	4,079	× 2,560	× 160	4, 6	17	9	3
Partial remission											
3	28	F	100	83	3,830	× 320	× 640	n.t.	18	11	5
4	31	M	122	291	2,422	× 640	× 40	1, 2	14	7	2
5	57	F	220	171	2,133	× 40	(-)	4, 6	15	11	3
6	55	F	109	150	2,284	× 2,560	× 40	4,15	18	6	3
7	48	F	962	994	1,930	× 1,280	× 640	4, 8	15	9	3
Relapse											
8	41	F	253	237	4,196	× 1,280	× 640	4, 8	17	11	3
9	53	F	48	27	5,014	× 160	× 320	2, 4	14	9	4
10	42	F	124	129	2,682	× 640	(-)	4, 6	15	11	5
11	18	F	255	213	6,582	× 2,560	× 640	1, 9	14	12	4
12	47	F	200	262	2,409	× 160	(-)	4,12	17	11	5
13	41	F	592	929	1,724	× 40	(-)	2, 4	17	15	2

AIH score, scores are determined by the scoring system of the International Autoimmune Hepatitis Group (1999) [6]; ALT, alanine aminotransferase; ANA, anti-nuclear antibody; ASMA, anti-smooth muscle antibody; AST, aspartate aminotransferase; Histology, histological gradings and stagings are determined by the criteria of Ishak *et al* [7].

Table 2 The dose of medications in the combined azathioprine (AZP) and low-dose prednisolone (PSL) therapy, and the efficacy of the therapy

Case No	Initiation dose of PSL		Before the additional administration of AZP			Azathioprine and prednisolone combined therapy						Efficacy	
						Initiation dose		Maintenance dose		Duration (year)	Recent data		
	PSL (mg/day)	PSL (mg/day)	ALT (IU/l)	PSL (mg/day)	AZP (mg/day)	PSL (mg/day)	AZP (mg/day)	ALT (IU/l)	IgG (mg/dl)				
Non-response													
1	40	40	273	40	100	5	50	8.1	32	1692	CR		
2	40	35	478	35	100	5	50	4.1	14	1438	CR		
Partial response													
3	30	12.5	122	30	100	5	50	5.3	31	1255	CR		
4	30	15	226	15	100	5	50	4.4	56	2965	PR		
5	30	10	171	10	50	5	50	3.1	15	1025	CR		
6	30	20	76	20	100	5	50	2.3	21	1399	CR		
7	40	35	203	35	100	5	50	2.4	18	1482	CR		
Relapse													
8	40	5	168	5	50	2.5	50	7.2	26	1965	CR		
9	20	2.5	394	5	50	5	50	3.4	13	1873	CR		
10	20	7.5	917	5	50	5	50	5.1	15	1383	CR		
11	40	5	105	5	50	5	50	3.6	18	1649	CR		
12	30	5	104	30	50	5	50	2.9	16	1123	CR		
13	40	15	380	10	50	5	50	2.4	12	1494	CR		

ALT, alanine aminotransferase; CR, complete remission; PR, partial remission, which are defined in the text.

the conventional regimen using prednisolone alone before the additional administration of azathioprine was 24 ± 12 mg/day (median dose 20 mg/day, range 10–40 mg/day) and 6.7 ± 4.4 mg/day (median dose 5 mg/day, range 2.5–15 mg/day), respectively, which could not control the disease activities.

Additional administration of azathioprine in combination with prednisolone reliably induced complete remission in 2 patients who showed a nonresponse to conventional prednisolone therapy, and in 4 of 5 patients showing partial remission. In these patients, the mean doses of azathioprine and prednisolone during the initial treatment of azathioprine and prednisolone combined therapy were 93 ± 19 mg/day (median dose 100 mg/day, range 50–100 mg/day) and 26 ± 11 mg/day (median dose 30 mg/day, range 10–40 mg/day), respectively. Also, in 6 patients who relapsed during the prednisolone maintenance therapy, complete remission was achieved by additionally administering 50 mg/day of azathioprine in combination with prednisolone (median dose 5 mg/dl, range 5–30 mg/day).

The regimen of an additional administration of azathioprine in combination with prednisolone induced a sustained remission. These patients did not relapse during the follow-up period (mean duration 4.2 ± 1.8 years, median 3.6 years, range 2.3 to 8.1 years) with maintenance therapy using 50 mg of azathioprine in combination with only 5 mg of prednisolone. The maintenance dose of prednisolone in the combined therapy was lower than that in the regimen using prednisolone alone before the additional administration of azathioprine.

Since many patients declined a liver biopsy when they were asymptomatic and showed normal liver-function, we could not be certain that all the patients had histological remission. Histological liver examinations were performed in 3 patients (Case 2, 10, and 13) during remission (Figs. 1, 2 and 3). The liver biopsy specimens obtained before the therapy showed mild to severe portal fibrosis, portal inflammation, and interface hepatitis with lymphocyte infiltration. Histological grading and staging as assessed by the criteria of Ishak *et al.* were 9 and 3 in Case 2, 11 and 5 in Case 10, and 15 and 2 in Case 13, respectively. In the biopsy specimens obtained during remission, histological improvements were observed compared with the biopsy specimens obtained before the therapy. Histological grading and staging of repeat liver biopsy specimens were 1 and 1 in Case 2, 0 and 1 in Case 10, and 2 and 1 in Case 13, respectively.

During the therapy period, none of the 13 patients receiving combined azathioprine and low-dose prednisolone therapy developed serious azathioprine-related or prednisolone-related toxicities.

Discussion

Prednisolone therapy has been standard for autoimmune hepatitis. A nationwide survey in Japan between 1975 and 1984 by the Study Group of Autoimmune Hepatitis found that steroid therapy during the study period was attempted in 66.8% of patients with autoimmune hepatitis, and was effective in 86% of the cases [8]. These results indicate that, although autoimmune hepatitis responds well to prednisolone therapy, an incomplete or arrested response to the therapy occurs in a small number of AIH patients. Also, the nationwide survey revealed that 10 (11%) of 92 patients receiving maintenance therapy with prednisolone after remission later relapse [8].

Failure of the conventional prednisolone regimen to induce a sustained remission suggests a suboptimal response to the treatment. Generally, administration of a higher-than-conventional dose of prednisolone is the most common approach to patients with an incomplete or arrested response to conventional therapy. Also, in patients relapsing during maintenance therapy, the option of increasing the maintenance dose of prednisolone can be exercised. However, although the administration of higher-than-conventional doses of prednisolone might induce and maintain remission, high-dose prednisolone therapy is commonly complicated by serious steroid-related toxicities. Therefore, these patients are candidates for alternative therapies and deserve an opportunity to use azathioprine to control inflammatory activity.

The administration of azathioprine in combination with prednisolone has had success in inducing remission in the initial treatment for autoimmune hepatitis [1, 2]. However, in patients with intractable autoimmune hepatitis showing an incomplete or arrested response to conventional prednisolone therapy, or who relapse during prednisolone maintenance therapy, the treatment strategies remain complex and uncertain, and there is no justification for introducing alternative nonsteroidal regimens or unconventional prednisolone. The use of azathioprine and prednisolone to induce and maintain remission should be redefined.

In the present study, combined azathioprine and

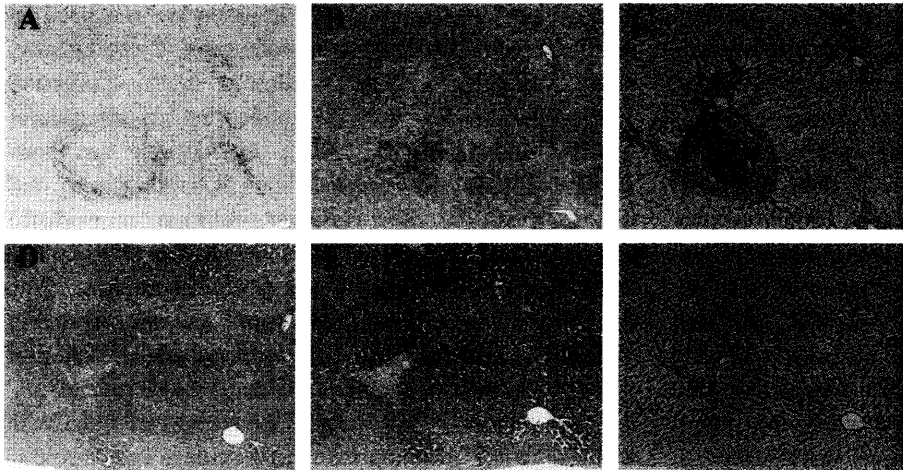


Fig. 1 Liver-biopsy specimens of Case 2 before (A, B, C) and after (D, E, F) the initiation of combined azathioprine and low-dose prednisolone therapy. (A, D, Hematoxylin Eosin stain; B, E, Azan stain; C, F, Reticulin silver impregnation. Original magnification $\times 50$)

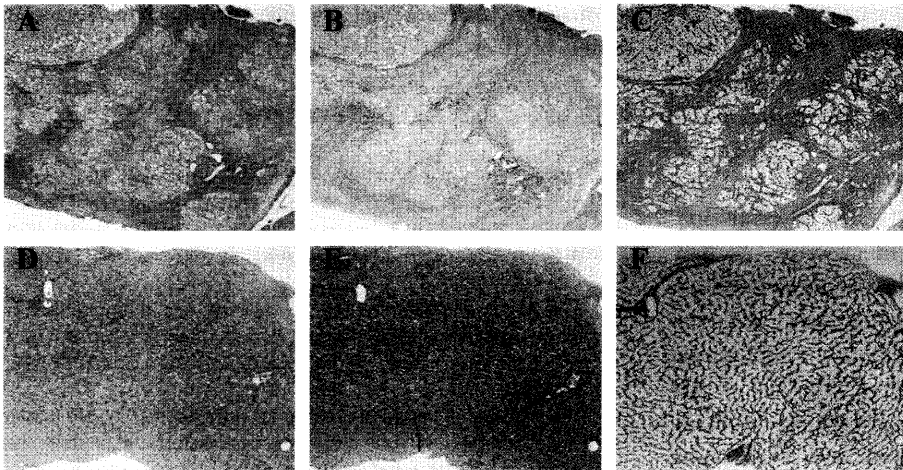


Fig. 2 Liver-biopsy specimens of Case 10 before (A, B, C) and after (D, E, F) the initiation of combined azathioprine and low-dose prednisolone therapy. (A, D, Hematoxylin Eosin stain; B, E, Azan stain; C, F, Reticulin silver impregnation. Original magnification $\times 50$)

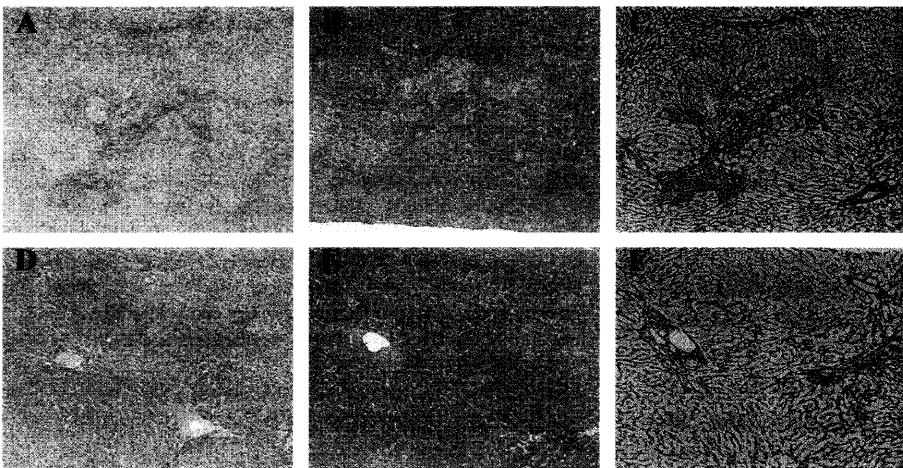


Fig. 3 Liver-biopsy specimens of Case 13 before (A, B, C) and after (D, E, F) the initiation of combined azathioprine and low-dose prednisolone therapy. (A, D, Hematoxylin Eosin stain; B, E, Azan stain; C, F, Reticulin silver impregnation. Original magnification $\times 50$)

low-dose prednisolone therapy was attempted in 7 patients with an incomplete or arrested response to the conventional prednisolone therapy, and in 6 patients who relapsed during the prednisolone maintenance therapy. In 6 of 7 patients with an incomplete or arrested response to conventional prednisolone therapy, complete remission was realized with additional administration of 100 mg/day of azathioprine in combination with prednisolone. Complete remission was maintained by using 50 mg/day azathioprine in combination with 5 mg/day of prednisolone. Also, in patients who had relapsed, complete remission was sustained by additionally administering 50 mg/day of azathioprine in combination with 5 mg/day of prednisolone. The maintenance dose of prednisolone in the combined azathioprine and low-dose prednisolone therapy was lower than the dose of prednisolone in the regimen using prednisolone alone, which could not control the disease activity.

The present findings indicate that the regimen using azathioprine and low-dose prednisolone is effective in controlling the clinical and biochemical manifestations of intractable autoimmune hepatitis patients. Subsequent long-term follow-up has confirmed the safety of the regimen and its efficacy in maintenance of remission. Used together, the 2 agents work in synergy, as they interfere with different stages of the immune pathway. Prednisolone, which has anti-inflammatory and immunosuppressive properties, primarily suppresses activated macrophages to produce interleukin (IL) -1 and IL-2, and interferes with antigen-presenting function, subsequently inhibiting T cell activation and proliferation [9]. Azathioprine, which is converted *in vivo* to its active form, 6-mercaptopurine, is an antimetabolite pro-drug that interferes with nucleic acid synthesis, preventing proliferation of T and B lymphocytes [10]. These different immunosuppressive activities of the 2 agents could theoretically explain the efficacy of combined azathioprine and low-dose prednisolone therapy in patients with intractable autoimmune hepatitis who have had an incomplete or arrested response to protracted prednisolone conventional therapy, or who have relapsed during the prednisolone maintenance therapy.

In a previous study, azathioprine alone was found to play no role in inducing remission in the initial treatment for patients with autoimmune hepatitis [1, 2]. Furthermore, Johnson *et al.* have reported that 60 (87%) of 72 patients with autoimmune hepatitis who had been in complete remission for at least 1 year with prednisolone

alone or in combination with azathioprine remained in remission with a higher dose of azathioprine (2 mg/kg/day) alone, whereas 4 patients showed myelosuppression [11]. The complications of azathioprine include nausea, emesis, and rash [2]. Also, azathioprine has been implicated in theoretical possibilities of teratogenicity and oncogenicity [12, 13]. However, we found no evidence of azathioprine toxicities or carcinogenic side effects. The regimen using azathioprine and prednisolone may allow for a lower dose of both prednisolone and azathioprine in clinical use, with the benefit being a notable reduction in steroid-induced and azathioprine-induced side effects.

In conclusion, the results of the current study indicate that combined azathioprine and low-dose prednisolone therapy may offer a satisfactory alternative therapy for patients with intractable autoimmune hepatitis who have had an incomplete or arrested response to protracted prednisolone conventional therapy, or who have relapsed during prednisolone maintenance therapy.

References

1. Soloway RD, Summerskill WH, Baggenstoss AH, Geall MG, Gitnick GL, Elveback IR and Schoenfield LJ: Clinical, biochemical and histological remission of severe chronic active liver disease: A controlled study of treatments and early prognosis. *Gastroenterology* (1972) **63**, 820-833.
2. Summerskill WH, Korman MG, Ammon HV and Baggenstoss AH: Prednisone for chronic active liver disease: Dose titration, standard dose, and combination with azathioprine compared. *Gut* (1975) **16**, 876-883.
3. Kirk AP, Jain S, Pocock S, Thomas HC and Sherlock S: Late results of the Royal Free Hospital prospective controlled trial of prednisolone therapy in hepatitis B surface antigen negative chronic active hepatitis. *Gut* (1980) **21**, 78-93.
4. Murray-Lyon IM, Stern RB and Williams R: Controlled trial of prednisone and azathioprine in active chronic hepatitis. *Lancet* (1973) **1**, 735-737.
5. Czaja AJ: Low-dose corticosteroid therapy after multiple relapses of severe HBsAg-negative chronic active hepatitis. *Hepatology* (1990) **11**, 1044-1049.
6. McFarlane IG and International Autoimmune Hepatitis Group members: International Autoimmune Hepatitis Group Report: Review of criteria for diagnosis of autoimmune hepatitis. *J Hepatol* (1999) **31**, 929-938.
7. Ishak K, Baptista A, Bianchi L, Callea F, DeGroot J, Gudat F, Denk H, Desmet V, Korb G, MacSween RN, Phillips J, Portmann BG, Poulsen H, Scheuer PJ, Schmid M and Thaler H.: Histological grading and staging of chronic hepatitis. *J Hepatol* (1995) **22**, 696-699.
8. Monna T, Kuroki T and Yamamoto S: Autoimmune hepatitis: The present status in Japan. *Gastroenterology Jpn* (1985) **20**, 260-271.
9. Claman HN: Corticosteroids as immunomodulators. *Ann N Y Acad Sci* (1993) **685**, 288-292.
10. Elion GB: The George Hitchings and Gertrude Elion Lecture. The pharmacology of azathioprine. *Ann N Y Acad Sci* (1993) **685**, 400-407.

11. Johnson PJ, McFarlane IG and Williams R: Azathioprine for long-term maintenance of remission in autoimmune hepatitis. *N Engl J Med* (1995) **333**, 958-963.
12. Silman AJ, Petrie J, Hazleman B and Evans SJ: Lymphoproliferative cancer and other malignancy in patients with rheumatoid arthritis treated with azathioprine: A 20 year follow up study. *Ann Rheum Dis* (1988) **47**, 988-992.
13. Wang KK, Czaja AJ, Beaver SJ and Go VL: Extrahepatic malignancy following long-term immunosuppressive therapy of severe hepatitis B surface antigen-negative chronic active hepatitis. *Hepatology* (1989) **10**, 39-43.