

Case Report

Recanalization 24 Months after Endovascular Repair of a Large Internal Iliac Artery Aneurysm with Use of Stent-Graft

Kotaro Yasui^{a*}, Susumu Kanazawa^a, Hidefumi Mimura^a, Shuichi Dendo^a,
Yoshio Hiraki^a, Hiroyuki Irie^b, and Shunji Sano^b

^aDepartment of Radiology and ^bCardiovascular Surgery,
Okayama University Medical School, Okayama 700-8558, Japan

An 83-year-old man with a large internal iliac artery aneurysm (IIAA) was treated with the use of stent-graft, suggesting successful results at 3, 6, and 12 months after treatment. However, 24-month follow-up computed tomography showed minor peripheral opacification of the IIAA. The patient underwent surgical endoaneurysmorrhaphy. No previous report of long-term recanalization of a satisfactorily thrombosed iliac artery aneurysm at 2 years or more after stent-grafting has been previously reported. Further follow-up studies need to be performed on the present procedure before anyone can confidently recommend it in regard to its long-term safety.

Key words: aneurysm, iliac----stents and prosthesis

Endovascular repair of iliac artery aneurysm using a stent-graft has been described [1, 2]. To our knowledge, there has been no report of long-term (up to or beyond 24 months) recanalization of thrombosed aneurysm following endovascular repair. We discuss in this case report the decision to make complete occlusion of possible collateral vessels when endovascular repair of iliac artery aneurysm is planned, and when long-term effective results are required.

Case Report

An 83-year-old man was noted with an 8-cm left internal iliac artery aneurysm (IIAA) and a 3-cm right common iliac artery aneurysm. These were diagnosed on CT (Fig. 1) as incidental findings during evaluation for benign prostatic hyperplasia. The patient had undergone

right hemicolectomy due to ascending colon cancer. Because of his age and past history, a transluminal procedure using a stent-graft was chosen. Informed consent was obtained for this procedure.

All procedures were performed in the angiography suite with use of both local and epidural anesthesia. The unthrombosed part of the left internal iliac artery aneurysm and parietal branches originating from the aneurysm were demonstrated on pelvic aortogram (Fig. 2) before the procedure. To start with, the left superior gluteal artery, the common channel for the visceral branches, and the left inferior gluteal artery were selectively catheterized. Stainless steel Gianturco embolization coils (Cook, Bloomington, IN, USA) and platinum microcoils (Johnson & Johnson, Warren, NJ, USA) were placed in each artery to preclude retrograde flow into the aneurysm. The second stage required exclusion of the origin of the aneurysm. Placement of a stent-graft from the common iliac artery leading to the external iliac artery was performed. The stent-graft was composed of commercially available polyester fabric (DeBakey Elastic Knit Fabric; Bard

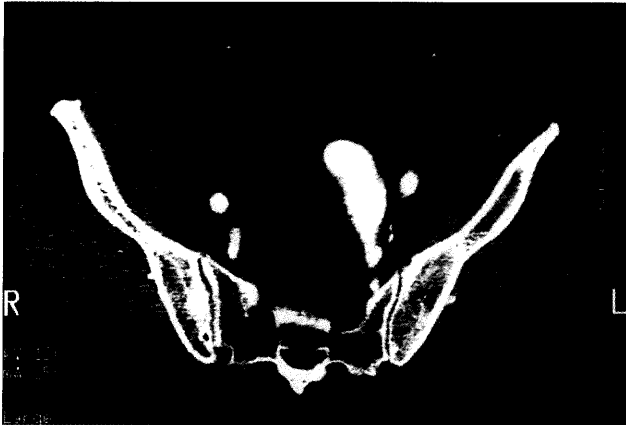

Fig. 1 Pelvic CT shows an 8-cm left internal iliac artery aneurysm with thick mural thrombus.

Vascular Systems Division, Billerica, MA, USA) with modified Z stents (5 sections of 1.5 cm; 7.5 cm in total) of 12-mm-diameter (Cook, Bloomington, IN, USA) sutured to the framework of the stent with use of 3-0 polypropylene sutures (Prolene; Ethicon, Johnson & Johnson, Warren, NJ, USA). The most proximal stent (1.5-cm-long) and half of the most distal one remained bare to prevent stent migration. Since the immediate post-deployment aortogram demonstrated a leak into the aneurysm, we performed post-dilatation with a balloon catheter at the proximal and distal portions of the stent-graft including the covered parts. After post-dilatation of the stent-graft, aortogram (Fig. 3) showed no further leak or presence of collateral vessels.

An intravenous-contrast-material-enhanced CT scan of the pelvis obtained on the seventh postprocedural day demonstrated no contrast opacification within the aneurysm. CT scans obtained at 3 (Fig. 4), 6, and 12 months after the procedure demonstrated continued complete thrombosis of the aneurysm. A CT scan (Fig. 5) at

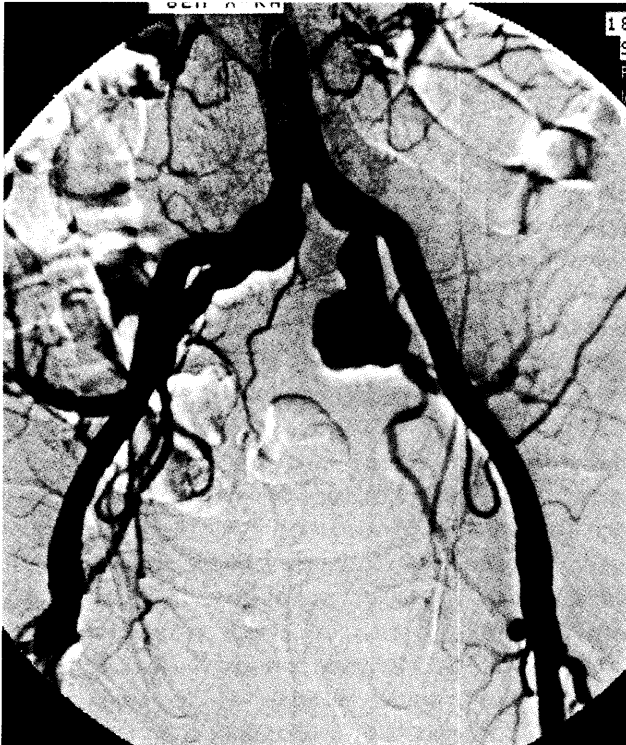


Fig. 2 Unthrombosed part of the left internal iliac artery aneurysm and parietal branches originating from the aneurysm are demonstrated on the pelvic aortogram before the procedure.

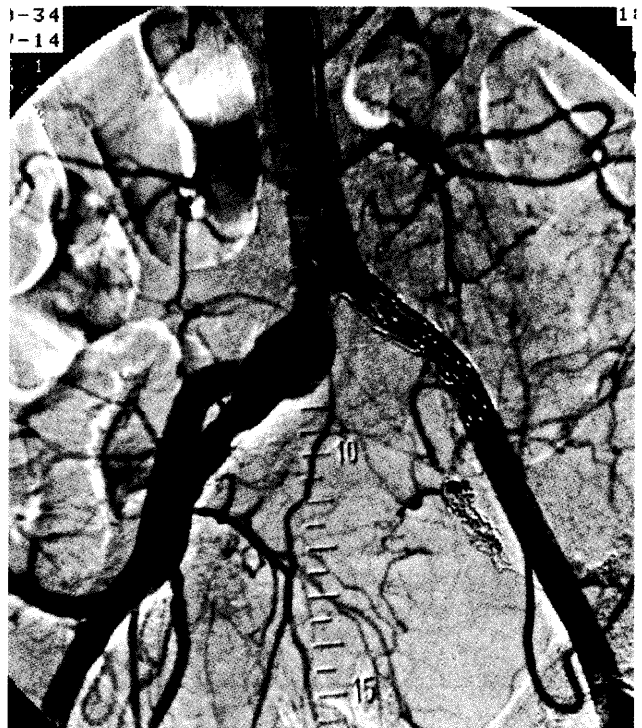


Fig. 3 No evidence of any leak is shown on pelvic aortogram immediately after the procedure for endovascular repair of the left internal iliac artery aneurysm.

24 months after the stenting, however, showed increased aneurysmal size and minor contrast opacifications of the IIAA. Pelvic aortography (Fig. 6), bilateral iliac arteriographies, and left fourth lumbar arteriography were performed to clarify the reason for such opacification in the aneurysm. Endoleak was seen from the left fourth lumbar artery to the left IIAA via the left iliolumbar artery.

The patient underwent operative aneurysmorrhaphy 28 months after stent-grafting. The operation revealed retrograde flow into the aneurysm from the origin of the parietal branch of the left internal iliac artery.

Discussion

The natural history of iliac artery aneurysm is expansion, with a risk of rupture in approximately one-third of the cases [3]. The mean diameter of ruptured iliac artery aneurysms has been reported as 5.6-cm [3]. Current recommended treatment is surgical repair for aneurysms larger than 3 cm in diameter [1]. Endoluminal graft placement is an alternative approach to conventional surgical repair of peripheral aneurysm [4]. Many authors have since investigated the use of intraluminal grafts for treatment of aneurysmal disease [4-7]. The attraction of this relatively newer technique is that it is less invasive, and thereby avoids the need for incision, general anesthesia, and transfusion. Long-term results, however, are not yet fully known [4, 8]. The advantages are particularly important in high-risk surgical candidates because of other co-morbid medical conditions [1, 8].

Because the orifice of the internal iliac artery was involved in the common iliac artery aneurysms in 3 patients, Razavi *et al.* [1] performed transcatheter embolization of the branches of the internal iliac artery before placement of the stent-graft in order to prevent retrograde fill-back of the aneurysm. In our case we were

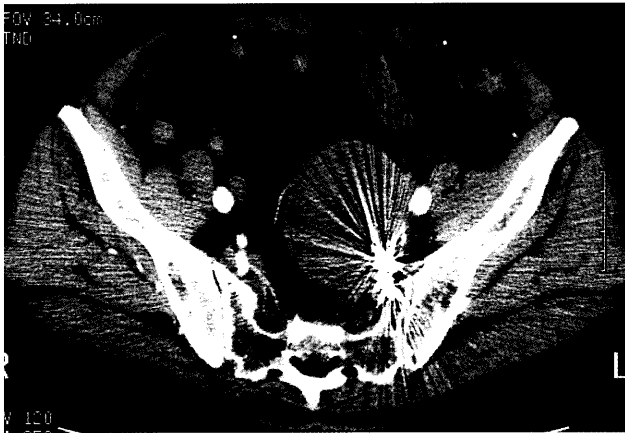


Fig. 4 Pelvic CT scan obtained 3 months after the stent-grafting demonstrates no contrast opacification within the aneurysm.

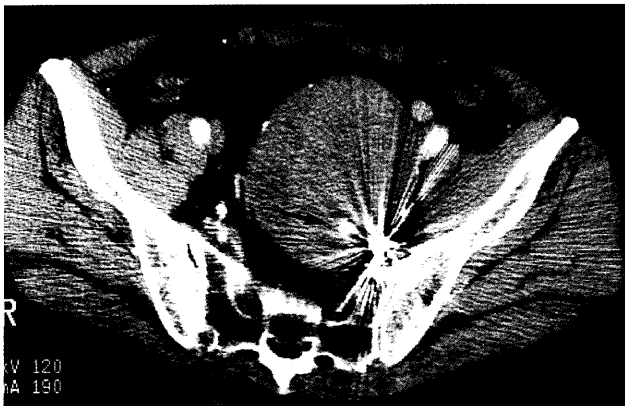


Fig. 5 CT scan 24 months after the stent-grafting shows increased aneurysmal size and minor contrast opacifications (arrow) in the internal iliac artery aneurysm.

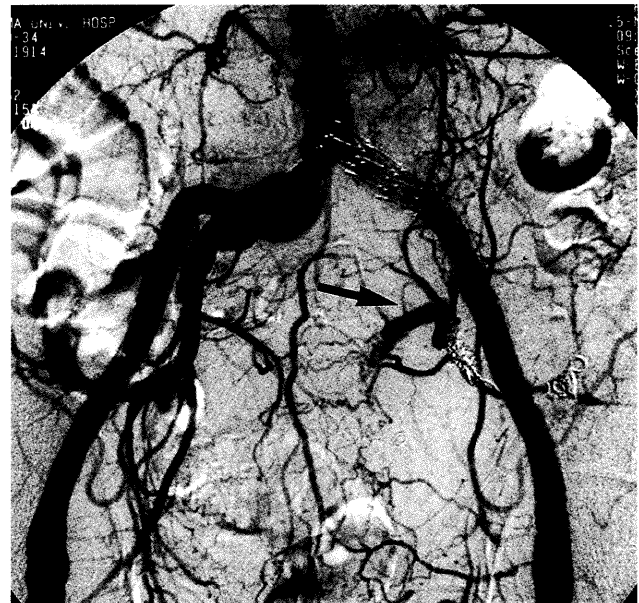

Fig. 6 Pelvic aortogram shows endoleak (arrow) occurring from the left fourth lumbar artery to the left internal iliac artery aneurysm via the left iliolumbar artery.

able to achieve early thrombosis of the aneurysm, which looked solid and continued for over 12 months. However, CT scan at 24 months after stenting showed minor peripheral contrast opacifications of the IIAA. No previous report has described radiological reopacification of supposedly thrombosed iliac artery aneurysm more than 2 years after stent-grafting. Contrast filling of the aneurysm sac after endoluminal repair can transmit aortic arterial pressure to the aneurysm wall and may allow further growth with the potential for rupture [9]. Parsons *et al.* [9] reported that one patient's aneurysm ruptured 17 months after stented endovascular repair. They stated that the precise reasons for rupture in their patient remained unclear. We noted in our situation that the most proximal coil was placed just distal to the iliolumbar artery. This probably allowed retrograde flow through the iliolumbar artery into the branches of the hypogastric artery. We should, with the benefit of hindsight, have placed coils proximal to the orifice of the iliolumbar artery [10], though angiography at the time of stent-graft placement did not then show vessels that would form any collateral pathway to the aneurysm. The reason for recanalization after such a long time remains a mystery. However, this case does suggest to us that collateral vessels can develop 24 months later, even though the aneurysm was kept under control by the endovascular repair up until 24 months. There would in addition, interestingly, appear to be some truth in the impression of Cynamon *et al.* [10] that prograde flow might not have to be obstructed completely during the embolization procedure, because it can prevent retrograde filling of the aneurysm. We agree with their opinion and consider that we should intentionally have incompletely occluded the

most proximal portion of the superior gluteal artery using metallic coils.

Further follow-up studies need to be performed on the present procedure before anyone can confidently recommend it in regard to its long-term safety.

References

1. Razavi MK, Dake MD, Semba CP, Nyman UR and Liddell RP: Percutaneous endoluminal placement of stent-grafts for the treatment of isolated iliac artery aneurysms. *Radiology* (1995) **197**, 801-804.
2. Cynamon J, Marin ML, Veith FJ, Bakal CW, Silberzweig JE, Rozenblit A and Wahl SI: Endovascular repair of an internal iliac artery aneurysm with use of a stented graft and embolization coils. *J Vasc Interv Radiol* (1995) **6**, 509-512.
3. Richardson JW and Greenfield LJ: Natural history and management of iliac aneurysm. *J Vasc Surg* (1988) **8**, 165-171.
4. Rousseau H, Gieskes L, Joffre F, Dube M, Roux D, Soula P, Mnif D, Arrue P and Carre P: Percutaneous treatment of peripheral aneurysms with the Cragg EndoPro System. *J Vasc Interv Radiol* (1996) **7**, 35-39.
5. Vorwerk D, Gunther RW, Wendt G and Schurmann K: Ulcerated plaques and focal aneurysms of iliac arteries: Treatment with non-covered, self-expanding stents. *AJR* (1994) **162**, 1421-1424.
6. Hausegger KA, Cragg AH, Lammer J, Lafer M, Fluckiger F, Klein GE, Sternthal MH and Pilger E: Iliac artery stent placement: Clinical experience with a nitinol stent. *Radiology* (1994) **190**, 199-202.
7. Cragg AH and Dake MD: Percutaneous femoropopliteal graft placement. *Radiology* (1993) **187**, 643-648.
8. Marin ML, Veith FJ, Cynamon J, Panetta TF, Bakal CW, Kerr A and Parodi JC: Transfemoral endoluminal repair of a penetrating vascular injury. *J Vasc Interv Radiol* (1994) **5**, 592-594.
9. Parsons RE, Marin ML, Veith FJ, Parsons RB and Hollier LH: Midterm results of endovascular stented grafts for the treatment of isolated iliac artery aneurysms. *J Vasc Surg* (1999) **30**, 915-921.
10. Cynamon J, Lerer D, Veith FJ, Taragin BH, Wahl SI, Lantin JL, Ohki T and Sprayregen S: Hypogastric artery coil embolization prior to endoluminal repair of aneurysms and fistulas: Buttock claudication, a recognized but possibly preventable complication. *J Vasc Interv Radiol* (2000) **11**, 573-577.