

Case Report

Primary Appendiceal Adenocarcinoma of Colonic Type with Perforating Peritonitis

Hirofumi Noguchi^{a,b*}, Hidenori Kondo^a, and Masami Kondo^a

^aDepartment of Surgery, Kondo Hospital, Okayama 717-0013, Japan, and

^bDepartment of Surgery I, Okayama University Medical School, Okayama 700-8558, Japan

Primary adenocarcinoma of the appendix is rare, especially the colonic type. We report a case of appendiceal adenocarcinoma of colonic type associated with perforating peritonitis after aorto-femoral artery bypass surgery. A 79-year-old woman presented with fever and pain in the right lower abdomen. She had undergone aorto-femoral artery bypass surgery due to arteriosclerosis obliterans 6 months earlier. Abdominal ultrasonography and computed tomography showed a suspected pool of fluid surrounding the artificial vessel and a mass lesion in the upper end of the fluid collection. These findings suggested localized peritonitis due to appendiceal perforation. Emergency laparotomy showed a pool of pus around the artificial vessel and inflamed appendix, which adhered to the surrounding tissue. The mass was excised in combination with an ileocaecal resection, followed by an ileocolic anastomosis. The histological diagnosis was moderately differentiated adenocarcinoma of the appendix, colonic type. The tumour had infiltrated and obstructed the lumen of the orifice of the appendix, which may have caused perforation of the appendix. She was examined at regular periodic follow-ups and no evidence of recurrence or metastasis was noted in the 12-month postoperative period. These findings indicate that, in cases of acute appendicitis, especially with perforation, the possibility of appendiceal adenocarcinoma should be considered.

Key words: appendix, adenocarcinoma, colonic type, perforation, bypass of aorto-femoral artery

P rimary adenocarcinoma of the vermiform appendix is rare, representing 0.2% to 0.5% of all gastrointestinal tumours [1-4] and 4% to 6% of primary malignant appendiceal neoplasms [5, 6]. The colonic type adenocarcinoma is more rare still [3, 7]. Carr *et al.* [8] reported on cases of epithelial noncarcinoid tumours and tumour-like lesions of the appendix using the classification of the World Health Organization (WHO) [9]. In their report, colonic-type adenocarcinomas of the appendix were only 6 cases of 85 patients with car-

cinomas. In general, most patients with colonic type adenocarcinomas of the appendix are not identified until the disease is advanced. The most common clinical presentation is that of acute appendicitis or a palpable abdominal mass [1-3, 6, 8, 10-13]. The diagnosis of carcinoma of the appendix is difficult to make preoperatively due to the lack of definite diagnostic, clinical, sonographic, or radiological findings characteristic of this disease [1, 3, 10, 11, 13-15]. We report here a case of appendiceal adenocarcinoma of colonic type associated with perforating peritonitis after aorto-femoral artery bypass surgery.

Received January 19, 2001; accepted March 2, 2001.

*Corresponding author. Phone: +81-86-235-7259; Fax: +81-86-221-8775
E-mail: hirofumi@cc.okayama-u.ac.jp (H. Noguchi)

Case Report

A 79-year-old woman presented with severe chills and pain in the right lower quadrant of the abdomen. She was admitted to our hospital for further investigation. An aorto-femoral artery bypass had been performed 6 months earlier for arteriosclerosis obliterans (ASO). At the time of the bypass operation, the appendix was soft and slightly enlarged, suggesting chronic appendicitis. Two weeks before admission, she had consulted a regional hospital, complaining of abdominal pain and chills, and was treated with antibiotics.

On the day of admission, there was localized tenderness, particularly over the McBurney's point, and Blumberg's sign was observed in the right lower quadrant of the abdomen. Body temperature was 37.2 °C. An abdominal mass was palpated in the same region. Laboratory tests showed leukocytosis (WBC: 15,300/mm³) and elevation of C-reactive protein (CRP: 13.3 mg/dl). There were no other abnormal values on peripheral blood analysis or serum biochemical analysis.

Abdominal ultrasonography showed a low echoic lesion surrounding the artificial vessel, which was suspected to indicate collection of fluid. In the upper area of this lesion, another low echoic lesion was noted, but the latter was relatively higher than that of the suspected fluid lesion, which continued with the area of the ascending colon.

Abdominal computed tomography (CT) findings revealed a low-density mass, 3-cm in diameter, surrounded by a high density area, in the right pelvic cavity (Fig.

1A). The low-density area surrounding the artificial vessel, as well as the ultrasonographic findings, was suspected to indicate fluid collection (Fig. 1B). These findings suggested localized peritonitis due to appendiceal perforation.

Emergency laparotomy was performed. The appendix was inflamed and adhered to the surrounding tissue, including the ileum, caecum, peritoneum, and artificial vessel, and a pool of pus was accumulated around the artificial vessel and surrounding structures. Through careful dissection, we were able to excise the mass from the vessel. This procedure was combined with ileocaecal resection. Immediately after ileocaecal resection, we opened the enteric canal of the preparation. Carcinoma of the appendiceal orifice was evident. We had previously cut the ileocaecal vessels to dissect lymph nodes along the vessels. We therefore performed an ileocolic anastomosis without additional resection. The peritoneal cavity was washed repeatedly using a large amount of 5,000 ml sterile saline and a closed drain was inserted in order to prevent infection of the artificial vessel.

Gross examination of the excised tissue showed infiltration of adenocarcinoma and obstruction of the lumen of the orifice of the appendix (Fig. 2). The lesion showed an ulcerative and localized lesion, measuring 3.5 × 2.5 cm. Microscopic examination showed replacement of the serosa by necrotic tissue, with blood and fibrin in the perforated lesion. There were inflammatory changes of the ileum and caecum. The tumour was composed of gland-like structures and groups of cells without lakes of mucin or large cysts. The histological

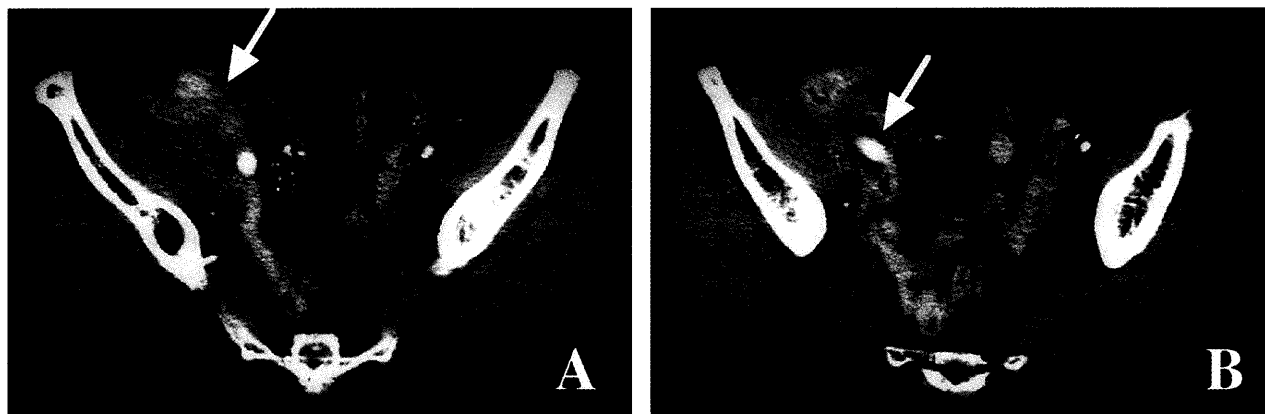


Fig. 1 A, abdominal computed tomography (CT) showing a low-density mass surrounded by an area of high density, in the right pelvic cavity (arrow). B, note the low-density area surrounding the artificial vessel (arrow), which suspected to indicate fluid collection.

diagnosis was moderately differentiated adenocarcinoma, colonic type (Fig. 3A), with adenoma in the part of the tumour terminal (Fig. 3B). The cancer cells infiltrated the wall near the perforated lesion. The regional lymph nodes were negative for metastasis.

The patient had an uneventful postoperative course

and was discharged 41 days after surgery. She was examined at regular periodic follow-ups and no evidence of recurrence or metastasis was noted in the 12-month post-operative period.

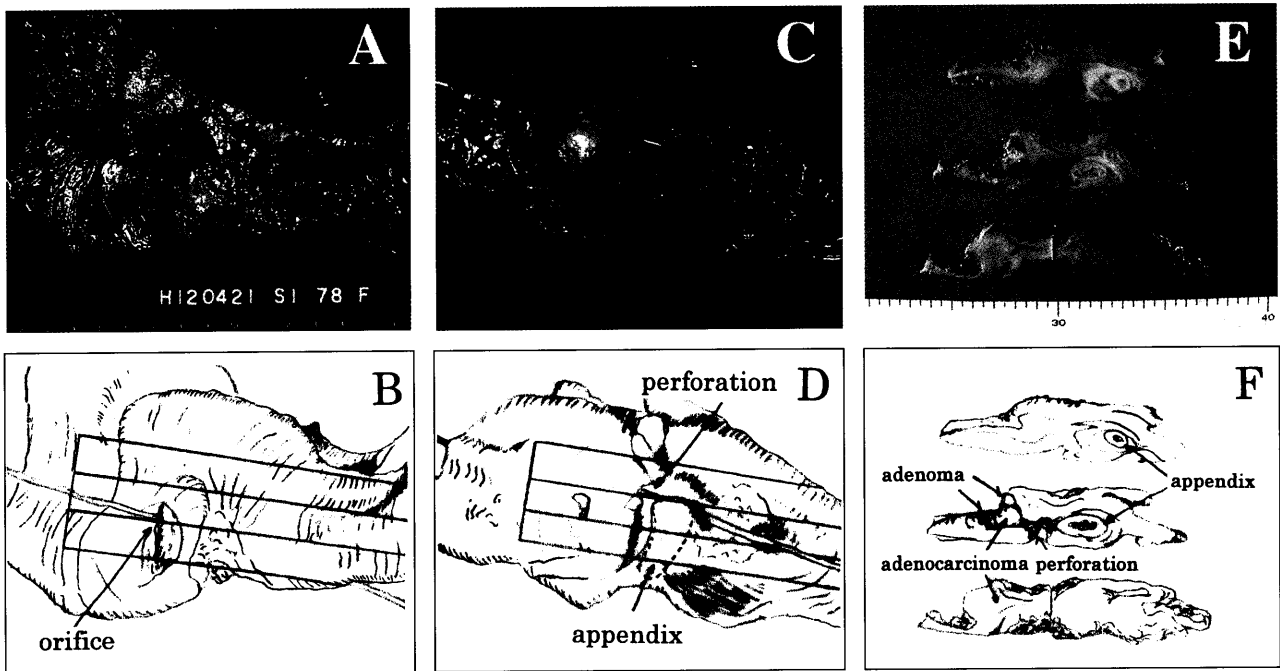


Fig. 2 Macroscopic view and the schema of the excised tissue. A, mucosa side; B, the schema of Fig. 2A; C, serosa side; D, the schema of Fig. 2C; E, cross section of the tumour; F, the schema of Fig. E.

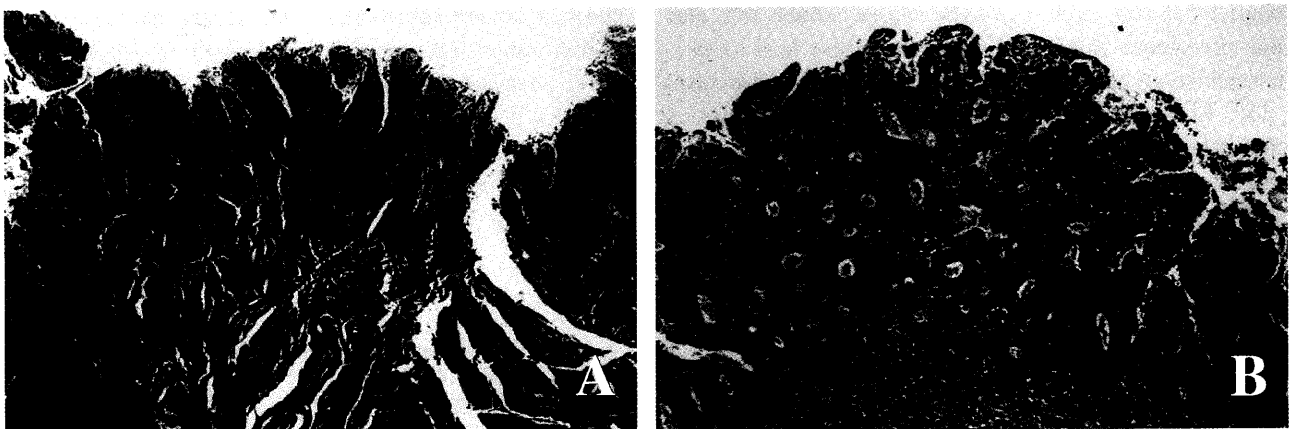


Fig. 3 Microscopic examination of the excised tumour. The histological features are consistent with those of moderately differentiated adenocarcinoma, colonic type (A) and with those of adenoma (B). Magnification, $\times 10$.

Discussion

Primary adenocarcinoma of the appendix is a rare neoplasm, occurring in approximately 0.03% to 0.3% of all surgically removed appendixes [4, 16, 17]. A slight male predominance is reported and the mean age of presentation is in the fifth or sixth decade, with a reported range of 13 to 91 years [8, 18–20]. Epithelial noncarcinoid tumours and tumour-like lesions of the appendix are classified into 5 diagnostic groups based on the WHO criteria [9]: simple mucocoeles, hyperplastic polyps, adenomas, mucinous tumours of uncertain malignant potential (UMP), and adenocarcinomas. Simple mucocoeles account for 6% of the epithelial noncarcinoid tumours and tumour-like lesions, followed in prevalence by hyperplastic polyps, adenomas, mucinous tumours of UMP, and adenocarcinomas (10%, 23%, 15%, and 46%, respectively) [8]. The colonic-type adenocarcinomas of the appendix account for only 3% of the epithelial noncarcinoid tumours and tumour-like lesions [8].

The patient often presents with a right lower quadrant mass, anaemia, or with symptoms and signs suggestive of acute appendicitis [2, 6–8, 10, 21], similar to our patient, and up to 70% of cases are not diagnosed intraoperatively [3, 5, 16]. The symptoms of acute appendicitis are likely due to obstruction of the lumen by the tumour, as in the present case, infiltration by the tumour, superimposed infection of the wall, obstruction of lymphatic channels, obstruction of the vasculature, or invagination [22].

The anatomic peculiarities of the appendix lead to several considerations with regard to appendiceal neoplasms. The vermiform appendix is often deficient in both longitudinal and circular muscle fibres, which not only may predispose to perforation but may also lead to early dissemination or direct invasion of adjacent structures [23]. Mucinous adenocarcinoma, the so-called malignant mucocoele, sometimes ruptures into the abdominal cavity, often resulting in pseudomyxoma peritonei [24, 25]. Although colonic type adenocarcinoma is less likely to perforate than cystadenocarcinoma, perforation and direct extension to adjacent structures may occur early, as noted in our patient [7, 10, 26]. Cerame [27] reviewed cases of adenocarcinoma of the appendix diagnosed in his hospital over a period of 25 years and found perforation of appendiceal carcinomas in 55% of patients, making it the most common perforating carcinoma of the entire gastrointestinal tract [27].

Adenocarcinoma of the appendix, like carcinomas of the colon, spreads via local invasion, lymphatic vessels, and the bloodstream. The most common metastatic location is the peritoneal cavity, followed by the lymph nodes, liver, ovaries, abdominal wall, and lungs [23]. In surgical excision of the colonic type carcinoma of the appendix, extra care is needed because the lesion frequently involves the base of the appendix, occasionally extending into the caecum and causing perforation [27]. Sometimes more extensive resection may be necessary, which could include resection of part of the caecum. Didolkar and Fanous [26] noted that perforation at the tumour site promoted spread. As the appendix originates from lymphatic structures, lymphatic spread occurs easily, initially to the ileocolic lymph nodes and later to the infraduodenal and paraaortic lymph nodes [28]. Therefore, colectomy with lymph node dissection has been reported to be the treatment of choice for carcinoma of the appendix [29, 30]. Simple appendectomy is inadequate for primary appendiceal adenocarcinomas. There was a significant difference in the 5-year survival rate between those who underwent appendectomy alone and those who had a right hemicolectomy in the largest published series of 94 patients [3]. In addition, 38% of patients who underwent right hemicolectomy as a second procedure had an upstaging of their disease [3].

In summary, we reported a case of primary appendiceal adenocarcinoma of colonic type with perforating peritonitis, after bypass surgery. Cancer of the appendix was suspected and ileocaecal resection in combination with lymph node dissection was performed. The tumour obstructed the orifice of the appendix, and this may have caused the perforation. Although deficiency in the muscle fibres of the vermiform appendix not only may predispose to perforation but may also lead to early dissemination or direct invasion of adjacent structures, no evidence of recurrence or metastasis was noted in the 12-month postoperative period in our patient. In acute appendicitis, and especially in cases with perforation, it is important to consider the possibility of appendiceal adenocarcinoma.

References

1. Chang P and Attiyeh FF: Adenocarcinoma of the appendix. *Dis Colon Rectum* (1981) **24**, 176–180.
2. Lyss AP: Appendiceal malignancies. *Semin Oncol* (1988) **15**, 129–137.
3. Nitecki SS, Wolff BG, Schlinkert R and Sarr MG: The natural history of surgically treated primary adenocarcinoma of the appendix. *Ann*

- Surg (1994) **219**, 51-57.
4. Connor SJ, Hanna GB and Frizelle FA: Appendiceal tumors: Retrospective clinicopathologic analysis of appendiceal tumors from 7,970 appendectomies. *Dis Colon Rectum* (1998) **41**, 75-80.
 5. Rutledge RH and Alexander JW: Primary appendiceal malignancies: Rare but important. *Surgery* (1992) **111**, 244-250.
 6. Gamble HA II: Adenocarcinoma of the appendix: An unusual case and review. *Dis Colon Rectum* (1976) **19**, 621-625.
 7. Yamada T, Murao Y, Nakamura T, Tabuse H, Miyamoto S, Imai S and Nakano H: Primary adenocarcinoma of appendix, colonic type associated with perforating peritonitis in an elderly patient. *J Gastroenterol* (1997) **32**, 658-662.
 8. Carr NJ, McCarthy WF and Sobin LH: Epithelial noncarcinoid tumors and tumor-like lesions of the appendix. A clinicopathologic study of 184 patients with a multivariate analysis of prognostic factors. *Cancer* (1995) **75**, 757-768.
 9. Jass JR and Sobin LH: Histological typing of intestinal tumours: WHO international histological classification of tumours. 2nd Ed, Springer-Verlag, Berlin (1989) pp 25-28.
 10. Cortina R, McCormick J, Kolm P and Perry RR: Management and prognosis of adenocarcinoma of the appendix. *Dis Colon Rectum* (1995) **38**, 848-852.
 11. Ben-Aaron U, Shperber J, Halevy A, Negri M, Bogokovski H and Orda R: Primary adenocarcinoma of the appendix: Report of five cases and review of the literature. *J Surg Oncol* (1987) **36**, 113-115.
 12. Gilhome RW, Johnston DH, Clark J and Kyle J: Primary adenocarcinoma of the vermiform appendix: Report of a series of ten cases, and review of the literature. *Br J Surg* (1984) **71**, 553-555.
 13. Lenriot JP and Huguier M: Adenocarcinoma of the appendix. *Am J Surg* (1988) **155**, 470-475.
 14. Willett CG, Fung CY, Kaufman DS, Efird J and Shellito PC: Postoperative radiation therapy for high-risk colon carcinoma. *J Clin Oncol* (1993) **11**, 1112-1117.
 15. Bodner G, Springer P, Dessl A, Ensinger C and Jaschke W: Sonographic appearance of an appendix carcinoma. *Ultraschall Med* (1998) **19**, 90-91.
 16. Andersson A, Bergdahl L and Boquist L: Primary carcinoma of the appendix. *Ann Surg* (1976) **183**, 53-57.
 17. Conte CC, Petrelli NJ, Stulc J, Herrera L and Mittelman A: Adenocarcinoma of the appendix. *Surg Gynecol Obstet* (1988) **166**, 451-453.
 18. Schlatter MG, McKone TK, Scholten DJ, Bonnell BW and DeKryger LL: Primary appendiceal adenocarcinoma. *Am Surg* (1987) **53**, 434-437.
 19. Chen KT and Spaulding RW: Appendiceal carcinoma masquerading as primary bladder carcinoma. *J Urol* (1991) **145**, 821-822.
 20. Hananel N, Powsner E and Wolloch Y: Primary appendiceal neoplasms: *Isr J Med Sci* (1993) **29**, 733-734.
 21. Reichle FA, Brigham MP, Fleegler EJ and Rosemond GP: Adenocarcinoma of the vermiform appendix. *Am Surg* (1971) **37**, 344-350.
 22. Berman AT and James PM Jr: Adenocarcinoma of the vermiform appendix. *Am J Surg* (1970) **119**, 733-736.
 23. Ozakyol AH, Saricam T, Kabukcuoglu S, Caga T and Erenoglu E: Primary appendiceal adenocarcinoma. *Am J Clin Oncol* (1999) **22**, 458-459.
 24. Ghosh BC, Huvos AG and Whiteley HW: Pseudomyxoma peritonei. *Dis Colon Rectum* (1972) **15**, 420-425.
 25. Green N, Gancedo H, Smith R and Bennett G: Pseudomyxoma peritonei-nonoperative management and biochemical findings. A case report. *Cancer* (1975) **36**, 1834-1837.
 26. Didolkar MS and Fanous N: Adenocarcinoma of the appendix: A clinicopathologic study. *Dis Colon Rectum* (1977) **20**, 130-134.
 27. Cerame MA: A 25-year review of adenocarcinoma of the appendix. A frequently perforating carcinoma. *Dis Colon Rectum* (1988) **31**, 145-150.
 28. Otto RE, Ghislandi EV, Lorenzo GA and Conn J Jr: Primary appendiceal adenocarcinoma. *Am J Surg* (1970) **120**, 704-706.
 29. Hopkins GB, Tullis RH and Kristensen KA: Primary adenocarcinoma of the vermiform appendix: report of seven cases and review of the literature. *Dis Colon Rectum* (1973) **16**, 140-144.
 30. Pugeda FV and Hinshaw JR: Primary adenocarcinoma of the appendix. *Dis Colon Rectum* (1969) **12**, 457-461.