

## Rat Small Intestinal Transplantation: A Comparison of the Cuff and Hand-Suture Methods

Atsunori NAKAO<sup>a</sup>, Naoshi MITSUOKA<sup>a</sup>, Sun Don SHEN<sup>a</sup>, Noriaki TANAKA<sup>a</sup> and Eiji KOBAYASHI<sup>b</sup>

<sup>a</sup>Department of Surgery I, Okayama University Medical School, Okayama 700-8558 and <sup>b</sup>Division of Organ Replacement Research, Center for Molecular Medicine, Jichi Medical School, Tochigi 329-0498, Japan

The rat model is ideal for investigating various reactions to small intestinal transplantation (SIT). The conventional surgical model (hand-suture method), however, requires microsurgical techniques and remains difficult for beginners to perform at a high success rate. We have employed the SIT model using the cuff method, by which the vessels are anastomosed without sutures. All of the fellows who used the hand-suture models needed over  $8 \pm 5.8$  months until they achieved a 70% success rate. In contrast, the fellows employing the cuff method mastered SIT models after 6 weeks' practice. The cuff technique is a simplified and quickly mastered alternative to the hand-suture method that may be desirable for researchers who wish to apply the method to SIT experiments and whose primary purpose is not microsurgery.

**Key words:** small intestinal transplantation, cuff technique, rat model

**C**omplications related to small intestinal transplantation (SIT) remain difficult to control with conventional immunosuppressive drugs, unlike those occurring with transplantations of other solid organs (1, 2). Experimental solutions obtained using animal models would therefore have direct clinical implications. The rat model offers several practical advantages over large-animal models with regard to cost, social concerns, and ability to perform detailed immunologic studies.

Since Monchik and Russel (3) described the first rat SIT model in 1971, their technical procedure has been widely used. This method requires microsurgical techniques and remains difficult for beginners to perform at a high success rate. The microvascular anastomosis

involved in this procedure must be performed quickly and perfectly in order to avoid prolongation of systemic clamping and the warm ischemic time. It is therefore necessary to find some simplified method that can be easily learned without long-term practice.

The SIT model using the cuff method, by which the vessels are anastomosed without sutures, was first reported by Wallander *et al* (4). Recently, Kobayashi and his colleagues (4-15) have conducted extensive investigations on rat SIT using the cuff technique. Compared to the hand-suture method, the cuff method can significantly decrease the warm ischemic time and prevent bleeding from the vascular anastomosis site. Moreover, only a few weeks' training is needed for the researcher to learn the technique and to start running the experiment.

At the Department of Surgery I, Okayama University, we have employed the cuff method for SIT research since 1996. In this article, we compare rat SIT using the cuff method with conventional hand-suture, and evaluate the cuff method and its significance with regard to SIT studies.

### Materials and Methods

**Rats.** Animals used before 1996 were inbred LEW (RT1<sup>l</sup>), WKA (RT1<sup>k</sup>), and (LEW × WKA) F1 rats weighing 250 to 350 g. Since the introduction of the cuff method, we have used ACI (RT1<sup>a</sup>) and LEW rats weighing 200 to 250 g. All rats were maintained at the Animal Center of Okayama University and received humane care according to the Guidelines for the Humane Care and Handling of Laboratory Animals of Okayama University.

---

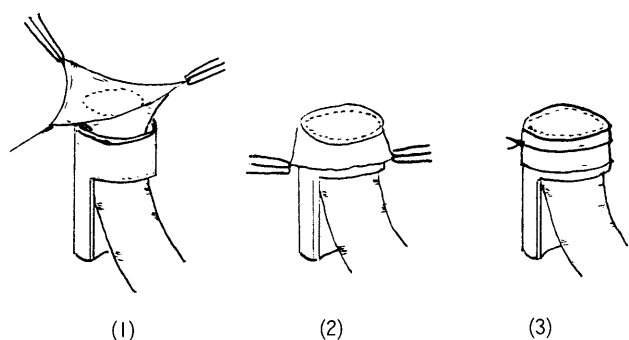
\* To whom correspondence should be addressed.

## Surgical Procedure

### Cuff Method

**Donor operation.** A transverse skin incision is made on the abdomen. After tying and cutting both middle and right colonic vessels, the entire colon is removed. The portal vein (PV) is dissected by ligation of the splenic and pyloric veins. The aorta above and below the origin of the superior mesenteric artery (SMA) is mobilized by ligating and dividing the renal and lumbar arteries. After systemic heparinization (100 units) and ligation of the distal abdominal aorta with 6-0 silk, the ileum from the middle of the intestine to the ileocaecal valve (approximately 40 cm) is prepared with a vascular pedicle consisting of aorta, SMA, and PV. The graft intestine segment should be less than 40-60 cm (approximately half of the total length), as a longer graft cannot handle an adequate blood supply from the renal artery. The lumen of the bowel is irrigated with 40 ml of cold normal saline to clear the intraluminal contents. The following procedures are performed while the intestinal graft is placed in a cold bath. The cuff is prepared with polyethylene tubing (SURFLO, 14 or 16 gauge, Terumo Co. Ltd., Tokyo, Japan). PV of the graft is passed through the cuff, then turned over the cuff and secured with 6-0 silk (Fig. 1).

**Recipient operation.** Under ether anesthesia, a straight midline abdominal incision is made. After native intestine is wrapped in a sponge and retracted to the right side, the left kidney is freed from the retroperitoneum. After the left ureter is ligated and divided, the left kidney is removed. The renal vein and artery are released from surrounding connective tissue and cross-clamped with



**Fig. 1** Attachment of the cuff. The vessel is pulled up through the cuff lumen (1). The vessel is everted over the cuff body (2) and fixed with a 6-0 silk ligation (3).

microvessel clips. The prepared graft is placed *in situ*, and the cuffed PV is inserted into the renal vein of the recipient and tied with 6-0 silk. The arterialization is then carried out by inserting the recipient renal artery, cuffed with 20 or 22 gauge polyethylene tubing, into the donor aorta containing the SMA (Fig. 2). Both ends of the grafted small intestine are exteriorized as stomata, and the abdominal wall is closed.

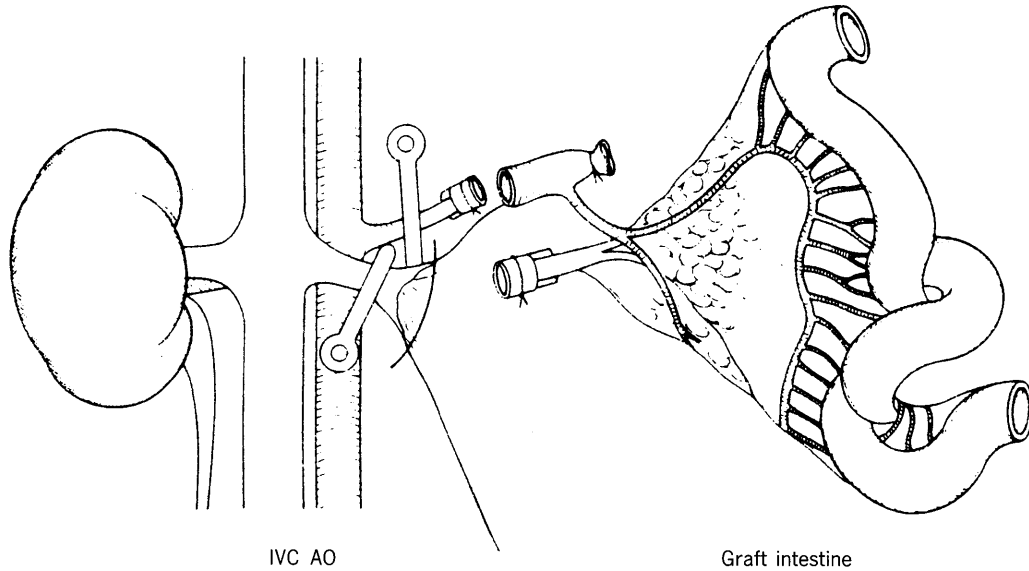
### Hand-Suture Method

**Donor operation.** Donor preparation is carried out primarily as outlined above. The donor small bowel is harvested based on a vascular pedicle consisting of the superior mesenteric artery with a part of aorta as well as the portal vein transected near its bifurcation. The graft consists of small bowel and mesentery from the middle of the intestine to the terminal ileum along with the attached portal vein and superior mesenteric artery.

**Recipient operation.** A straight median abdominal skin incision is made. After native intestine is wrapped in a sponge and retracted to the right side, the inferior vena cava (IVC) and the aorta are released from surrounding connective tissue and cross-clamped with microvessel clips at a level below the left renal vessels. The graft is covered by a gauze sponge packed with iced saline and placed on the right side of the rat. The arterial end-to-side anastomosis is first performed under a surgical microscope using 9-0 prolene. A stay suture placed at the midpoint of the arteriostomy provides a better surgical view. The anterior wall of the anastomosis is sutured externally, and the graft is rotated to the opposite side for easy suturing of the back wall (Fig. 3). Next, the back wall is sutured externally. Next, the donor portal vein is placed end-to-side into the recipient IVC. Interrupt sutures are made using 9-0 or 10-0 nylon. The ends of the small intestine are exteriorized and sutured to the abdominal wall as ileostomies, and the abdominal wall is then closed.

### Object

At the Department of Surgery I, Okayama University, heterotopic SIT models in rats have been used for various investigations by research fellows. Between 1989 and 1995, 5 fellows studied immunological issues using rat SIT models with hand-suturing, and 4 fellows have applied SIT using the cuff method since 1996. The clinical experiences of these fellows were not significantly different between these 2 groups, without having prior

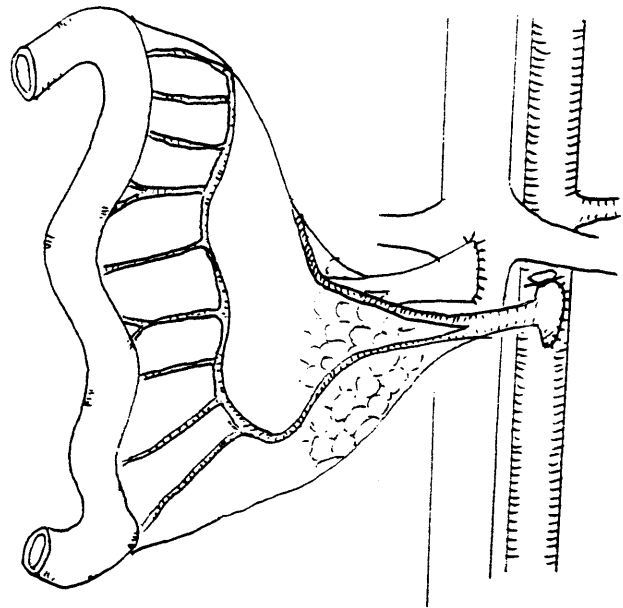


**Fig. 2** Small intestinal transplantation using the cuff technique. The venous anastomosis is first performed between the cuffed donor portal vein and the recipient renal vein, with tension being maintained by traction. The arterial anastomosis is then carried out by inserting the recipient renal artery, cuffed with a 22-gauge tube, into the donor aortic cuff containing the superior mesenteric artery. (Kobayashi *et al.*, 1992, reprinted with permission from *Medicina Philosophica*, © Copyright Nagai Shoten Co. Ltd., Japan.)

microsurgical experience. During the training period, all of the fellows were allowed to observe a demonstration of the operation once or twice by a fellow who had adequate training. Data regarding surgical information, including the number of animals needed until the first successful operation and the period required to achieve a success rate greater than 70%, were obtained based on personal interviews.

**Results**

All of the fellows who used the hand-suture models needed more than 30 pairs of animals (donor and recipients) until the first successful operation. Although 3 of them were not sure of actual numbers because a long time had passed since they had finished their studies, they could not perform the first successful surgery within 30 transplants, and it took over  $8 \pm 5.8$  months for them to achieve a 70% successful rate. In contrast, the fellows who used the cuff method could master SIT models after 6 weeks' practice, which was much faster than with the hand-suture method. Moreover, all fellows using the cuff method could carry out a successful transplantation within 10 days of the start of training (less than 13 transplants), even with no previous experience with rodent transplanta-



**Fig. 3** Conventional small intestinal transplantation (hand-suture method). The arterial end-to-side anastomosis was performed first under the surgical microscope using 9-0 prolene. Next, the donor portal vein was placed end-to-side into the recipient IVC using interrupt sutures with 9-0 or 10-0 nylon.

tion (Table 1).

## Discussion

Kobayashi *et al.* first utilized the cuff technique in combination with small intestine/liver transplantation in rats (5). Thereafter, an extensive series of more than 600 SIT cases using the cuff technique have been reported by Kobayashi and his colleague (5-16), with a very high success rate (95%) being obtained for rat segmental SIT.

A technique for orthotopic liver transplantation (OLT) in the rat using cuff anastomosis developed by Kamada *et al.* (17) has considerably shortened the anhepatic phase in the recipient, and has resulted in an excellent long-term survival rate; the technique has thus become the standard method for rat OLT. It is also noteworthy that a high success rate can be achieved in combined with OLT that has not achieved with hand-suturing alone (10). However, the SIT model using the cuff method is still not as well-received as OLT. To the best of our knowledge, this model has been used only by very few researches until now, and their studies are cited in the reference section of this article. But the cuff method as well as hand-suture method can be used to study transplantation immunology, including both graft-versus-host disease (GVHD) and host-versus-graft reaction.

We have previously carried out various studies using the unidirectional GVHD model by the hand-suture method. Orita *et al.* (18) have described the beneficial effects of combination therapy with FK506 and prednisolone on GVHD following SIT based on the use of this model. Kai *et al.* (19) and Okitsu *et al.* (20) have demonstrated that deoxyspergualin prevents GVHD after SIT using the same model. Recently, an increasing

number of studies of GVHD using the cuff method have been reported. Kobayashi *et al.* (7) have developed a combined small bowel/liver transplantation model using the cuff method and have shown that liver graft prevents both a rejection of the small bowel allo-graft and GVHD associated with small bowel grafting. Mitsusada *et al.* (12) have shown that FTY720, a new immunosuppressant, prevents graft rejection and GVHD in rat SIT.

In addition to the investigation of GVHD, the SIT model using the cuff method has been shown to be appropriate for studies of various immunologic and functional factors following SIT. Saito *et al.* (14) have shown the usefulness of endoscopic examination for the early detection of acute rejection in a rat SIT model using the cuff method. Ogino *et al.* (16) have demonstrated that cyclosporin A is more actively absorbed from the ileum than from the jejunum, but that tacrolimus is absorbed equally from both sites in the orthotopic SIT model using the cuff technique. Miyauchi *et al.* (13) have shown that the combined administration of donor splenocytes and FK506 reduces allograft rejection and prolonged survival in rat SIT. Nakao *et al.* (21, 22) have described the immunomodulatory effects of donor-specific bone marrow transplantation via the portal vein in a high-responder rat SIT.

Our data showed that the cuff method can be mastered after only a short period of practice and can result in both cost and time savings in the rat segmental SIT experiments. The cuff technique significantly reduces the training period in comparison to that required for the hand-suture technique, which is a skill-demand procedure for young investigators. Of course, although the cuff technique provides a simplified procedure for vascular anastomosis, it does require extensive training with regard to

**Table 1** Comparison between direct hand-suturing and the cuff method

Research fellows	Procedure	Experience as a surgeon (years)	Experience with microscopic surgical techniques	Transplants needed until the first success	Amount of time required to achieve 70%
1	Hand suture	6	No	> 30	7 months
2	Hand suture	6	No	> 30	6 months
3	Hand suture	4	No	> 50	18 months
4	Hand suture	6	No	30	3 months
5	Hand suture	6	No	45	6 months
6	Cuff method	6	No	8	5 weeks
7	Cuff method	14	No	13	4 weeks
8	Cuff method	5	No	5	6 weeks
9	Cuff method	5	No	3	3 weeks

cuff preparation. The diameter of the renal artery is sometimes considered too small for beginners to apply a polyurethane cuff in preparation for the arterial anastomosis. But, once mastered, the procedure can be performed quickly with a high technical success rate. Only a few weeks' training is needed for the researcher to learn the technique and to start running experiments.

Moreover, the merits of the cuff method include a significant decrease in the warm ischemic time and a prevention of bleeding from the anastomosis. This model has decreased the graft warm ischemic time to  $10 \pm 1.4$  min, compared to  $25 \pm 5$  min with suture technique (23).

It is also important, however, to understand the disadvantages of the cuff method. The major drawback of this method is that it requires a left-side nephrectomy, although this approach is well accepted even in clinical transplantation practice (1, 2).

Another disadvantage of this model is that the intestine segment to be transplanted cannot be greater than 40 cm (about half of the total length). Because the blood flow from the renal artery is limited for a graft supply, an entire small intestinal transplantation, namely from the ligament of Trietz to the ileocecal valve, is impossible using the cuff method (24). Therefore, this method might only be suitable for segmental SIT. The segmental SIT model must be studied further, as segmental SIT is an option for addressing donor shortages. Moreover, segmental SIT with living donors might be another option.

When the entire SIT model is needed, a modified cuff method that uses the cuff only for venous drainage can be adopted (25). This technique can be carried out as follows: end-to-side direct hand anastomosis is performed between the donor and recipient aortas, and the donor portal vein with polyethylene cuff is anastomosed with recipient left renal vein. Venous anastomosis using a cuff decreases the chance of thrombosis and the ischemic time. Moreover, a hand-suture on the artery results in sufficient blood flow. We have actually applied this method to orthotopic SIT between syngeneic rat combinations and have found the survival time be over 90 days with weight gain. This may thus be an appropriate model for beginners studying orthotopic entire SIT.

The formation of fibrous and granulomatous tissue around the polyethylene cuff is also a potential problem. Kitakado *et al.* (26) have claimed that the polyethylene cuff is unsuitable for long-term use in the rat orthotopic liver transplant model, because the venous anastomoses tend to be occluded due to foreign-body reaction. We

have also demonstrated that the polyethylene cuff employed in the SIT is associated with occlusion in 40% of venous anastomoses (27). However, the blood supply to the graft can be maintained by collateral vessels. To achieve better results, a cuff made of bio-absorbable material should be used in long-term studies.

In conclusion, the rat model using the cuff method is promising for beginning SIT researchers. Both cuff and hand-suture techniques have their merits and disadvantages, and it is important to select the appropriate technique to suit the experimental design and purpose. When surgical practice of microsurgery is not the primary purpose, however, it is desirable to apply a simplified method that can be easily mastered by researchers without long-term practice, with the accompanying loss of time and money.

**Acknowledgement.** We are grateful to Dr. Xuedong Chi (Department of Transplant Surgery, University of Pittsburgh, USA) for his critical reading of our manuscript.

## Reference

1. Grant D: Current results in intestinal transplantation. The international intestinal transplant registry. *Lancet* (1996) **347**, 1801-1803.
2. Grant D: Intestinal transplantation: 1997 report of the international registry. *Transplantation* (1999) **67**, 1061-1064.
3. Monchik GJ and Russell PS: Transplantation of small bowel in the rat: Technical and immunological considerations. *Surgery* (1971) **70**, 693-702.
4. Wallander J, Holtz A, Larsson E, Gerdin B, Lackgren G and Tufver-son G: Small-bowel transplantation in the rat with a nonsuture cuff technique. Technical and immunological considerations. *Transpl Int* (1988) **1**, 135-139.
5. Kobayashi E, Kamada N, Enosawa S, Toyama N, Delriviere L, Goto S, Kim YI and Miyata M: Comparison of potentiality to induce graft-versus-host reaction with small bowel, pancreas/spleen, and liver transplantation in the rat. *Clin Exp Immunol* (1993) **92**, 527-531.
6. Toyama N, Kobayashi E, Kamada N, Doi M and Miyata M: Small bowel transplantation in rats: Endoscopic and histological evaluation of graft rejection. *Gastroenterol Jpn* (1993) **28**, 209-217.
7. Kobayashi E, Kamada N, Enosawa S, Toyama N, Walker NI and Miyata M: Prevention by liver transplantation of the graft-versus-host reaction and allograft rejection in a rat model of small bowel transplantation. *Transplantation* (1994) **57**, 177-181.
8. Kobayashi E, Toyama N, Kiyozaki H, Enosawa S, Walker N, Kamada N and Miyata M: Small bowel transplantation for pediatric short bowel syndrome: Evaluation of the graft length required for development and the immunologic aspects relating to graft length. *J Pediatr Surg* (1994) **29**, 1331-1334.
9. Kobayashi E, Kamada N, Enosawa S, Toyama N and Miyata M: Syngeneic small-bowel grafting increases susceptibility to lethal graft-versus-host disease in the rat. *Eur Surg Res* (1995) **27**, 19-26.
10. Toyama N, Kobayashi E, Yamada S, Enosawa S and Miyata M: Fulminant second-set allograft rejection and endoscope findings following small bowel transplantation in the rat. *J Gastroenterol* (1995) **30**,

- 465-471.
11. Kiyozaki H, Kobayashi E, Toyama N and Miyata M: Segmental small bowel transplantation in the rat: Comparison of lipid absorption between jejunal and ileal grafts. *J Parenter Enteral Nutr* (1996) **20**, 67-70.
  12. Mitsusada M, Suzuki S, Kobayashi E, Enosawa S, Kakefuda T and Miyata M: Prevention of graft rejection and graft-versus-host reaction by a novel immunosuppressant, FTY720, in rat small bowel transplantation. *Transpl Int* (1997) **10**, 343-349.
  13. Miyauchi T, Ishikawa M, Tashiro S, Hisaeda H, Nagasawa H and Himeno K: Effect of donor-specific splenocytes via portal vein and FK506 in rat small bowel transplantation. *Transplantation* (1998) **65**, 27-32.
  14. Saito T, Kobayashi E, Toyama N, Fujimura A and Miyata M: Endoscopic findings in transplanted allo-intestine of rats after discontinuance of immunosuppressive agent. *J Gastroenterol* (1998) **33**, 336-342.
  15. Saito T, Kobayashi E, Ogino Y, Kaneko K, Fujimura A and Miyata M: Change in fecal fat excretion from allo-intestine transplanted rats after discontinuance of immunosuppressive agents. *J Gastroenterol* (1999) **34**, 182-188.
  16. Ogino Y, Kobayashi E and Fujimura A: Comparison of cyclosporin A and tacrolimus concentrations in whole blood between jejunal and ileal transplanted rats. *J Pharm Pharmacol* (1999) **51**, 811-815.
  17. Kamada N and Calne RY: A surgical experience with five hundred and thirty liver transplants in the rat. *Surgery* (1983) **93**, 64-69.
  18. Orita T, Tanaka S and Orita K: Effect of FK506 in combination with prednisolone on the graft-vs-host reaction after small bowel transplantation in rats. *Transplant Proc* (1994) **26**, 1594-1596.
  19. Okitsu T, Tanaka S and Orita K: Analysis of deoxyspergualin-induced host resistance to graft-versus-host reaction induced with small bowel transplantation in rats. *Transplant Proc* (1995) **27**, 1609-1611.
  20. Kai K, Tanaka S and Orita K: Donor pretreatment with deoxyspergualin on prevention of graft-vs-host reaction after small bowel transplantation. *Transplant Proc* (1996) **28**, 1847-1848.
  21. Nakao A, Yagi T, Matsukawa H, Endo A, Okada Y, DS Sun, Sadamori H, Inagaki M, Matsuno T and Tanaka N: Combined Effect of Donor-Specific Bone Marrow Transplantation via Portal Vein and FK506 on Small Bowel Transplantation in the Rat. *Transplant Proc* (in press).
  22. Nakao A, Yagi T, Sun DS, Matsukawa H, Endo A, Okada Y, Sadamori H, Inagaki M, Matsuno T and Tanaka N: Cytokine mRNA Expression on rat small bowel allograft treated with tacrolimus and simultaneous bone marrow transplantation via portal vein. *Transplant Proc* (2000) **32**, 1318-1319.
  23. Zhong R, Grant D, Sutherland F, Wang PZ, Chen HF, Lo S, Stiller C and Duff J: Refined technique for intestinal transplantation in the rat. *Microsurgery* (1991) **12**, 268-274.
  24. Ogino Y, Uchida H, Xiu DR, Kiyozaki H, Toyama N, Kogure H, Fujimura A, Miyata M and Kobayashi E: Rat organ transplantation using cuff anastomosis-an overview-. *Jpn J Transplant* (1999) **34**, 335-347.
  25. Nakao A, Takeichi T, Tahara K, Uchida H, Tanaka N and Kobayashi E: A combined cuff and suture technique for small intestinal transplantation in rats. *Microsurgery* (in press).
  26. Kitakado Y, Tanaka K, Asonuma K, Uemoto S, Matsuoka S, Utsunomiya H, Okamura R, Katayama T, Inomata Y, Ozawa K, Shimamoto T, Hyon SH and Ikeda Y: A new bioabsorbable material for rat venous anastomosis. *Transplantation* (1988) **46**, 620-622.
  27. Nakao A, Ogino Y, Tahara K, Uchida H, Tanaka N and Kobayashi E: Orthotopic intestinal transplantation in rats using cuff method: A histopathological evaluation of the anastomosis in long-term survivals. *Microsurgery* (in press).

---

Received July 19, 2000; accepted September 13, 2000.