

Efficacy of Lodoxamide Eye Drops on Tear Fluid Cytology of Patients with Vernal Conjunctivitis

Halit OGUZ^{a*}, Muharrem BITIREN^b, Osman Sevki ASLAN^c and Ilyas OZARDALI^b

Departments of ^aOphthalmology and ^bPathology, Harran University Faculty of Medicine, Sanliurfa 63100, Turkey and ^cDepartment of Ophthalmology, Istanbul University Cerrahpasa Faculty of Medicine, Istanbul 34270, Turkey

A double-masked, randomized, placebo-controlled study was conducted to evaluate the effectiveness of lodoxamide tromethamine 0.1 % eyedrops in preventing inflammatory cell accumulation in the tear fluid of patients with vernal conjunctivitis. A 1-week baseline period was followed by 4 weeks of treatment with either lodoxamide tromethamine 0.1 % ophthalmic solution or placebo in 30 symptomatic subjects with vernal conjunctivitis. Cytological evaluation of tear fluid was performed before and after the treatment. In the lodoxamide-treated group, but not in the placebo-treated group, the number of neutrophils ($P = 0.051$) and eosinophils ($P = 0.020$) in the tears significantly decreased at the end of 4 weeks when compared with baseline (Wilcoxon-signed rank test). It was concluded that lodoxamide treatment was significantly more effective than the placebo in terms of reducing inflammatory cells in the tear fluid in vernal conjunctivitis. This objective inhibition of inflammatory cells may be associated with clinical relief.

Key words: inflammatory cells, lodoxamide, tear, vernal conjunctivitis

Vernal conjunctivitis (VC), observed more commonly in male than in female subjects, is a seasonal allergic inflammatory condition of the conjunctiva, which affects particularly children and young adults between the ages of 3 and 25 years. The disease is characterized by mild to severe ocular itching, redness and giant papillae on the upper tarsal conjunctiva. Eosinophils, basophils, neutrophils and lymphocytes infiltrate both the substantia propria and the conjunctival epithelium (1).

The concomitant presence of itching and eosinophils in the conjunctival epithelium is considered a pathognomonic hallmark of this disease. However, the etiological mechanisms are not completely understood, and other immune or nonimmune mechanisms may also play a role (2). The corneal epithelial manifestations of VC are likely to be due to chemical toxicity caused by mast cell and eosinophil products, and specifically by major basic protein derived from eosinophilic granules (3).

Lodoxamide tromethamine 0.1 % is a newly developed antiallergic compound administered in the form of eye drops. Lodoxamide has been shown to reduce the ocular signs and symptoms in subjects with VC and allergic conjunctivitis, presumably by inhibiting mast cell degranulation and the toxic effects of eosinophil-derived products on corneal epithelium (4, 5).

We report here the results of a double-masked, randomized, placebo-controlled study designed to evaluate the effectiveness of this compound in the reducing the inflammatory cell profile in the tear fluid of patients with VC.

Materials and Methods

Thirty-three symptomatic patients with VC (23 males, 10 females) were included in the study. The diagnosis of VC was based on seasonal or chronic history of symptoms such as itching, redness, photophobia, and lacrimation and clinical examination signs such as the presence of polygonal flat-topped cobblestone papilla affecting the upper palpebral conjunctiva and limbal form marked by a thickened, broad, gelatinous opacification of the limbus. Males or females with a history of at least 1 year of VC were included in the study. Any additional eye disease,

* To whom correspondence should be addressed.

contact lens wear, pregnancy or the requirement for systemic or topical anti-allergic agents were grounds for exclusion.

After a week without treatment the patients received, in a randomized, double-masked, placebo-controlled study, either lodoxamide tromethamine 0.1 % ophthalmic solution or placebo in both eyes 4 times a day for 4 weeks. Treatment was formulated as follow: The active solution consisted of a commercially available solution of lodoxamide tromethamine 0.1 % aqueous isotonic eye drops containing 0.01 % benzalkonium chloride and EDTA (Alomide, Alcon, USA). The placebo solution contained the same concentration of preservative and EDTA in an aqueous solution. Signed informed consent was obtained from all patients or their parents. Three non-compliant patient withdrew from the study because they did not come to visit at the end of the study. These data were excluded from the statistical analysis. Both at the beginning and the end of the study, the tear fluid cytology was evaluated.

Two microliters of tears were collected with disposable micro-pipettes from the inferior conjunctival fornix of each eye and spread onto a glass slide, which was allowed to dry at room temperature for 3–5 min. All slides were stained with hematoxylin and eosin. Epithelial cells, neutrophils, eosinophils, lymphocytes observed on each slide were counted by light microscopy at 1000 \times magnification (Figs. 1 and 2). The total count in both eyes was calculated for each cell type for each patient.

The Wilcoxon-signed rank test was used for statistical

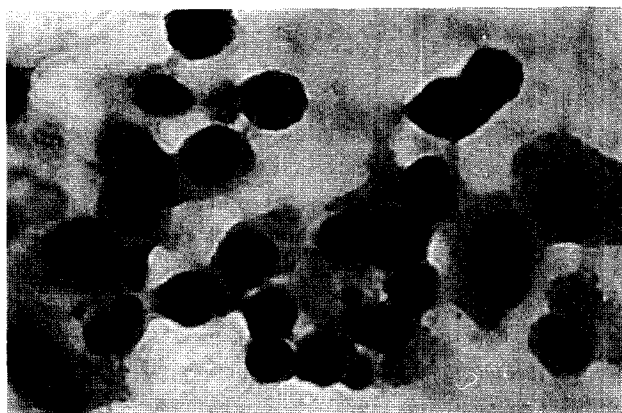


Fig. 1 Epithelial cells, neutrophils, eosinophils, lymphocytes observed on a slide (hematoxylin and eosin stain, 1000 \times). Notice the abundance of eosinophils.

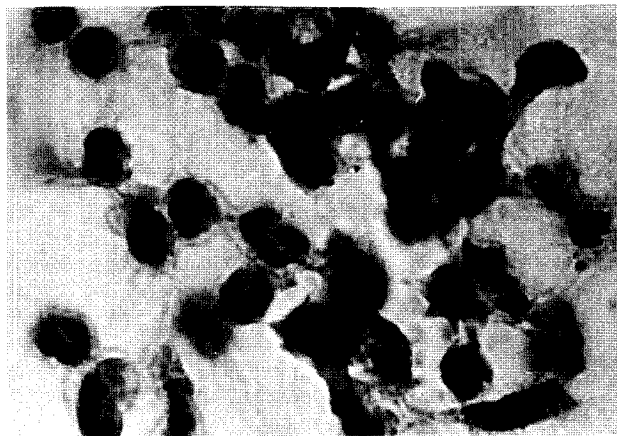


Fig. 2 Neutrophils, eosinophils, lymphocytes observed on a slide (hematoxylin and eosin stain, 1000 \times). Notice the absence of eosinophils.

evaluation. A probability of 0.05 or less was accepted as statistically significant.

Results

Data from 30 patients were included in the statistical analysis. There were 16 patients (10 males, 6 females) in the lodoxamide group and their mean age was 12 years (range 6–21 years); 14 subjects (10 males, 4 females) were contained in the placebo group and their mean age was 13 years (range 7–20 years). There were no significant differences between the two treatment groups in terms of the signs and symptoms of conjunctivitis and cell types counted before the treatment.

Patients in the lodoxamide group showed a statistically significant reduction from the baseline in the number of neutrophils ($P = 0.051$), of eosinophils ($P = 0.020$), but not lymphocytes ($P = 0.238$) (Fig. 3), while the placebo group did not show any statistically significant differences (Fig. 4). Statistical analysis was not performed on the counts of basophils and monocytes because of their low numbers.

No ocular side effects were observed by the physicians or noted by the patients or their parents.

Discussion

Lodoxamide tromethamine is a newly developed antiallergic agent. After ocular application, lodoxamide inhibited allergic conjunctival reaction and reduced the release

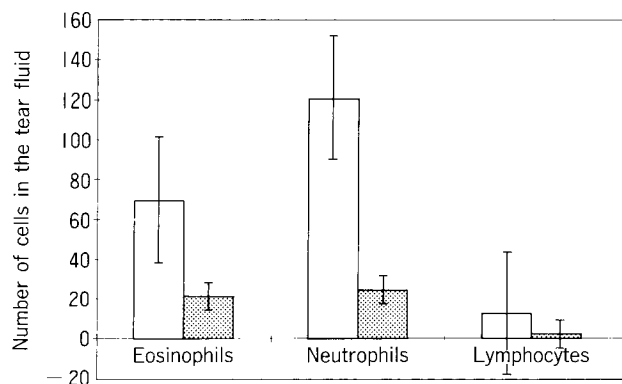


Fig. 3 The lodoxamide-treated eyes showed a significant reduction in the number of eosinophils and neutrophils when compared with the baseline ($P = 0.020$, $P = 0.051$, respectively, Wilcoxon-signed rank test). As visible in the figure, the reduction in the number of lymphocytes was not significant ($P = 0.238$). □: Before Therapy; ▨: After Therapy.

of histamine in an experimental model of allergic conjunctivitis in the rat (6). The protective effect of lodoxamide on mast cells was shown by measuring tryptase in tear fluid (7) and it was reported that lodoxamide significantly reduced this mast cell mediator in tear fluid after allergen challenge (7). Inflammatory cells and mast cell-derived products may, in turn, activate other cells or toxic products responsible for chronic inflammation and hypersensitivity reaction (7).

In particular, eosinophils play an important role in the pathogenesis of VC. Moreover, eosinophils and eosinophil-derived products contribute to conjunctival tissue damage (8). The presence of a higher number of these cells in the conjunctival epithelium is pathognomonic for this disease (9). However, eosinophils were not observed in the normal conjunctiva in some studies (10). But, the absence of eosinophils should not preclude the diagnosis of VC because there is great variation in the appearance of eosinophils (11).

We found that the lodoxamide-treated eyes had significantly fewer inflammatory cells in their tear fluid than the placebo-treated eyes when compared with their respective baseline values. Bonini *et al.* (7) reported that lodoxamide significantly decreased neutrophil and eosinophil accumulation in tear fluid during the immediate hypersensitivity reaction. Moreover, Akpek *et al.* (12) emphasized that lodoxamide was effective in reducing the quantity of inflammatory cells, particularly eosinophil and neutro-

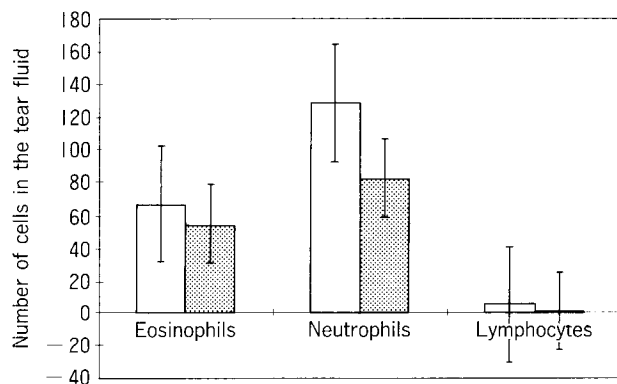


Fig. 4 Placebo-treated eyes did not show a significant reduction in the number of eosinophils, neutrophils and lymphocytes when compared with the baseline ($P = 0.138$, $P = 0.059$ and $P = 0.221$, respectively, Wilcoxon-signed rank test). □: Before Therapy; ▨: After Therapy.

phils, in tear fluid. However, Bonini *et al.* studied asymptomatic subjects with allergic conjunctivitis. In our study, the effects of lodoxamide were evaluated in symptomatic subjects with vernal conjunctivitis.

We observed a mild cell decrease in the placebo-treated patients. We suggest that the placebo serves as an irrigation liquid which leads to a decrease in the number of cells in the tear fluid. In fact, in many studies the application of a placebo also serves as a treatment in that irrigation is first approach to the management of allergic eye conditions. Ideally, to reduce bias, double-masked controlled clinical trials should be held in the same environment. Since this is not practical, we evaluated the individual responses by comparing the results after active treatment or placebo treatment with their respective baseline values.

In conclusion, our study shows that lodoxamide is effective in reducing inflammatory cells in the tear fluid in vernal conjunctivitis. These effects of lodoxamide on tear fluid cytology may be associated with relief of the signs and symptoms of this disease.

Acknowledgments. The authors wish to thank Zeki Dogan, Ph. D., for statistical analysis and Dogan Unal, M. D., for reviewing the grammar of the manuscript.

References

1. Allansmith MR, Baird RS and Griener JV: Vernal conjunctivitis and contact lens-associated giant papillary conjunctivitis compared and contrasted. *Am J Ophthalmol* (1979) **87**, 544-555.
2. Bonini ST, Bonini SE, Allansmith MR, Schiavone M, Berruto A, Centofanti M and Bucci MG: Topical histamine testing for conjunctival hyperreactivity in vernal conjunctivitis. *Invest Ophthalmol Vis Sci* (1989) **30**, 503.
3. Buckley RJ: Vernal keratoconjunctivitis. *Int Ophthalmol Clin* (1988) **28**, 303-308.
4. Santos CI, Huang AJ, Abelson MB, Foster CS, Friedlander M and McCulley JP: Efficacy of lodoxamide 0.1% ophthalmic solution in resolving corneal epitheliopathy associated with vernal keratoconjunctivitis. *Am J Ophthalmol* (1994) **117**, 488-497.
5. Caldwell DR, Verin P, Hartwich-Young R, Meyer SM and Drake MM: Efficacy and safety of lodoxamide 0.1% vs cromolyn sodium 4% in patients with vernal keratoconjunctivitis. *Am J Ophthalmol* (1992) **113**, 632-637.
6. Yanni JM, Weimer LK, Glaser RL, Lang LS, Robertson SM and Spellman JM: Effect of lodoxamide on *in vitro* and *in vivo* conjunctival immediate hypersensitivity responses in rats. *Int Arch Allergy Immunol* (1993) **101**, 102-106.
7. Bonini S, Schavone M, Bonini S, Magrini L, Lischetti P, Lambiase A and Bucci MG: Efficacy of lodoxamide eye drops on mast cells and eosinophils after allergen challenge in allergic conjunctivitis. *Ophthalmology* (1997) **104**, 849-853.
8. Udell U, Gleich GJ, Allansmith MR, Ackerman SJ and Abelson MB: Eosinophil granule major basic protein and charcot-leyden crystal protein in human tears. *Am J Ophthalmol* (1981) **92**, 824-828.
9. Abelson MB, Madiwale N and Weston JH: Conjunctival eosinophils in allergic ocular disease. *Arch Ophthalmol* (1983) **101**, 555-556.
10. Nomura K, Takamura E, Murata M, Fukagawa K and Uechi K: Quantitative evaluation of inflammatory cells in seasonal allergic conjunctivitis. *Ophthalmologica* (1997) **211**, 1-3.
11. Friedlander MH, Ohashi Y and Kelley J: Diagnosis of allergic conjunctivitis. *Arch Ophthalmol* (1984) **102**, 1198-1199.
12. Akpek EK, Hasiripi H, Albayrak L and Kalayci D: Comparison of the efficacy and safety of lodoxamide and cromolyn sodium in the treatment of seasonal and perennial allergic conjunctivitis. *T Klin J Ophthalmol* (1996) **5**, 117-122.

Received December 28, 1998; accepted February 16, 1999.