

Ultrasonographic Analysis of Shoulder Rotator Cuff Tears

Shunji MASAOKA, Hiroyuki HASHIZUME*, Masuo SENDA, Keiichiro NISHIDA, Mitsuru NAGOSHI and Hajime INOUE

Department of Orthopaedic Surgery, Okayama University Medical School, Okayama 700-8558, Japan

Seventy-nine shoulders suspected of rotator cuff tears were examined by ultrasonography (US) and forty-three received surgery. Long and short axis scans were performed and findings of each were separately classified according to a five-grade system, and the results were correlated with the actual extent of tear observed during surgery. Internal echogenicity and subacromial impingement were analyzed before and after surgery. A accuracy of US in detecting rotator cuff tears was analyzed. In addition, the correlation between cuff shape observed by US before surgery and actual shape observed during surgery was assessed. It was noted that cuff thinning and abnormalities in shape did not recover to normal after surgery. However, in the cases of discontinuities observed by US before surgery, US findings indicated that the torn cuff was anchored to the greater tuberosity and functional during active motion. Although post-operative US findings were not normal, clinical results were good in most cases. Sensitivity of US for detecting rotator cuff tear was 100% and specificity 94%. US is non-invasive, cost effective and allows the physician to examine the joint while it is in motion. Therefore, at this time, we use US as a screening method for detecting rotator cuff tears. Furthermore, US allows us to check for re-tears while the joint is in motion, which is essential for accurate diagnosis.

Key words: rotator cuff tear, ultrasonography, diagnostic image

In the past the diagnosis of rotator cuff tears was made based only on clinical findings and arthrography, however, other non-invasive imaging techniques, including ultrasonography (US) and magnetic resonance imaging (MRI), have been developed (1, 2). Several

reports on preoperative diagnostic imaging for rotator cuff tears (3-6) and on the usefulness of US as a diagnostic technique have been published. However, few have dealt with preoperative and long-term postoperative imaging (7, 8).

In this study, preoperative and postoperative images were compared with clinical manifestations and operative findings. The surgical results were also followed-up and analyzed, according to their preoperative and postoperative US images, to predict the surgical results before surgery.

Subjects and Methods

Over the last 15 years (1983-1997), 77 patients (79 shoulders) were examined by US in our outpatient clinic; of these, 41 patients (43 shoulders) had undergone surgical repair. Of the 43 shoulders operated on, 21 shoulders were examined by US before and after surgery, 7 only before surgery and 15 only after surgery. Patients who were examined by US after surgery were followed-up for at least 3 months. The 79 shoulders consisted of 45 males and 32 females, ranging in age from 20 to 79 years (average, 44 years). The postoperative follow-up periods ranged from 3 to 180 months (average, 29 months). Surgical observation of the tear size using Post's classification (9) revealed an incomplete tear (partial thickness tear) in 1 shoulder, a small tear in 4, a medium tear in 14, a large tear in 11, and a massive tear in 13. Complete rotator cuff tears were repaired by McLaughlin's method (10) in combination with Neer's anterior acromioplasty (11).

The US examination was performed in a sitting position with the shoulder in 0 degrees abduction and forearm 90 degrees supination position with a 7.5MHz linear transducer (EUB 450, Hitachi Co., Ltd., Tokyo, Japan). On both the normal and affected sides, the rota-

* To whom correspondence should be addressed.

tor cuff shape (thinning, discontinuity and absence along the long and short axes of scanning in the conventional US technique); measurement of cuff thickness (the proximal end of the greater tuberosity on long axis scanning, and 1 cm posterior and 1 cm proximal from the inter-tubercular sulcus on short axis scanning); and ecogenic changes in the cuff were examined. Subacromial impingement was also examined in the image during shoulder joint abduction. The US examinations were performed before surgery and 3, 6, and 12 months after surgery, and at the final follow-up time. Then, surgical findings and surgical results were compared for the extent of tear. Clinical evaluation was made according to Rowe's clinical score (12). Cuff thickness was compared between the affected side and the normal side before surgery and at final follow-up, and also compared before and after surgery by Mann-Whitney's U-test. Accuracy including sensitivity and specificity in detecting cuff tear was assessed statistically.

The cuff condition was divided into five grades, both in the long and short axes scanning (Figs. 1-4).

Long axis (Figs. 1 and 3)

Grade 0: Normal shape and echogenicity.

Grade 1: Cuff shape is normal, but there is abnormal echogenicity within the cuff.

Grade 2: Cuff thinness is present, and at the attachment to the greater tuberosity, cuff thickness is more than half the height of the greater tuberosity.

Grade 3: Cuff thinness is present, and at the attachment to the greater tuberosity, cuff thickness is less than half the height of the greater tuberosity.

Grade 4: Cuff disappearance.

Short axis (Figs. 2 and 4)

Grade 0: Normal shape and echogenicity.

Grade 1: Cuff shape is normal, but there is abnormal echogenicity of cuff.

Grade 2: Thinness in part of the cuff.

Grade 3: Thinness over a wide range of the cuff.

Grade 4: Cuff disappearance.

The correlation between grading of cuff condition before surgery and the extent of tear at surgery was analyzed.

Results

Cuff shape. Correlation between the extent of tear at surgery and the shape observed on US could be assessed for 26 shoulders in long axis scanning and 23 in short axis scanning before surgery, and 32 shoulders in

long axis scanning and 30 in short axis scanning after surgery. The results are shown in Tables 1 and 2.

Before surgery, for incomplete and small tears, only high echogenicity was noted. As the size of tear increased, the degree of thinning or defect of the cuff increased. After surgery, only those rotator cuffs which displayed high echogenicity on US before surgery retained their shape, but in most cases thinning remained and the shape did not return to that of normal side. However, in cases in which an absence or discontinuity of the cuff was noted before surgery, it was possible to observe the cuff anchored to the greater tuberosity after surgery on US (Fig. 5). As the extent of tear increased, the thickness of the repaired cuff became thinner. Grade 4 (absence of the cuff) was noted in only 1 case, a re-tear.

In long axis scanning, of the shoulders whose cuff shapes on US were classified as Grades 1 or 2 (no case was classified as Grade 0) before surgery, incomplete, small or medium sized tears were observed in 11 shoulders on long and 9 shoulders on short axis scanning. In these cases, we judged the US-based diagnoses as true-positive for smaller (incomplete, small or medium) tears. Large or massive tears were observed in 3 shoulders on long and 3 shoulders on short axis scanning. In these cases, we judged that US-based diagnoses were false-positive by indicating only smaller tears. Of the shoulders whose cuff shapes on US were classified as Grades 3 or 4, large or massive tears were observed in 10 shoulders on long and 9 shoulders on short axis scanning. We judged that in these cases, US-based diagnoses were true-positive for larger (large and massive) tears. Incomplete, small or medium sized tears were observed in 2 shoulders on long and 2 shoulders on short axis scanning. Thus, we judged that in these cases, US-based diagnoses were false-positive for larger tears. Therefore, sensitivity in detecting smaller tears was 85 % (11/13) in long axis and 73 % (8/11) in short axis scanning. Sensitivity in detecting larger tears was 77 % (10/13) on long axis and 75 % (9/12) on short axis scanning.

Of the 21 shoulders on which US was performed both before and after surgery, in 19 we were able to compare cuff shape before and after surgery (17 on both long and short axes and 2 on long axis only) (Table 3).

For incomplete and small tear cases (Nos. 1 and 2), all US findings showed Grade 1. For medium tear cases (Nos. 3-12), 7 of 10 cases were classified as Grade 2 on long axis scanning before surgery and 9 of 10 after surgery. Of massive tear cases (Nos. 16-19), 3 of 4

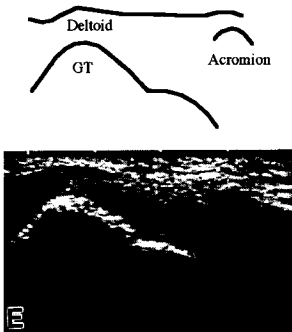
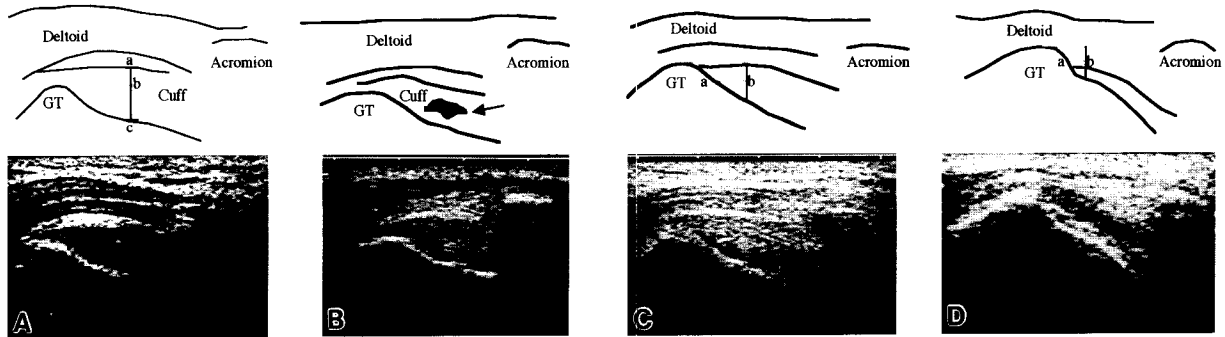


Fig. 1 Classification of rotator cuff tears before surgery by ultrasonography (US) on long axis scanning.

- A:** Grade 0. Normal shape. Shape of rotator cuff is convex and its attachment is over the greater tuberosity (GT). Cuff thickness and GT height is shown (ac: Cuff thickness; bc: GT height).
- B:** Grade 1. Shape of rotator cuff is same as grade 0, however, there is high echogenicity within the cuff (arrow).
- C:** Grade 2. Shape of rotator cuff is concave, and at its attachment to the GT, cuff thickness is more than half the height of the GT (a-b).
- D:** Grade 3. Shape of rotator cuff is concave, and at its attachment to the GT, cuff thickness is less than half the height of the GT (a-b).
- E:** Grade 4. There is no evidence of the rotator cuff because of the retraction of the cuff proximally.

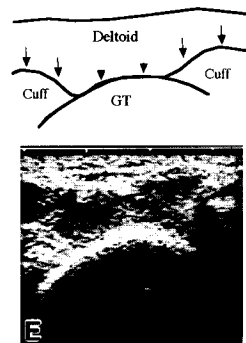
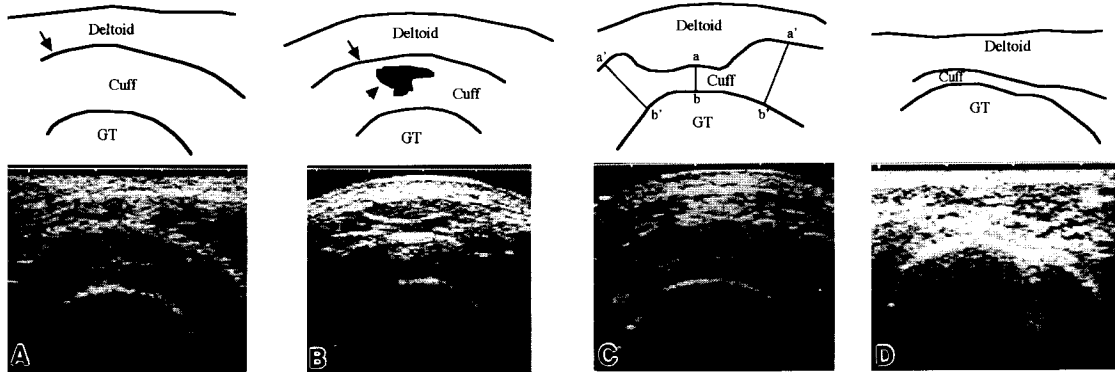


Fig. 2 Classification of rotator cuff tears before surgery by US on short axis scanning.

- A:** Grade 0. Normal shape. Border echo between the cuff and the subacromial bursa (SAB, arrow) is round and there is no concavity.
 - B:** Grade 1. Border echo between the cuff and the SAB is round (arrow), but there is a high echogenicity area within the cuff (arrowhead).
 - C:** Grade 2. There is thinness at the supraspinatus tendon (a-b), but thickness of the surrounding tendons is normal (a'-b').
 - D:** Grade 3. Thinness of cuff is over a wide range compared to Grade 2.
 - E:** Grade 4. There is discontinuity of the rotator cuff. Border echo between cuff and deltoid (arrows) is broken at the center of the GT (arrowheads).
- US; GT: See legend to Fig. 1.

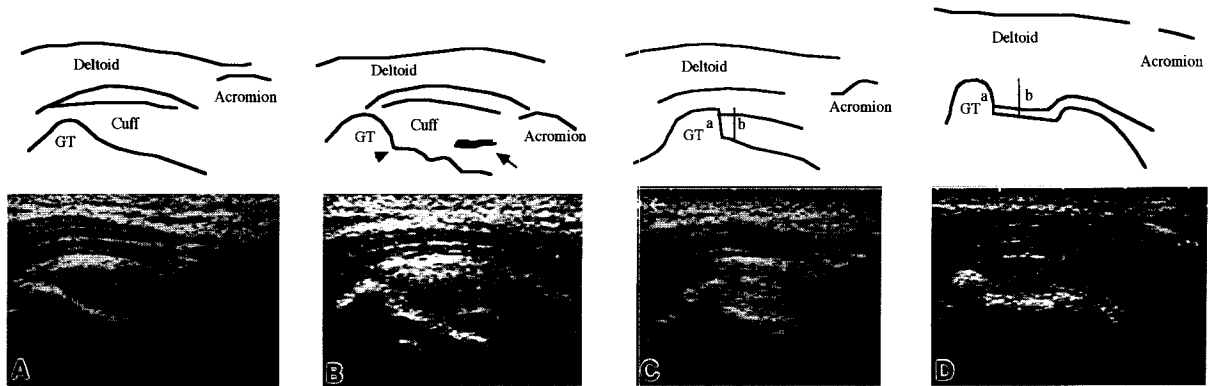


Fig. 3 Classification of rotator cuff tears after surgery by US on long axis scanning.

A: Grade 0. Normal shape (normal side is demonstrated for comparison). Shape of rotator cuff is convex and its attachment is over the GT.

B: Grade 1. Shape of rotator cuff is same as grade 0, however, there is a notch made by McLaughlin's procedure (arrowhead) and high echogenicity within the cuff (arrow).

C: Grade 2. Rotator cuff is anchored to the GT and cuff thickness is more than half the height of the GT (a-b).

D: Grade 3. Rotator cuff is anchored to the GT and cuff thickness is less than half the height of GT (a-b).

E: Grade 4. A re-tear case. There is no evidence of the rotator cuff and the humeral head has moved superiorly because of the absence of the rotator cuff.

US; GT: See legend to Fig. 1.

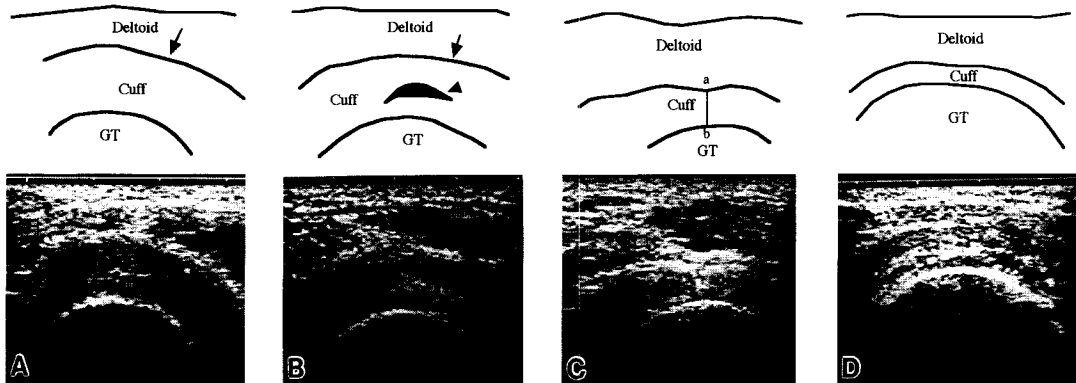
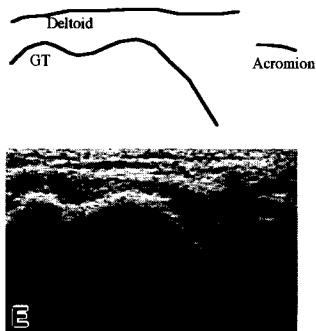


Fig. 4 Classification of rotator cuff tears after surgery by US on short axis scanning.

A: Grade 0. Normal shape (normal side is demonstrated for comparison). Border echo between the cuff and the subacromial bursa (arrow) is round and there is no concavity.

B: Grade 1. Border echo between the cuff and the subacromial bursa (arrow) is round, but there is a high echogenicity area within the cuff (arrowhead).

C: Grade 2. There is thinness at a part of rotator cuff (a-b), but thickness of the surrounding tendon is normal.

D: Grade 3. Cuff is thinner over a wider range than in Grade 2.

E: Grade 4. A re-tear case. Rotator cuff is invisible.

US; GT: See legend to Fig. 1.

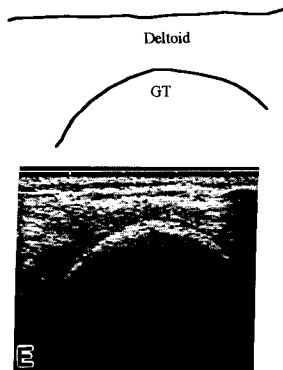


Table 1 Correlation between the extent of tear at surgery (incomplete ~ massive) and the grade of cuff condition observed at sonography before surgery

		Grade				
		0	1	2	3	4
Long axis scanning (n = 26)	Incomplete		1			
	Small		1			
	Medium		1	8	2	
	Large			2	6	
	Massive			1		4
Short axis scanning (n = 23)	Incomplete		1			
	Small		1			
	Medium		2	4	3	
	Large			2	4	2
	Massive			1	2	1

Table 2 Correlation between the extent of tear at surgery (incomplete ~ massive) and the grade of cuff condition observed by sonography after surgery

		Grade				
		0	1	2	3	4
Long axis scanning (n = 32)	Incomplete		1			
	Small		1	2		
	Medium			12	1	
	Large			4	1	
	Massive			5	4	1
Short axis scanning (n = 30)	Incomplete		1			
	Small		1	2		
	Medium		2	6	4	
	Large			3	2	
	Massive			3	5	1

Table 3 Correlation between the extent of tear at surgery and the grade of cuff condition observed by sonography before and after surgery

Case number	Extent of tear	Grade			
		Long axis scanning		Short axis scanning	
		Before	After	Before	After
1	I	1	1	1	1
2	S	1	1	1	1
3	Me	2	2	2	2
4	Me	2	3	—	3
5	Me	1	2	—	3
6	Me	2	2	2	3
7	Me	2	2	1	2
8	Me	2	2	1	1
9	Me	2	2	3	2
10	Me	3	2	2	3
11	Me	2	2	3	2
12	Me	3	2	3	2
13	L	3	2	2	3
14	L	3	3	3	3
15	L	2	2	2	2
16	Ma	2	3	3	2
17	Ma	4	3	2	2
18	Ma	4	2	3	2
19	Ma	4	4	4	4

I: Incomplete; S: Small; Me: Medium; L: Large; Ma: Massive; —: Not performed.

Table 4 Abnormal echogenicity within the rotator cuff at final follow-up

	Months		Years				
	~3	~6	~1	~3	~5	~10	~15
+	1	6	4	5	1	0	1
-	2	2	2	1	3	1	2

(cases)

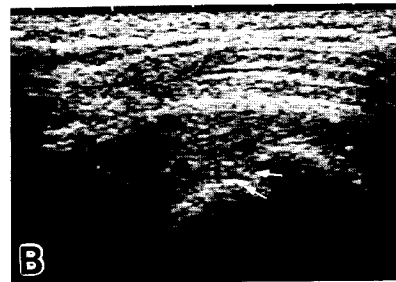


Fig. 5 US on long axis scanning (a 58-year-old male). **A:** Before surgery, there is discontinuity of rotator cuff on long axis scanning. **B:** After repair, the ruptured cuff is anchored to the base of the greater tuberosity (arrows).

cases were classified as Grade 4 in long axis scanning before surgery. However, on short axis scanning, medium, large, and massive cases showed various grades except No. 19 (a re-tear case).

Inner condition (abnormal echogenicity).

Of the 21 shoulders in which US was performed both before and after surgery, we were able to evaluate the inner condition in 19 shoulders. Of these, high echogenicity in the rotator cuff was observed in 9 of 19 shoulders before surgery, and at 3 months after surgery it was evident in 13 shoulders.

At the final follow-up, we were able to evaluate the inner condition of 31 shoulders (19 shoulders in which US was performed before and after surgery, and 12 after surgery only). The frequency of the presence of abnormal echogenicity is shown in Table 4.

Dynamic findings (subacromial impingement). Of the 21 shoulders in which US was performed both before and after surgery, dynamic scanning was performed in 19 shoulders. A subacromial impingement image was observed in 17 of 19 shoulders before surgery, however, at final follow-up, it had disappeared in all but 4 shoulders.

Measurement of cuff thickness. Of the 28 shoulders in which US was performed before surgery, rotator cuff thickness was measured in 24 shoulders on long axis scanning and 20 on short axis scanning. Rotator cuff thickness before surgery is shown in Table 5. According to preoperative rotator cuff thickness, a significant difference ($P < 0.001$) was observed between the normal and injured sides on both long and short axes of scanning.

Of the 36 shoulders in which US was performed after surgery, rotator cuff thickness was measured in 27 shoulders on long axis scanning and 26 on short axis scanning. Cuff thickness after surgery is shown in Table 6. On long axis scanning, a significant difference ($P < 0.01$) was observed between the normal and injured sides. And on short axis of scanning, a significant difference ($P < 0.01$) was again observed between these two groups.

Comparing the thickness before and after surgery (Table 7), there was a significant difference ($P < 0.05$) on long axis scanning. However, on short axis scanning the value was not significant ($P = 0.10$).

Diagnostic accuracy of US for evaluating cuff tears. In cases in which a cuff tear was suspected on US observations before surgery, if the tear was confirmed on arthrography or during open surgery, we

Table 5 Comparison of cuff thickness between affected and normal sides before surgery

	Long axis scanning (n = 24)	Short axis scanning (n = 20)
Affected side	2.7 ± 1.3	3.1 ± 1.6
Normal side	5.6 ± 1.2	5.7 ± 1.4
	$P < 0.001$	

(mm)

Table 6 Comparison of cuff thickness between affected and normal sides after surgery

	Long axis scanning (n = 27)	Short axis scanning (n = 26)
Affected side	3.9 ± 1.2	4.1 ± 1.2
Normal side	5.2 ± 1.5	5.5 ± 1.7
	$P < 0.01$	

(mm)

Table 7 Comparison of cuff thickness before and after surgery

	Long axis scanning (n = 21)	Short axis scanning (n = 21)
Before surgery	3.2 ± 1.2	3.4 ± 1.4
After surgery	4.1 ± 1.1	4.2 ± 1.1
	$P < 0.05$	

(mm)

N.S.: Not significant.

judged the US-based diagnosis to be true-positive. If leakage was not observed in arthrography and surgery was not performed, we judged it false-positive. If cuff tear was not suspected by US examination, but leakage was observed in arthrography, we judged that it was false-negative. And if the tear was not suspected in both US and arthrography, it was judged true-negative. Of the 64 shoulders in which US was performed before surgery, 28 were true-positive, 2 were false-positive, 0 was false-negative and 34 were true-negative. Therefore, sensitivity was 100 % (28/28) and specificity 94 % (34/36).

Correlation between clinical evaluation and US findings. Clinical evaluation according to Rowe's clinical score and grade of cuff tears is shown in Table 8. Before surgery, no correlation between grade of cuff tear and Rowe's clinical score was observed. After surgery, most of cases had excellent or good results (more than 70 points), except 4 cases (Table 9). One of

Table 8 Comparison of Rowe's clinical score between each grade of cuff shape

	Grade	Rowe's clinical score (average)	
Long axis scanning	1	56.7 ± 15.3	
	2	55.8 ± 12.4	
	3	54.3 ± 10.7	
	4	45.7 ± 19.9	
Short axis scanning	1	59.0 ± 15.6	
	2	59.4 ± 10.2	
	3	48.4 ± 12.9	
	4	54.5 ± 12.0	

*: Not significant.

Rowe's clinical score was established to evaluate the clinical results of shoulder diseases and consists of pain, stability, function, motion, and strength indicators.

Table 9 Correlation between the grade of cuff condition and Rowe's clinical score after surgery

	Grade	Rowe's clinical score		
		Excellent (100~85)	Good (84~70)	Fair (69~50)
Long axis scanning (n = 30)	1	1	1	
	2	14	6	1
	3	2	2	2
	4			1
Short axis scanning (n = 29)	1	3	2	
	2	6	6	1
	3	6	2	2
	4			1

(cases)

these 4 was a re-tear case revealed by US. The other 3 cases were massive tear cases, but the cuff was anchored to the greater tuberosity and seemed to be functional under active abduction on US, however, because of poor range of motion, the clinical result was fair.

Discussion

Rotator cuff tears cause symptoms such as shoulder pain and range of motion disturbance. However, frozen shoulder, calcified tendinitis and impingement syndrome also causes such dysfunctions. It is very important to differentiate such tears in making diagnosis for suitable treatment. However, accurate diagnosis based only on

clinical findings is often difficult. Therefore, diagnostic imaging techniques are essential.

Formerly, conventional radiography and double-contrast arthrography have been used for rotator cuff tear diagnosis. However, radiography shows only bony lesions, such as subacromial spurs and shortening of the distance between the acromion and the humeral head. Arthrography is sensitive in detecting full-thickness tears and incomplete tears on the glenohumeral joint side. However, arthrography is invasive and has several disadvantages such as allergic reaction and shoulder pain after examination (13). MRI has the advantages of high resolution and visibility of proximal cuff muscle belly, which cannot be observed on US because of interference by the bone. However, MRI has the following disadvantages: a) it is costly, b) it inconveniences the patient because it is time-consuming, c) it has unpredictable complications. In contrast, US has become popular due to the fact that it is a non-invasive method for detecting cuff tear.

When making diagnoses of rotator cuff tears based on US observations, we suggest that the following three issues be kept in mind.

First one must consider how to make an accurate diagnosis. Several researchers (3-6, 14) have proposed US procedures and criteria for evaluating findings to make accurate diagnoses of cuff tears. These authors also reported on the accuracy of US. Thinning of the rotator cuff, an irregular and/or discontinuous image of the echo border, which represents a change in shape, is indicative of a complete rotator cuff tear on diagnosis using US. In previous reports, sensitivity was from 91 % to 100 % and specificity from 83 % to 100 % in detecting complete rotator cuff tears. In our results, sensitivity was 100 % and specificity 94 %. However, a small tear with little change in shape, such as an echogenicity change, was difficult to identify. Read and Perko (14) reported that the sensitivity of US in detecting partial tears was 46 %. Therefore, the criteria for judging partial tears remain problematic.

Recently, some researchers (15) have reported on the relationship between irregularity of the greater tuberosity and rotator cuff tears, comparing their findings with the rates of cuff tears for normal shoulders. They found that US revealed the greater tuberosity to be irregular in 36 of 40 (90 %) shoulders with rotator cuff tears. This may be helpful in diagnosing rotator cuff tears.

The second issue is how to predict the extent of the

tear. In our results, incomplete and small cases showed high echogenicity within the rotator cuff. Cases with more than medium tears showed cuffs of abnormal shape, including thinning, discontinuity or complete absence of the cuff on long axis scanning, and concavity or absence of the cuff on short axis scanning. Moreover, as the tear size increased, the degree of thinning or defect of the cuff increased. Four of 5 massive cases showed disappearance of cuff on long axis scanning.

The third issue is how to evaluate postoperative condition and detect re-tear. In previous reports, postoperative abnormal findings were frequently observed. Crass *et al.* (7) performed US on 40 patients after rotator cuff repair and noted that postoperative shoulders were not normal in any of the cases and concluded that finding a defect or gap within the rotator cuff was the only accurate sign of a recurrent rotator cuff tear. Mack *et al.* (8) also noted that visualization of a defect in the cuff tear could be diagnosed with certainty. In our results, abnormal images, such as irregularity, thinning and internal echogenicity changes, were noted in all but 1 case. On long axis scanning, the cases with more than a medium tear showed cuff thinning in which the attachment of the cuff to the greater tuberosity was inferior to its attachment to its tip, because they were anchored to the greater tuberosity to just under its tip in McLaughlin's method. On short axis scanning, the concave cuff surface of the bursal side was observed in most medium, large and massive tear cases. This means that, if preoperative US reveals concavity or disappearance of the cuff, the repaired cuff will be thinner than normal in most cases. However, in the massive tear cases, though 4 of 5 (80 %) cases were Grade 4 on long axis scanning before surgery (Table 1), 5 of 10 (50 %) were Grade 2, and 4 of 10 (40 %) were Grade 3 (Table 2) after surgery. This shows that torn cuffs were repaired and the image of rotator cuff could be detected after surgery. Therefore, we suggest that abnormal images do not necessarily represent postoperative rotator cuff defects and dysfunctions such as re-tears.

In postoperative cases, it is usually difficult to distinguish the cuff border from the subacromial bursa. Therefore, it is important to confirm the rotator cuff surface by dynamic scanning. In addition, scanning while the patient is in active motion helps to confirm the function of tendon part of rotator cuff.

Of the cases we studied, subacromial impingement disappeared in all but 4 cases. One was a re-tear case.

However, in the other 3 cases, the cuff was clearly identified by US. These 3 cases were at 6 months after surgery. And, in all cases more than 1 year after surgery, impingement was not observed. Thus, some patients, less than 1 year after surgery, still had pain and range of motion disturbance, while others did not have such dysfunction at 3 months after surgery. In both groups, US findings were abnormal, as mentioned above. According to this evidence, we suggest that final clinical results after surgery should be determined at more than 1 year after surgery.

Based on the results mentioned above, can we conclude that US is a useful method for evaluating postoperative conditions? At present, we do not make the decision to re-operate based on US observations. Rather, we use clinical findings including pain, range of motion, muscle atrophy, stability and inconvenience in daily life. Evaluating recurrent tears by US is very difficult because US images of postoperative shoulders very much resemble those of preoperative cuff tears. However, US has important advantages over MRI. US can examine a patient while in motion (active or passive), and allows the physician to identify the echo border by passive abduction and to check the function of rotator cuff while in motion. US is non-invasive and easy to perform in outpatient clinics, and cost effective compared with MRI, and there is no exposure to X-rays. Nevertheless, US has several disadvantages. US diagnosis depends on the examiners' experience, and its resolution is inferior to that of MRI. At present, we only use US as a routine screening method. However, new high resolution instruments may soon be developed and the accuracy of diagnosis by US can only improve. In the near future, we hope to use US for determining surgical indication.

References

1. Middleton WD, Edelman G, Reinus WR, Melson GL and Murphy WA: Ultrasonography of the rotator cuff: Technique and normal anatomy. *J Ultrasound Med* (1984) **3**, 549-551.
2. Crass JR, Craig EV, Thompson RC and Feinberg SB: Ultrasonography of rotator cuff: Surgical correlation. *J Clin Ultrasound* (1984) **12**, 487-492.
3. Sakuragi K: Morphological and clinical study of shoulder joint diseases by ultrasonography. *J Jpn Orthop Assoc* (1989) **63**, 1330-1342 (in Japanese).
4. Middleton WD, Edelman G, Reinus WR, Melson GL, Totty WG and Murphy WA: Sonographic detection of rotator cuff tears. *Am J Roentgenol* (1985) **144**, 349-353.
5. Mack LA, Masten FA 3d, Kilcoyne RF, Davies PK and Sickler ME: US evaluation of the rotator cuff. *Radiology* (1985) **157**, 205-209.

6. Middleton WD, Reinus WR, Totty WG, Melson CL and Murphy WA: Ultrasonographic evaluation of the rotator cuff and biceps tendon. *J Bone Jt Surg Am Vol* (1986) **68**, 440-450.
7. Crass JR, Craig E and Feinberg SB: Sonography of postoperative rotator cuff. *Am J Roentgenol* (1986) **146**, 561-564.
8. Mack LA, Nyberg DA, Masten FR 3d, Kilcoyne RF and Harvey D: Sonography of the postoperative shoulder. *Am J Roentgenol* (1988) **150**, 1089-1093.
9. Post M, Silver R and Singh M: Rotator cuff tear: Diagnosis and treatment. *Clin Orthop Relat Res* (1983) **173**, 78-91.
10. McLaughlin HL: Lesions of the musculotendinous cuff of the shoulder. I. The exposure and treatment of tears with retraction. *J Bone Jt Surg Am Vol* (1944) **26**, 31-51.
11. Neer CS III: Anterior acromioplasty for the chronic impingement syndrome in the shoulder. *J Bone Jt Surg Am Vol* (1972) **54**, 41-50.
12. Rowe CR: Evaluation of the Shoulder. *The Shoulder*. Churchill Livingstone, New York (1988) pp632-633.
13. Hall FM, Rosenthal DI, Goldberg RP and Wyshak G: Morbidity from shoulder arthrography: Etiology, incidence, and prevention. *Am J Roentgenol* (1981) **136**, 59-62.
14. Read JW and Perko M: Shoulder ultrasound: Diagnostic accuracy for impingement syndrome, rotator cuff tear, and biceps tendon pathology. *J Shoulder Elbow Surg* (1998) **7**, 264-271.
15. Wohlwend JR, van Holsbeeck M, Craig J, Shriazi K, Habra G, Jacobsen G and Bouffard JA: The association between irregular greater tuberosities and rotator cuff tears: A sonographic study. *Am J Roentgenol* (1998) **171**, 229-233.

Received September 28, 1998; accepted January 5, 1999.