

Adequacy and Long-Term Prognosis of Endoscopic Carpal Tunnel Release

Takahiko HIROOKA, Hiroyuki HASHIZUME*, Masuo SENDA, Mitsuru NAGOSHI, Hajime INOUE and Hiroaki NAGASHIMA

Department of Orthopaedic Surgery, Okayama University Medical School, Okayama 700-8558, Japan

Forty-one hands of 37 patients with idiopathic carpal tunnel syndrome treated by endoscopic carpal tunnel release (ECTR) were followed up for more than one year after surgery. Surgical results were evaluated using Kelly's criteria, the Semmes-Weinstein test, the static and moving 2-point discrimination tests, tip-pinch strength, and motor and sensory nerve conduction studies. Clinical results, according to Kelly's criteria three months after surgery, were excellent or good in 36 hands, and fair or poor in five hands. No recovery was evident at six months and 12 months after surgery in fair and poor hands. Based on these findings, we conclude that a neurolysis of the median nerve and release of constriction of the thenar muscle branch should be performed using the conventional open technique for patients with poor results three months after ECTR if the patients are dissatisfied with ECTR results.

Key words: carpal tunnel syndrome, endoscopic carpal tunnel release, idiopathic

C arpal tunnel syndrome (CTS) is caused by several pathognomonic conditions including rheumatoid arthritis, long-term hemodialysis and fracture of the distal radius. The outcome of surgery for CTS caused by these etiologies depends upon the extent of the underlying condition. Most cases of CTS are caused by spontaneous compression neuropathy of the median nerve in the carpal tunnel (idiopathic CTS). Idiopathic CTS is little influenced by the above-mentioned diseases. Surgery has proven to be effective for correcting idiopathic CTS.

CTS has been treated by release of the flexor retinaculum (FR). Recently, endoscopic carpal tunnel release

(ECTR) for patients with CTS has been developed as a minimally invasive technique (1-4) in lieu of the conventional open carpal tunnel release (OCTR). Satisfactory and long-term follow-up results have been reported (5-7). However, there have been few comparative and quantitative reports (8) of clinical and electrophysiological examination results of those patients who underwent ECTR, differentiating between those patients who had satisfactory results and those who did not. This type of comparative study is necessary to better understand the indications of ECTR and to improve prognostic accuracy before surgery.

Since September 1993, our group has been performing ECTR using Okutsu's method (1) for patients with idiopathic CTS. In most cases, satisfactory results are obtained, but some patients do not show sufficient improvement. This raises the question of the necessity and timing of re-operation.

The purpose of this study is to evaluate the results of ECTR surgery and to clarify, in cases where it is necessary, when additional surgery should be performed.

Patients and Methods

ECTR was performed using Okutsu's method (1) on 41 hands of 37 patients (4 men, 33 women) with idiopathic CTS, consisting of 25 right hands and 16 left. Bilateral ECTR was performed on four of the female patients. Age at the time of surgery was between 40 and 78 (mean age, 58 years). The diagnosis of idiopathic CTS was made according to Schuind's criteria (9).

Three clinical grades were used: Grade 1-mild symptoms: numbness, paresthesia, no atrophy of the thenar muscle, complete opposition possible. Grade 2-moderate

* To whom correspondence should be addressed.

symptoms: some atrophy of the thenar muscle, complete opposition possible. Grade 3-severe symptoms: significant atrophy of the thenar muscle with incomplete opposition.

Twenty-four hands were Grade 1, 12 were Grade 2 and 5 were Grade 3.

All patients who complained of numbness in the proper sensory region of the median nerve and who were positive for both Tinel's sign at the wrist joint and Phalen's test were electrophysiologically examined for distal motor latency (DML) before surgery.

Grade 1 hands with DML of over 7.0 msec were treated by ECTR. Hands with DML of less than 7.0 msec were conservatively treated for three months, and, if the results were poor, ECTR was performed. All Grade 2 and 3 patients underwent ECTR.

The ECTR is performed under intra-carpal tunnel block anesthesia. A transverse skin incision (about 1 cm) is made 3 cm proximal to the distal transverse wrist crease between the palmaris longus and flexor carpi ulnaris tendons. A transparent outer tube of the Universal Subcutaneous Endoscope system (Biomet, Warsaw, IN, USA) is inserted into the carpal tunnel through the skin incision. A 30-degree oblique viewing endoscope is then inserted into the transparent tube. The entrance and exit of the FR, whose fibers run perpendicular to those of tendons, can be confirmed endoscopically. Then a Beaver 376083 hook knife (Becton Dickinson, Boston, MA, USA) is inserted into the carpal tunnel next to the ulnar side of the tube. The FR is then cut with this hook knife.

Numbness, thenar muscle atrophy, and opposition disturbance were classified into four levels (Table 1). They were examined preoperatively and at one, three, six and 12 months after ECTR. The SW test, static and moving 2-point discrimination (s- and m-2PD) tests, tip-pinch strength, DML, and sensory nerve conduction velocity (SCV) were also examined before and after ECTR. The clinical results of ECTR were examined one, three, six and 12 months after surgery according to Kelly's criteria (10).

The SW, s- and m-2PD tests were corrected to the same ranking and analyzed using the Wilcoxon signed-ranks test. Tip-pinch strength, DML, and SCV were analyzed using the two group *t*-tests. A *P* value of < 0.03 was considered significant.

The electromyographical study was initiated after the patients had rested in an air-conditioned room for approximately 15 min. To measure DML, silver disc electrodes

Table 1 Clinical evaluation system

Numbness	
None:	None
Slight:	Finger tip only, slight numbness
Moderate:	On the finger area, moderate numbness
Severe:	Finger to palm, severe numbness
Thenar muscle atrophy	
None:	None compared with normal side
Slight:	Slight atrophy but convex muscle belly
Moderate:	Flat muscle belly
Severe:	Concave muscle belly
Opposition disturbance	
None:	Straight and strong tip to tip pinch with little finger is possible
Slight:	Tip to tip pinch with little finger is possible but does not show straight line
Moderate:	Side to tip with little finger
Severe:	No contact with little finger

were attached by adhesive tape over the abductor pollicis brevis according to the belly-tendon method, and the stimulus was increased gradually to a supramaximal level. The median nerve was stimulated at the wrist and the stimulus point remained 7 cm from the silver disc electrodes along the nerve. SCV, recorded at the wrist, was measured by supramaximal stimulation with ring electrodes at the level of the proximal interphalangeal joints of the middle finger. The duration of the stimulating impulse was 0.1 msec. The hand temperature, using a surface thermometer over the midpalm, was found to be 33°C or higher in all patients.

Those evaluated as excellent or good, according to Kelly's criteria three months after surgery, were classified as Group A, and those evaluated as fair or poor, as Group B. In each group, we noted the age at the time of surgery and the period between onset of symptoms and surgery. We examined data obtained before surgery and one and three months after surgery as well.

The age at surgery, the period between onset of symptoms and surgery, DML and SCV were analyzed using the Student's *t*-test, while the results of the SW, s- and m-2PD tests were corrected to the same ranking and analyzed using Mann-Whitney's U test. A *P* value of < 0.03 was considered significant.

Results

The results of ECTR evaluated by Kelly's criteria are

shown in Fig. 1. Three months after surgery, the results were excellent in 22 hands, good in 14 and fair in five. Thirty-six hands were in Group A and five in Group B. In Group B, no improvement was observed six and 12 months after surgery. Numbness decreased generally three months after surgery, however, in the four hands that showed moderate or severe numbness three months

after surgery, it had not decreased even 12 months after surgery (Fig. 2a). The residual numbness lowered their clinical ranking according to Kelly's criteria. Severe muscular atrophy and opposition disturbance observed eventually improved several months after surgery (Figs. 2b and 2c). However, these symptoms did not affect the final evaluation by Kelly's criteria since some patients did not regard muscular atrophy and opposition disturbance as problems in daily life. The age at surgery, the period from onset to surgery and severity of symptoms in Group B were relatively higher than in Group A.

On the SW test, the yellow or black groups (≥ 3.84) were observed in more than 60 % of the hands before surgery, but decreased to less than 10 % three months after surgery (Fig. 3a).

On the m-2PD test, 56 % of the hands were classified as 7 mm or higher before surgery, and this figure decreased to less than 25 % at one month, and less than 10 % (three hands) at three months after surgery (Fig. 3b). The remaining three hands had not improved even at 12 months after surgery. Of the three hands, two were in Group A and did not show numbness at three months after surgery. Therefore, the m-2PD test was not related to numbness, nor to Kelly's criteria. As for the s-2PD test, the percentage of hands showing level 7 or higher

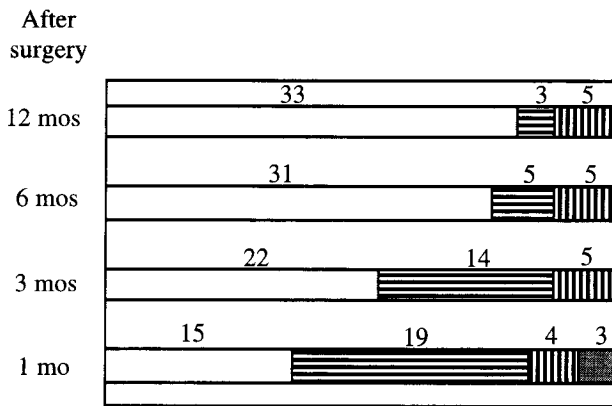


Fig. 1 Results of endoscopic carpal tunnel release evaluated by Kelly's criteria after surgery (41 hands). mo: Month.
 □ : Excellent; ▨ : Good; ▩ : Fair; ▪ : Poor.

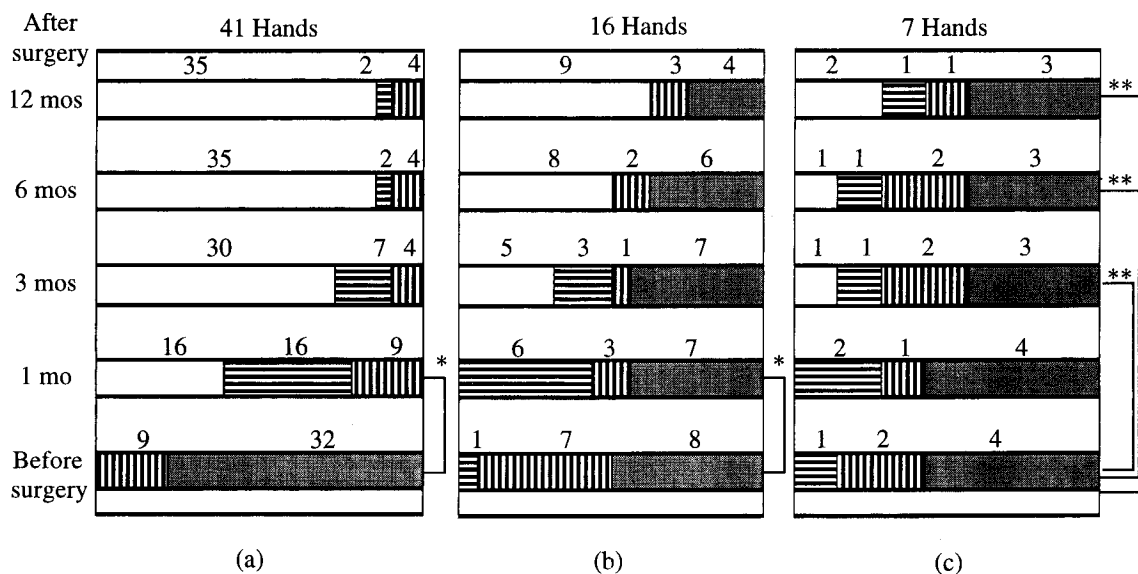


Fig. 2 Improvement in numbness (a), thenar muscular atrophy (b) and opposition disturbance (c) measured from before surgery to 12 months after surgery.
 □ : None; ▨ : Slight; ▩ : Moderate; ▪ : Severe. * $P < 0.01$. **N.S. (Wilcoxon signed-ranks test). mo: Month.

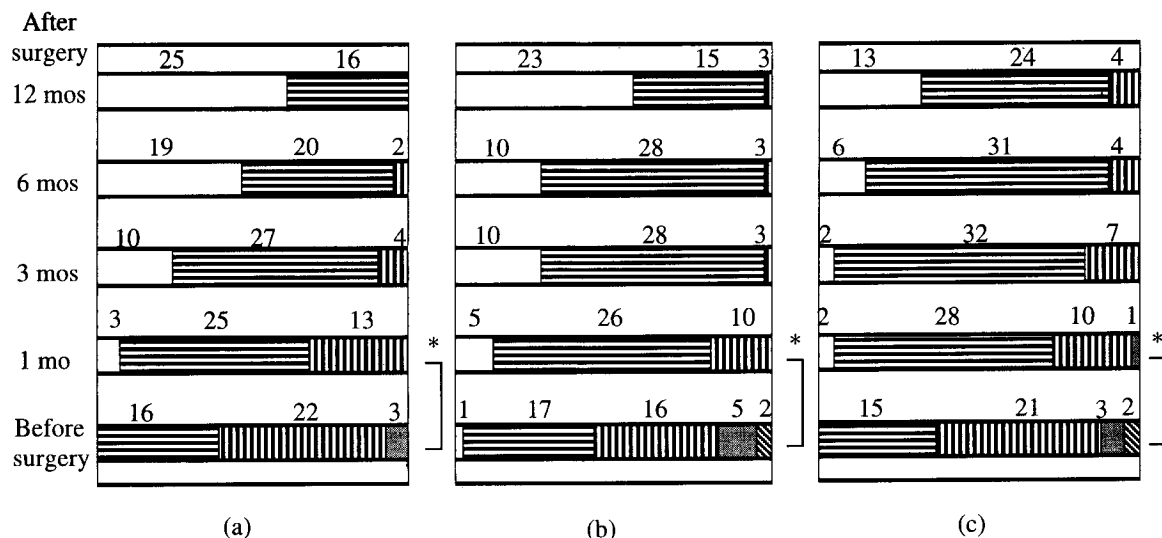


Fig. 3 Results of the Semmes-Weinstein test (a), m-2PD test (b) and s-2PD test (c) measured from before surgery to 12 months after surgery (41 hands).

□ : Green (1.65-2.83); ▨ : Blue (3.22-3.61); ▩ : Yellow (3.84-4.31); ▤ : Black (4.56-6.45); □ : 3; ▨ : 5; ▩ : 7; ▤ : 9; ▥ : 11-15 (mm). **P* < 0.01 (Wilcoxon signed-ranks test). mo: Month.

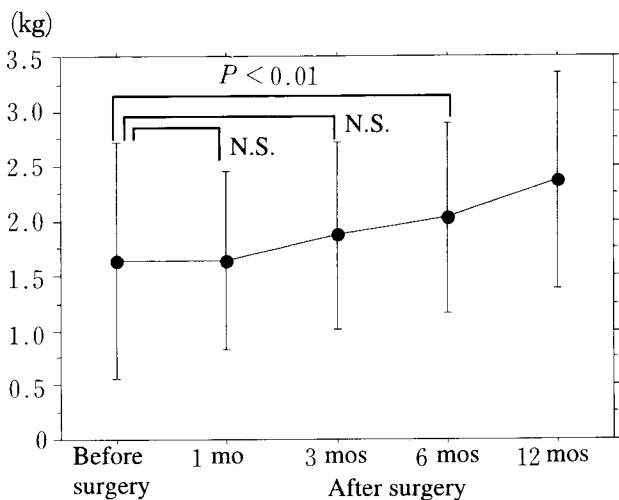


Fig. 4 Tip-pinch strength measured from before surgery to 12 months after surgery. (41 hands, mean ± SD, two group *t*-test). mo: Month. N.S.: Not significant.

was more than 60 % before surgery. That percentage had decreased to about 25 % one month after surgery and to less than 10 % (four hands) 12 months after surgery (Fig. 3c). Of these four hands, two were in Group A, and did not show numbness at three months after surgery. Like the m-2PD test, the s-2PD test was also not related to

numbness, nor to Kelly's criteria. Tip-pinch strength had not improved distinctly one month and three months after surgery, although it had significantly improved six months after surgery (Fig. 4). DML and SCV had improved significantly one month after surgery (Fig. 5).

Differences in the SW test, m and s-2PD tests, tip-pinch strength, DML and SCV findings between Groups A and B before surgery, and one and three months after surgery are shown in Table 2. There were significant differences in age at the time of surgery, in the m and s-2PD tests, and in DML between the two groups. The m and s-2PD tests and DML differed significantly one month after surgery. Three months after surgery, there were significant differences in the SW, s-2PD tests, DML and SCV; however, there was no significant difference in tip-pinch strength before surgery, or one and three months after surgery. There was no significant difference in the period between onset of symptoms and surgery between the two groups.

Discussion

ECTR, a minimally invasive technique (selective cutting of the FR) has developed since Okutsu's first report (1), and now has been performed by several variant

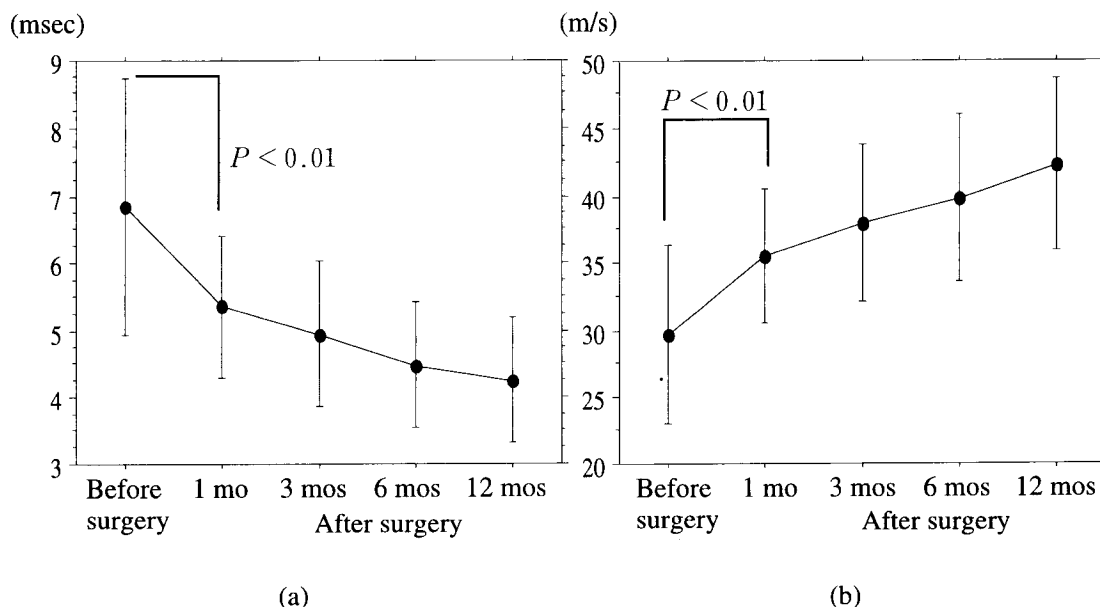


Fig. 5 Distal motor latency (a) and sensory nerve conduction velocity (SCV) (b) measured from before surgery to 12 months after surgery. (mean ± SD, two group *t*-test). SCV measurement could not be performed in four hands before surgery. mo: Month.

Table 2 Differences in Semmes-Weinstein (SW) test, static and moving 2-point discrimination (s- and m-2PD) tests, tip-pinch strength, distal motor latency (DML) and sensory nerve conduction velocity (SCV) findings between Groups A and B before surgery, and one and three months after surgery. Differences could not be statistically examined for SCV before and one month after surgery, because SCV of most cases was unobtainable.

	Before surgery	1 month after surgery	3 months after surgery
SW test	N.S.	N.S.	<i>P</i> < 0.01
m-2PD	<i>P</i> < 0.03	<i>P</i> < 0.03	N.S.
s-2PD	<i>P</i> < 0.01	<i>P</i> < 0.01	<i>P</i> < 0.03
Tip-pinch strength	N.S.	N.S.	N.S.
DML	<i>P</i> < 0.03	<i>P</i> < 0.01	<i>P</i> < 0.01
SCV	-	-	<i>P</i> < 0.01

N.S.: Not significant.

methods (2-4). However, some complications of this technique have also been reported (11).

Parathanassiou (12) first reported a thenar muscle branch running through a small opening in the FR. Poisel (13) classified anatomical variations of the thenar branch into three types: extraligamentous (46%), subligamentous (31%) and transligamentous (23%). ECTR is thought to be inappropriate in CTS patients suffering from certain types of transligamentous CTS, in which the thenar branch is compressed through the FR and in which

thenar muscle atrophy and opposition disturbances are observed. In these cases, OCTR combined with release of the thenar branch, should be performed. However, good results can be expected by ECTR in the extraligamentous and subligamentous types CTS.

There is still some controversy as to whether patients with severe muscular atrophy should undergo release or reconstructive surgery. Of course, such patients can always undergo reconstructive surgery after release surgery has been tried with unsatisfactory results. Patients with opposition disturbance need not undergo surgery provided they do not suffer any inconvenience in their daily lives. Another factor arguing against the universal application of reconstructive surgery is that it poses the risk of contracture of the finger joints, especially in older patients. With these factors in mind, it appears that a release surgery is a suitable first-surgery option even when a patient is suffering from severe muscular atrophy.

We believe that ECTR should be performed initially because the pressure to the thenar branch in the carpal tunnel is likely to be the cause of the muscular atrophy, even in severe cases. Thus, ECTR is particularly appropriate for patients with severe muscular atrophy whose main complaints are not impairment in daily life but pain and numbness. Indeed, some of the patients we treated were satisfied with the results of surgery even though

their muscular atrophy did not improve. Thus, it can be concluded that ECTR yields satisfactory results in patients with muscular atrophy and opposition disturbance when their chief complaints are pain and numbness. However, when the main complaints are muscular atrophy and opposition disturbance, and the symptoms could be induced by transligamentous compression, ECTR would be inappropriate.

Several parameters have been proposed for preoperative evaluation of treatment success, including the SW, m and s-2PD tests, tip-pinch strength and DML. In this survey, however, there were significant differences between the two groups before surgery on the m and s-2PD tests and DML. Szabo *et al.* (14) reported that the 2-PD test is more reliable for evaluation of nerve injury repair than for nerve compression. The reproducibility of the m and s-2PD tests was judged to be poor in this study. A DML of more than 8 msec was noted before surgery in five patients in Group A, which improved after ECTR in some patients. A prolonged delay in DML does not indicate a poor prognosis. Based on a statistical analysis of the two groups, it is difficult to determine the adequacy of ECTR for patients with idiopathic CTS.

Graham (15) reported that neurolysis should be conducted at the time of release surgery on the carpal tunnel for patients with thenar muscle atrophy, loss of 2PD, loss of light-touch sensibility and constantly decreased sensation. In patients with poor results, it is necessary to perform a neurolysis because of severe adhesion of the surrounding tissues and advanced fibrogenesis, and to confirm and release the constriction of the thenar branch in the FR.

Based on our clinical findings, patients in whom ECTR yielded poor results manifested two or more of the following characteristics: a) advanced age, b) DML of more than 6 msec three months after ECTR, c) SCV of less than 32m/sec three months after ECTR, d) more than 4.08 on the SW test three months after ECTR. Therefore, we believe that examination three months after ECTR is important. In patients with two or more of the above characteristics, re-operation should be considered.

When OCTR is performed as a first-surgery procedure in all patients to avoid the possibility of a second surgery, it becomes oversurgery for a large percentage of patients. Therefore, ECTR should be performed firstly on all patients. For patients showing poor results three

months after ECTR, OCTR should be performed (neurolysis of the median nerve and removal of constriction of the thenar branch). OCTR can be the first choice for elder patients who have severe muscular atrophy. In the near future, normal electromyographic analysis of the second lumbricales muscle will allow for accurate diagnosis and surgical prognosis. This type of analysis will further aid in choosing the appropriate surgical procedure for CTS relief.

References

1. Okutsu I, Ninomiya S, Natsuyama M, Takatori Y, Inanami H, Kuroshima N and Hiraki S: Subcutaneous operation and examination under universal endoscope. *J Jpn Orthop Assoc* (1987) **61**, 491-498 (in Japanese).
2. Chow JC: Endoscopic release of the carpal ligament: A new technique for tunnel syndrome. *Arthroscopy* (1989) **5**, 19-24.
3. Agee JM, MaCarroll HR Jr, Tortosa RD, Berry DA, Szabo RM and Peimer CA: Endoscopic release of the carpal tunnel: A randomized prospective multicenter study. *J Hand Surg [Am]* (1992) **17**, 987-995.
4. Menon J: Endoscopic carpal tunnel release: Preliminary report. *Arthroscopy* (1994) **10**, 31-38.
5. Okutsu I, Ninomiya S, Takatori Y, Hamanaka I, Genba K, Ugawa Y, Schonholtz GJ and Okumura Y: Results of endoscopic management of carpal tunnel syndrome. *Orthop Rev* (1993) **22**, 81-87.
6. Sellers DSI: Endoscopic carpal tunnel release. *Clin Plast Surg* (1995) **22**, 775-800.
7. Atroshi I, Johnsson R and Ornstein E: Endoscopic carpal tunnel release: prospective assessment of 255 consecutive cases. *J Hand Surg [Br]* (1997) **22**, 42-71.
8. Dumontier C, Sokolow C, Leclercq C and Chauvin P: Early results of conventional versus two-portal endoscopic carpal tunnel release. A prospective study. *J Hand Surg [Br]* (1995) **20**, 658-662.
9. Schuind F, Ventura M and Pasteel JL: Idiopathic carpal tunnel syndrome: Histologic study of flexor tendon synovium. *J Hand Surg [Am]* (1990) **15**, 497-503.
10. Kelly CP, Puliseti D and Jamieson AM: Early experience with endoscopic carpal tunnel release. *J Hand Surg [Br]* (1994) **19**, 18-21.
11. Shinya K, Lanzewtta M and Conolly WB: Risk and complication in endoscopic carpal tunnel release. *J Hand Surg [Br]* (1995) **20**, 222-227.
12. Parathanassiou BT: A variant of the motor branch of the median nerve in the hand. *J Bone Jt Surg [Br]* (1968) **50**, 156-157.
13. Poisel S: Ursprung und Verlauf des Ramus muscularis des Nervus digitalis palmaris communis I (N. medianus). *Chir. Plaxis* (1974) **18**, 471-474.
14. Szabo RM, Gelberman RH and Dimick MP: Sensibility testing in patients with carpal tunnel syndrome. *J Bone Jt Surg Am Vol* (1984) **66**, 60-64.
15. Graham RA: Carpal tunnel syndrome. A statistical analysis of 214 cases. *Orthopedics* (1983) **6**, 1283-1286.

Received June 24, 1998; accepted October 20, 1998.